

**PATIENT**

Phoenix James

**SPECIES**

Canine

**BREED**

Boxer Mix

**SEX**

Spayed Female

**AGE**

12 Years

**WEIGHT**

73.7 lbs

**INTERPRETED BY**

Eric Lindquist, DMV,  
DABVP(CFM), Cert.  
IVUSS

**IMAGING PERFORMED BY**

Kathleen Byrnes

**HOSPITAL NAME**

All Hearts Animal  
Hospital

**REFERRING VET**

Dr. Moe

**INVOICE**

15866

**DATE**

05/06/26

**PRESENTING CLINICAL SIGNS**

Patient presents for moaning (primarily in the nighttime hours) and panting. Patient seems to moan and groan while sleeping. This has been going on for approximately a year. Patient also has a cough that sounds deep and has become more consistent. Patient also drools often. Mass in cranial thorax. Rads attached.

**ULTRASONOGRAPHIC EXAMINATION OF THE HEART**

CANINE CARDIAC PARAMETERS	MR VMAX (m/s)	TR VMAX (m/s)	LA/AO (M-Mode)	LA/AO (Heart Base; Swe)	FS (%)	EF (%)	EPSS (cm)
NORMAL PARAMETER	4.5-5.5	<2.7	1.3	Up to 1.6	28-40	40-100	<0.6
PATIENT	--	--	1.1	1.4	46	78	0.1
CANINE CARDIAC PARAMETERS	HR (BPM)	AV VMAX (m/s)	PV MAX (m/s)	BODY WEIGHT (lbs)	LAD LA MAX 4 Chamber	LVIDd Avg; 2D and m-mode short axis (cm)	LVIDs Avg; 2D and m-mode short axis (cm)
NORMAL PARAMETER	50-100	0.7-1.7	0.7-1.6				
PATIENT	110	--	1.4	73.7	3.1	3.8	--

**Cardiac Presentation**

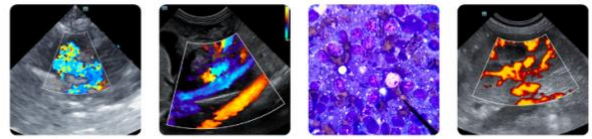
The heart in this patient presented with normal volumes and contractility, however, was deviated owing to extensive mass effect in the adjacent extracardiac field. Mass origin is unclear, and appears cystic and irregular, potentially thymic-related. However, the mass effect did deviate the heart laterally. The mass measured up to 10.0+ cm.

**ULTRASONOGRAPHIC FINDINGS**

- Extensive thoracic mass- sarcoma, thymoma are primary potentials with granulomatous disease thought less likely.

**INTERPRETATION OF THE FINDINGS & FURTHER RECOMMENDATIONS**

Ultrasound guided FNA of the mass is recommended. However, surgical biopsy may be necessary for a definitive diagnosis. CT evaluation for potential surgical planning would be indicated. Full abdominal sonogram is recommended to assess for comorbidities.



**PATIENT**

Phoenix James

**SPECIES**

Canine

**BREED**

Boxer Mix

**SEX**

Spayed Female

**AGE**

12 Years

**WEIGHT**

73.7 lbs

**INTERPRETED BY**

Eric Lindquist, DMV,  
 DABVP(CFM), Cert.  
 IUUSS

**IMAGING PERFORMED BY**

Kathleen Byrnes

**HOSPITAL NAME**

All Hearts Animal  
 Hospital

**REFERRING VET**

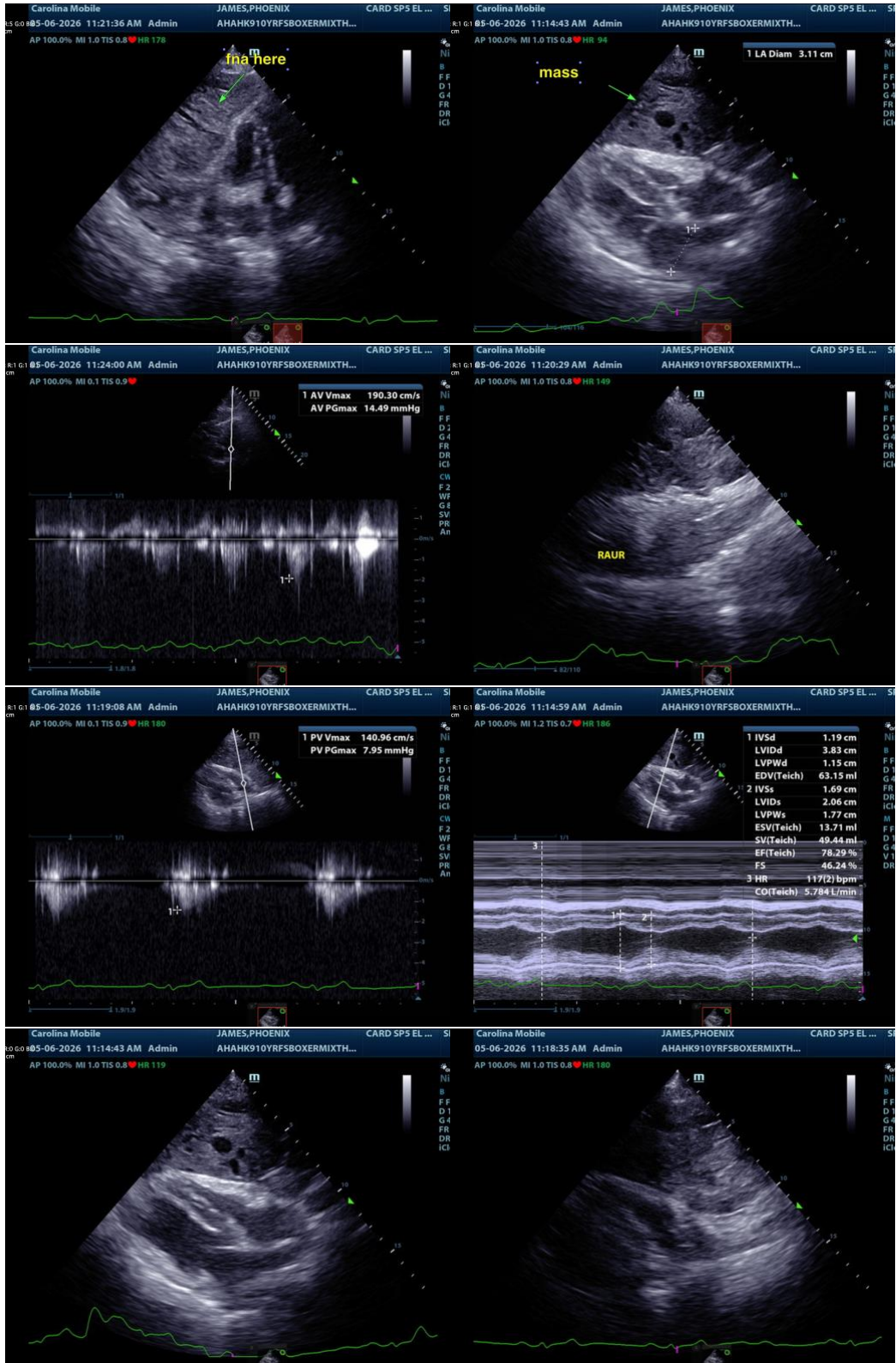
Dr. Moe

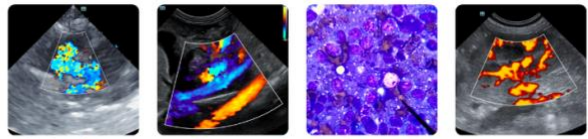
**INVOICE**

15866

**DATE**

05/06/26





**PATIENT**

Phoenix James

The information and recommendations provided are based on the images presented by the referring veterinarian/sonographer. No evaluation can be communicated regarding pathology that was not visible in the image/video clips provided.

**SPECIES**

Canine

Thank you for this referral. If the clinical or image interpretation does not parallel your findings or if I can be of any further assistance, please contact me.

**BREED**

Boxer Mix

**Eric Lindquist, DMV, DABVP(CFM), Cert. IVUSS,**

CEO, Owner, Founder -- SonoPath.com

[info@SonoPath.com](mailto:info@SonoPath.com)

**SEX**

Spayed Female

**AGE**

12 Years

**WEIGHT**

73.7 lbs

**INTERPRETED BY**

Eric Lindquist, DMV,  
DABVP(CFM), Cert.  
IVUSS

**IMAGING PERFORMED BY**

Kathleen Byrnes

**HOSPITAL NAME**

All Hearts Animal  
Hospital

**REFERRING VET**

Dr. Moe

**INVOICE**

15866

**DATE**

05/06/26