



PATIENT

Henry Leigh

SPECIES

Canine

BREED

Doodle

SEX

Neutered Male

AGE

11 Years 6 Months

WEIGHT

72.6

INTERPRETED BY

Eric Lindquist, DMV,
DABVP(CFM), Cert.
IVUSS

IMAGING PERFORMED BY

Dr. Michele
Pffannenstiel

HOSPITAL NAME

Mill Brook Animal
Clinic- VBF

REFERRING VET

Dr. Michele
Pffannenstiel

INVOICE

15873

DATE

05/06/26

PRESENTING CLINICAL SIGNS

Echo to track 2/3 murmur; pt is significant for phaeo in 2024 and has quarterly CXR and AUS to track. Was completely excised and NSF otherwise except wretched atopy.

Abnormal PE/Chem/CBC/UA Results: Sinus arrhythmia and otherwise nsf on Cardiopet read.

ULTRASONOGRAPHIC EXAMINATION OF THE HEART

CANINE CARDIAC PARAMETERS	MR VMAX (m/s)	TR VMAX (m/s)	LA/AO (M-Mode)	LA/AO (Heart Base; Swe)	FS (%)	EF (%)	EPSS (cm)
NORMAL PARAMETER	4.5-5.5	<2.7	1.3	Up to 1.6	28-40	40-100	<0.6
PATIENT	--	--	1.0	--	--	--	0.1
CANINE CARDIAC PARAMETERS	HR (BPM)	AV VMAX (m/s)	PV MAX (m/s)	BODY WEIGHT	LAD LA MAX 4 Chamber	LVIDd Avg; 2D and m-mode short axis (cm)	LVIDs Avg; 2D and m-mode short axis (cm)
NORMAL PARAMETER	50-100	0.7-1.7	0.7-1.6				
PATIENT	80	--	--	72.6	3.9	3.8	--

Cardiac Presentation

The echocardiogram in this patient demonstrated normal **left atrial** size based on 3 different LA measurement methods. Chamber volumes and echogenicity were normal. The cranial and caudal **mitral** valve leaflets presented vegetative thickening consistent with endocardiosis. Doppler indicated trivial insufficiency yet not clinically significant. The **left ventricle** presented normal thicknesses with linear contour and was not dilated nor restricted. The **myocardium** presented normal echogenicity without subjective evidence of significant fibrotic or ischemic disease. **Contractility** of the ventricular walls was adequate and in normal range for this patient evidenced by the fractional shortening measurement and subjective evaluation of the different regions of the myocardium. The **left ventricular outflow** tract demonstrated normal laminar flow and subjective structural integrity. The **right atrium** and auricle revealed normal size, structure and content. No evidence of masses was noted or chamber overload. **Tricuspid** valvular assessment demonstrated adequate linear morphology. The **right ventricle** was of normal size (1/3 diameter of LV), chordae structure, myocardial echogenicity and thickness. **Pulmonic** tract assessment revealed normal valve structure, laminar flow, and diameter (approx.1:1 pa/ao ratio). No visible **pericardial** or free pleura fluid was noted. No echographically detectable evidence of infiltrative disease was visible. The cranial **mediastinum and pericardial regions** were free of masses in the visible window.

ULTRASONOGRAPHIC FINDINGS

- Trivial mitral insufficiency. No evidence of volume overload.



PATIENT

Henry Leigh

SPECIES

Canine

BREED

Doodle

SEX

Neutered Male

AGE

11 Years 6 Months

WEIGHT

72.6

INTERPRETED BY

Eric Lindquist, DMV,
DABVP(CFM), Cert.
IVUSS

IMAGING PERFORMED BY

Dr. Michele
Pffannenstiel

HOSPITAL NAME

Mill Brook Animal
Clinic- VBF

REFERRING VET

Dr. Michele
Pffannenstiel

INVOICE

15873

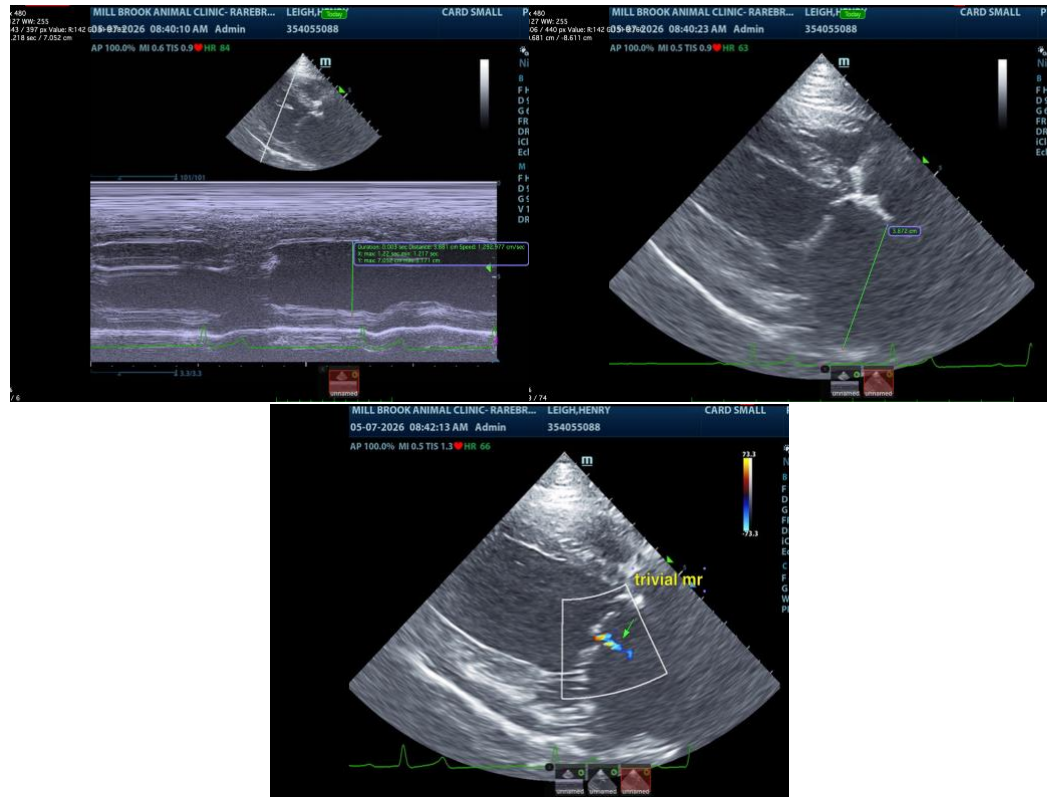
DATE

05/06/26

- Stable heart otherwise.

INTERPRETATION OF THE FINDINGS & FURTHER RECOMMENDATIONS

No contraindications to anesthetic procedures if necessary.



The information and recommendations provided are based on the images presented by the referring veterinarian/sonographer. No evaluation can be communicated regarding pathology that was not visible in the image/video clips provided.

Thank you for this referral. If the clinical or image interpretation does not parallel your findings or if I can be of any further assistance, please contact me.

Eric Lindquist, DMV, DABVP(CFM), Cert. IVUSS,

CEO, Owner, Founder -- SonoPath.com

info@SonoPath.com