



PATIENT

Buttons Weigle

SPECIES

Canine

BREED

Shih Tzu

SEX

Neutered male

AGE

7 years

WEIGHT

20.5 lbs

INTERPRETED BY

Eric Lindquist, DMV
DABVP, Cert. IVUSS

PRESENTING CLINICAL SIGNS

History: Buttons presented today for dental cleaning. preop auscultation revealed no murmur but lungs sounded wet. radiographs were taken and showed cardiomegaly (VHS 10.9) and pulmonary hilar edema.

Abnormal PE/Chem/CBC/UA Results: glob 3.7, rest NSF. platelet count 558, neut 52%, lymph 36% rest WNL

ULTRASONOGRAPHIC EXAMINATION OF THE HEART

The echocardiogram in this patient demonstrated normal **left atrial** size based on 3 separate methods of LA evaluation. The cranial and caudal **mitral** valve leaflets presented normal linear structure, extension in systole, and union in diastole with normal kinesis. The **left ventricle** presented thicknesses with linear contour and was not dilated nor restricted. The **myocardium** presented normal echogenicity without subjective evidence of significant fibrotic or ischemic disease. **Contractility** of the ventricular walls was adequate and in normal range for this patient evidenced by the fractional shortening measurement and subjective evaluation of the different regions of the myocardium. The **left ventricular outflow** tract demonstrated normal laminar flow and subjective structural integrity. The **right atrium** and auricle revealed normal size, structure and content. No evidence of masses was noted. Mild **tricuspid** insufficiency was noted, yet not clinically significant. This was demonstrated on color flow Doppler. The **right ventricle** was of normal size (1/3 diameter of LV), chordae structure, myocardial echogenicity and thickness. **Pulmonary outflow** tract assessment revealed normal valve structure, laminar flow, and diameter (approx. 1:1 pa/ao ratio). No visible **pericardial** or free pleura fluid was noted. The cranial **mediastinum and pericardial and extra-cardiac regions** were free of masses in the visible window.

E Wave Velocity 0.9

IMAGING PERFORMED BY

Brandon

HOSPITAL NAME

Dillsburg VC

REFERRING VET

Dr. Amber

INVOICE

75262

DATE

5/6/26

CANINE CARDIAC PARAMETERS	MR VMAX (m/s)	TR VMAX (m/s)	LA/AO	LA/AO (Heart Base)	FS (%)	EF (%)	EPSS (cm)
NORMAL PARAMETER	4.5-5.5	<2.7	1.3	<1.6	28-40	40-100	<0.6
PATIENT	-	-	1.4	1.1	45	90	0.1
CANINE CARDIAC PARAMETERS	HR (BPM)	AV VMAX (m/s)	PV MAX (m/s)	BODY WEIGHT	LA 2D short axis Base view (cm)	LVIDd Avg; 2D and m-mode short axis (cm)	LVIDs Avg; 2D and m-mode short axis (cm)
NORMAL PARAMETER	50-100	0.7-1.7	0.7-1.6	BELOW	BELOW	BELOW	BELOW
PATIENT	-	1.2	-	20.5 lbs	1.4	2.02	



PATIENT

Buttons Weigle

SPECIES

Canine

BREED

Shih Tzu

SEX

Neutered male

AGE

7 years

WEIGHT

20.5 lbs

INTERPRETED BY

Eric Lindquist, DMV
DABVP, Cert. IVUSS

IMAGING PERFORMED BY

Brandon

HOSPITAL NAME

Dillsburg VC

REFERRING VET

Dr. Amber

INVOICE

75262

DATE

5/6/26

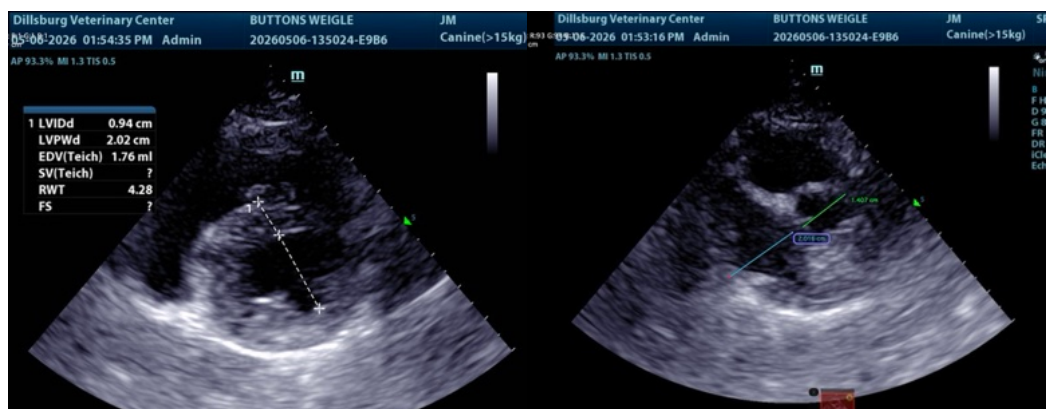
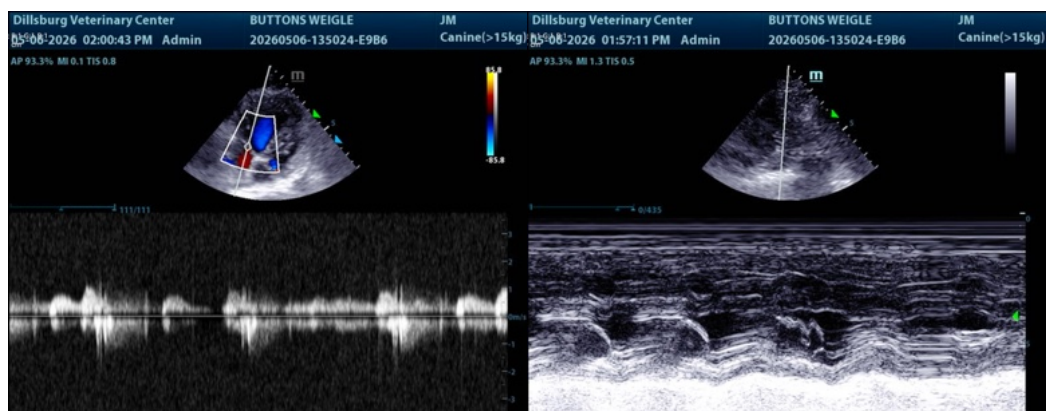
ULTRASONOGRAPHIC FINDINGS

Stage B1 valvular disease.

INTERPRETATION OF THE FINDINGS & FURTHER RECOMMENDATIONS

There is no contradiction to anesthetic procedure.

The heart is stable without clinical disease. No overt contraindication for anesthesia of brief to moderate duration. I suggest Torbutrol premed, Propofol induction, Isoflor maintenance or similar protocol if anesthesia is desired. Blood pressure recommended if not already performed and target white coat negative systolic pressure of < 160 mmHg. If higher than this ACE-inhibitor is suggested to reach this level. Recheck echocardiogram is recommended in 6 months, earlier if murmur grade increases or clinical signs initiate.





PATIENT

Buttons Weigle

SPECIES

Canine

BREED

Shih Tzu

SEX

Neutered male

AGE

7 years

WEIGHT

20.5 lbs

INTERPRETED BY

Eric Lindquist, DMV
DABVP, Cert. IVUSS

IMAGING PERFORMED BY

Brandon

HOSPITAL NAME

Dillsburg VC

REFERRING VET

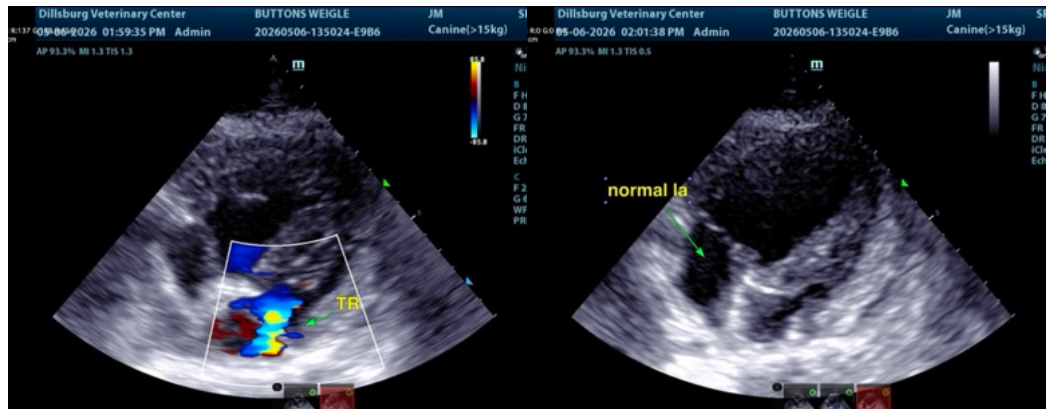
Dr. Amber

INVOICE

75262

DATE

5/6/26



The information and recommendations provided are based on the images presented by the referring veterinarian/sonographer. No evaluation can be communicated regarding pathology that was not visible in the image/video clips provided.

Thank you for this referral. If the clinical or image interpretation does not parallel your findings or if I can be of any further assistance please contact me.

Eric Lindquist, DMV, DABVP (CFM), Cert. IVUSS, CEO of SonoPath.com

info@SonoPath.com