

PATIENT

Elvis Goldberg

PRESENTING CLINICAL SIGNS

Dyspnea, cardiomegaly.

SPECIES

Feline

ULTRASONOGRAPHIC EXAMINATION OF THE HEART

BREED

Rex

FELINE CARDIAC PARAMETERS	BODY WEIGHT (kg)	HR (BPM)	IVSd (cm)	LVIDd (cm)	LVWd (cm)	FS (%)	EF (%)
NORMAL PARAMETER	-----	150-240	0.3-0.6	1.0-2.1	0.25-0.6	35-67	80-100
PATIENT		NM	0.25	1.17	0.4	20-25	35
FELINE CARDIAC PARAMETERS	LA/AO (Boon)	LA/AO HEART BASE (Sisson)	LA 2D 4-chamber long axis AS to FW (Sisson) (cm)	LVOT VEL. (m/s)	RVOT VEL. (m/s)	IVRT (m/)	
NORMAL PARAMETER	<1.5	0.88-1.79	0.7-1.7	<1.6	<1.3	40-60	
PATIENT	2.0	2.2	1.8	1.1	0.9	NM	

Adapted from June Boon, Veterinary Echocardiography, 1998
Sisson D et al. JVIM 1991; 5: 232, Jacobs et al. Am J Vet Res 1985; 46:1705

AGE

17 Years

WEIGHT

7 Pounds

Cardiac Presentation

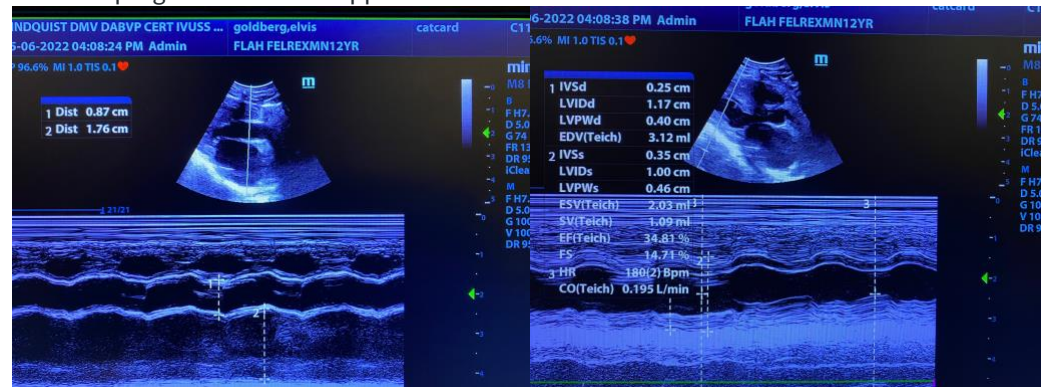The cardiac presentation revealed volume overload of the left atrium and minor volume overload of the right atrium. Mitral and tricuspid insufficiency noted. Hypocontractility of the left ventricular septal free wall noted with minor myocardial remodeling, yet measurements are normal. Contractility was subnormal, consistent with myocardial insufficiency. Slight pericardial effusion noted. No pleural effusion. Hepatic veins were not dilated.

ULTRASONOGRAPHIC FINDINGS

- Left-sided congestive heart failure, unclassified cardiomyopathy

INTERPRETATION OF THE FINDINGS & FURTHER RECOMMENDATIONS

Recommend quadrotherapy in this patient with ACE inhibitor 0.5 mg/kg SID, Lasix continued at 6.25 mg/kg BID, off-label Pimobendan at 0.3 mg/kg BID, and Plavix therapy. Recheck echo in 10-14 days. Guarded prognosis. Taurine supplementation and nutraceuticals could be considered as well.



INTERPRETED BY

Eric Lindquist, DMV
DABVP, Cert. IVUSS

IMAGING PERFORMED BY

Eric Lindquist, DMV
DABVP, Cert. IVUSS

HOSPITAL NAME

Franklin Lakes AH

REFERRING VET

Dr. Pomerantz

INVOICE

37453

DATE

5/6/22



PATIENT

Elvis Goldberg

SPECIES

Feline

BREED

Rex

SEX

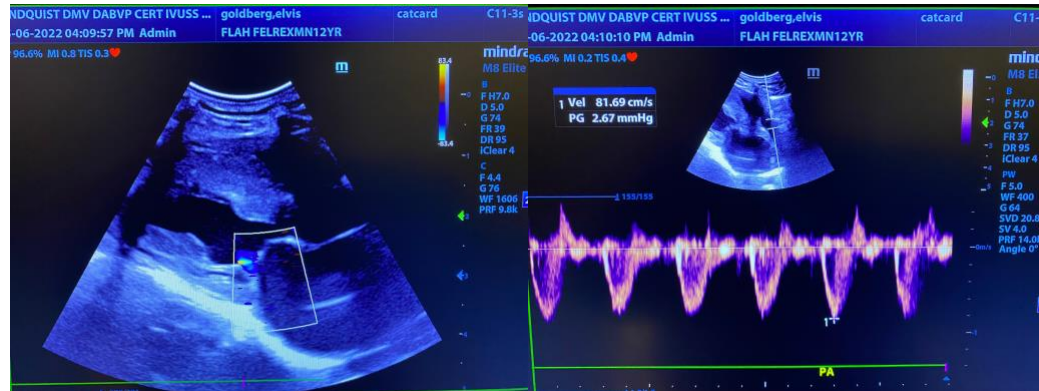
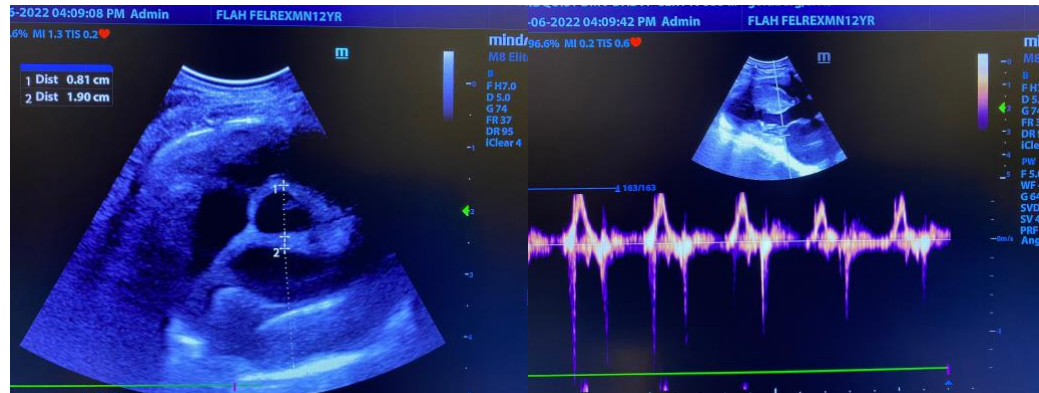
Neutered Male

AGE

17 Years

WEIGHT

7 Pounds



The information and recommendations provided are based on the images presented by the referring veterinarian/sonographer. No evaluation can be communicated regarding pathology that was not visible in the image/video clips provided.

Thank you for this referral. If the clinical or image interpretation does not parallel your findings or if I can be of any further assistance please contact me.

Eric Lindquist, DMV, DABVP, Cert. IVUSS, CEO of SonoPath.com

info@SonoPath.com

INTERPRETED BY

Eric Lindquist, DMV
DABVP, Cert. IVUSS

IMAGING PERFORMED BY

Eric Lindquist, DMV
DABVP, Cert. IVUSS

HOSPITAL NAME

Franklin Lakes AH

REFERRING VET

Dr. Pomerantz

INVOICE

37453

DATE

5/6/22