



**PATIENT**

Capone Sengle

**PRESENTING CLINICAL SIGNS**

Recheck. 1<sup>st</sup> AUS, possible neoplasia.

**SPECIES**

Canine

**ULTRASONOGRAPHIC EXAMINATION OF THE ABDOMEN**

**Urinary System**

The **urinary bladder**, trigone, and pelvic urethra presented normal thicknesses and normal tone. The ureters were not visible which is normal. No uroliths or sediment were visualized and anechoic urine was present. No evidence of inflammatory or neoplastic changes were noted. Ureteral papillae were normal.

**BREED**

Pit Bull

The **prostate** was uniformly enlarged (4.9 cm) with lobar swelling appeared to impinge upon the urethra and mildly deviate the descending colon. The prostatic tissue was hyperechoic containing focal areas of decreased echogenicity. These changes are suggestive of either chronic inflammatory episodes, benign cystic pathology or both. Underlying neoplasia cannot be completely ruled-out but is lower on the differential list. This presentation is most consistent with benign prostatic hyperplasia with possible active prostatitis. Neutering or off-label Finasteride (Propecia) (0.1-0.5 mg/kg Sid) treatment is indicated +/- FNA or prostatic wash cytology and culture.

**SEX**

Male

**AGE**

7 Years

The **kidneys** revealed normal size and structure, corticomedullary definition and ratio for this age. The cortices presented largely uniform texture with normal echogenic relationship to liver and spleen. Medullary structure differed distinctly from the cortex and no evidence of pelvic dilation was present. The capsules were acceptably uniform without significant irregularities. The left kidney measured 6.88 cm. The right kidney measured 6.88 cm.

**WEIGHT**

76.5 Pounds

**Adrenal Glands**

Both **adrenal glands** were visualized and recognized as having normal shape, size, position and echogenicity for this breed. The phrenic vasculature, glandular echogenicity and detail were unremarkable. Capsule, cortex, and medullary definition were normal for this age patient. The left adrenal gland measured 3.17 cm x 0.70 cm.

**INTERPRETED BY**

Eric Lindquist, DMV

DABVP, Cert. IVUSS

**Spleen**

The **spleen** presented a smooth homogeneous parenchyma hyperechoic to liver and renal cortical parenchyma. The capsule was smooth without noticeable expansion or deviation from within the spleen or adjacent pathology. The splenic vasculature demonstrated normal volume without signs of congestion or thrombosis. No sonographic evidence of acute or chronic inflammatory, neoplastic, or infarctual changes were noted.

**IMAGING PERFORMED BY**

Eric Lindquist, DMV

DABVP, Cert. IVUSS

**Liver**

The **liver** images submitted revealed subjectively normal liver size, contour, and structure. Parenchymal echogenicity was naturally coarse and hypoechoic to the spleen. Vascular and biliary tracts were of normal volume with no evidence of congestion. The gallbladder presented acceptably thin walls with primarily anechoic content. The cystic and common bile ducts were normal. No pathological hepatic lymphadenopathy was evident. No overt structural evidence of inflammatory, infiltrative or regenerative pathology was evident.

**HOSPITAL NAME**

Rockaway AH

**REFERRING VET**

Dr. Maniar

**INVOICE**

37471

**DATE**

5/6/22

**Gastrointestinal**

Examination of the **gastrointestinal tract** revealed upper gastrointestinal stasis continuing into the distal small intestine, where areas of adhesions and tethering of the small intestine were noted, followed by empty small intestine. No overt foreign body noted, yet could not be ruled out. Regional



**PATIENT**

Capone Sengle

free fluid and enhanced mesentery noted, consistent with localized peritonitis, which is a progression from the prior sonogram.

**Pancreas**

**SPECIES**

Canine

The base and limbs of the **pancreas** were observed to be largely isoechoic to surrounding omental fat. Pancreatic duct and capsular contour were acceptably normal and parenchyma respected normal curvilinear patterns. No overt evidence of active inflammatory or neoplastic disease was noted.

**BREED**

Pit Bull

**ULTRASONOGRAPHIC FINDINGS**

- Small intestinal obstructive pattern with regional peritonitis

**INTERPRETATION OF THE FINDINGS & FURTHER RECOMMENDATIONS**

**SEX**

Male

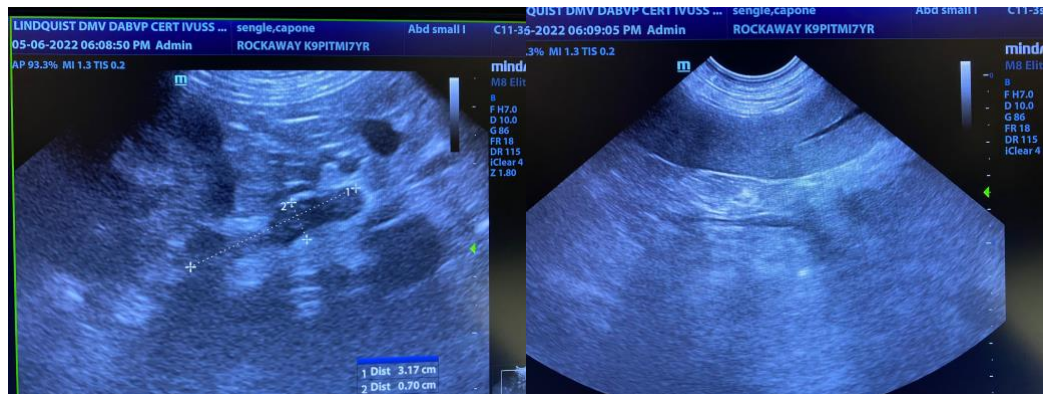
Exploratory surgery is essential. Possible penetrating foreign body, necrotic bowel, torsion or adhesions all possible. GI biopsies are essential.

**AGE**

7 Years

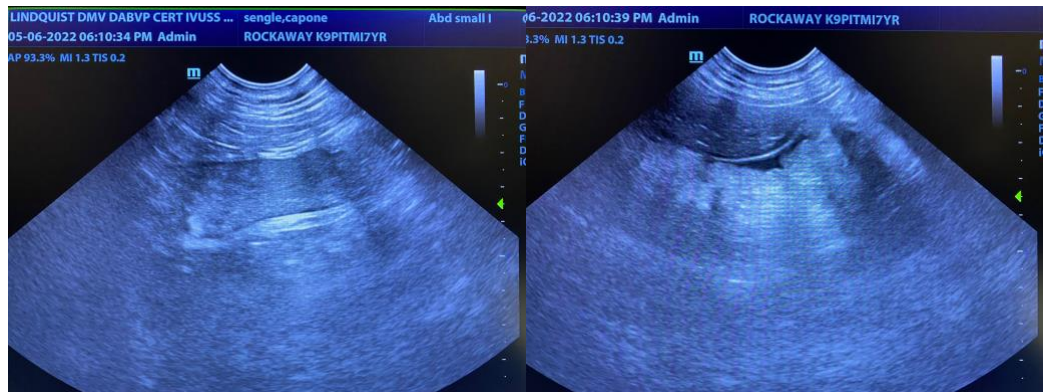
**WEIGHT**

76.5 Pounds



**INTERPRETED BY**

Eric Lindquist, DMV  
DABVP, Cert. IVUSS



**IMAGING PERFORMED BY**

Eric Lindquist, DMV  
DABVP, Cert. IVUSS

**HOSPITAL NAME**

Rockaway AH

**REFERRING VET**

Dr. Maniar

**INVOICE**

37471

**DATE**

5/6/22



**PATIENT**

Capone Sengle

**SPECIES**

Canine

**BREED**

Pit Bull

**SEX**

Male

**AGE**

7 Years

**WEIGHT**

76.5 Pounds

**INTERPRETED BY**

Eric Lindquist, DMV

DABVP, Cert. IVUSS

**IMAGING PERFORMED BY**

Eric Lindquist, DMV

DABVP, Cert. IVUSS

**HOSPITAL NAME**

Rockaway AH

**REFERRING VET**

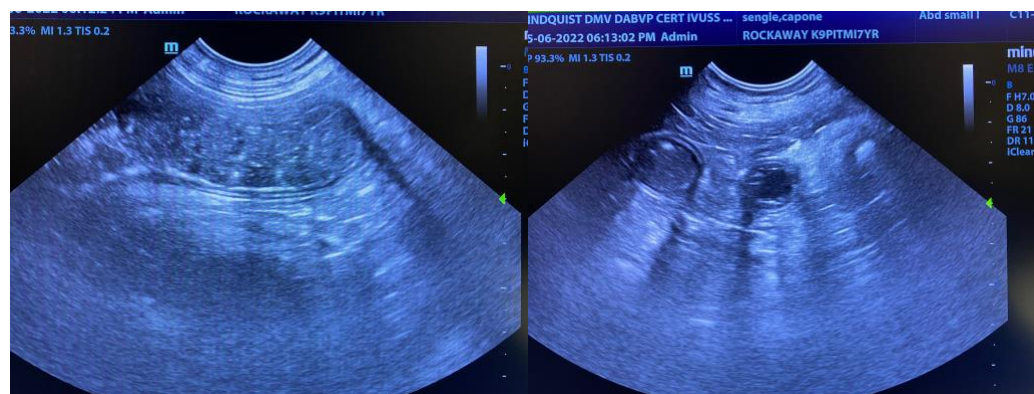
Dr. Maniar

**INVOICE**

37471

**DATE**

5/6/22



The information and recommendations provided are based on the images presented by the referring veterinarian/sonographer. No evaluation can be communicated regarding pathology that was not visible in the image/video clips provided.

Thank you for this referral. If the clinical or image interpretation does not parallel your findings or if I can be of any further assistance please contact me.

Eric Lindquist, DMV, DABVP, Cert. IVUSS, CEO of SonoPath.com

[info@SonoPath.com](mailto:info@SonoPath.com)