



PATIENT

Zoe Runyan

SPECIES

Feline

BREED

Domestic Shorthair

SEX

Spayed female

AGE

10 years

WEIGHT

8.74 lbs

INTERPRETED BY

Eric Lindquist, DMV
DABVP, Cert. IVUSS

IMAGING PERFORMED BY

Dr. Brenner

HOSPITAL NAME

Riverside Animal Clinic

REFERRING VET

Dr. Brenner

INVOICE

75213

DATE

5/5/26

PRESENTING CLINICAL SIGNS

History: November 2025 noted minor intestinal thickening on ultrasound December 2025 Uroliths dissolved by diet. Cat acting significantly better on C/D diet, normal urination, no more over grooming ventral abdomen, still no GI symptoms.

Abnormal PE/Chem/CBC/UA Results: March 2026 normal exam.

ULTRASONOGRAPHIC EXAMINATION OF THE ABDOMEN

Urinary System

The **urinary bladder**, trigone, and pelvic urethra presented normal thicknesses and normal tone. The ureters were not visible which is normal. No uroliths or sediment were visualized and anechoic urine was present. No evidence of inflammatory or neoplastic changes was noted. Ureteral papillae were normal.

The **kidneys** revealed largely normal size and structure, corticomedullary definition and ratio (cortex 1/3 of medulla) were essentially maintained with some age-related loss of curvilinear patterns regarding the capsule and C/M junction. The cortices presented largely uniform texture with some increased echogenicity expected for this age patient. Medullary structure differed distinctly from that of the cortex and no evidence of pelvic dilation was present. Pelvic calculi were noted and were non-obstructive. Calculus on the right kidney measured 0.47 cm. The left and right kidney measured 3.6 cm.

Adrenal Glands

Both **adrenal glands** were visualized and recognized as having normal shape, size, position and echogenicity for this breed. The phrenic vasculature, glandular echogenicity and detail were unremarkable. Capsule, cortex, and medullary definition were normal for this age patient. The left adrenal gland measured 0.29 cm. The right adrenal gland measured 0.43 cm.

Spleen

The **spleen** presented a smooth homogeneous parenchyma hyperechoic to liver and renal cortical parenchyma. The capsule was smooth without noticeable expansion or deviation from within the spleen or adjacent pathology. The splenic vasculature demonstrated normal volume without signs of congestion or thrombosis. No sonographic evidence of acute or chronic inflammatory, neoplastic, or infarctual changes was noted.

Liver

The **liver** images submitted revealed subjectively normal liver size, contour, and structure. Parenchymal echogenicity was naturally coarse and hypoechoic to the spleen. Vascular and biliary tracts were of normal volume with no evidence of congestion. The gallbladder presented acceptably thin walls with primarily anechoic content. The cystic and common bile ducts were normal. No pathological hepatic



PATIENT

Zoe Runyan

SPECIES

Feline

BREED

Domestic Shorthair

SEX

Spayed female

AGE

10 years

WEIGHT

8.74 lbs

INTERPRETED BY

Eric Lindquist, DMV
DABVP, Cert. IVUSS

IMAGING PERFORMED BY

Dr. Brenner

HOSPITAL NAME

Riverside Animal Clinic

REFERRING VET

Dr. Brenner

INVOICE

75213

DATE

5/5/26

lymphadenopathy was evident. No overt structural evidence of inflammatory, infiltrative or regenerative pathology was evident.

Gastrointestinal

The **gastrointestinal** presentation revealed mild uniform prominence of the gastric mucosa as well as areas of "ropey" small intestinal wall with slight disruption of the normal 1:3 muscularis/mucosal ratio. The intestinal submucosa was slightly irregular, thickened and hyperechoic suggestive of low grade, chronic disease. Distal thickening was noted and measured up to 0.35 cm with no loss of mural detail. No concerning lymphadenopathy was visible. No evidence of obstruction was present. Chronic inflammatory bowel disease is likely with a low possibility of an early neoplastic event such as lymphoma. Full thickness tissue biopsies via open laparotomy, ideally guided by intraoperative ultrasound in order to obtain the most representative mural sample, would be necessary to rule out this possibility.

Pancreas

The base and limbs of the **pancreas** were observed to be largely isoechoic to surrounding omental fat. Pancreatic duct and capsular contour were acceptably normal and parenchyma respected normal curvilinear patterns. No overt evidence of active inflammatory or neoplastic disease was noted.

ULTRASONOGRAPHIC FINDINGS

IBD GI Pattern. Muscularis hypertrophy was present with a 1:1 ratio.

Non-obstructive
nephrolithiasis.

INTERPRETATION OF THE FINDINGS & FURTHER RECOMMENDATIONS

Full thickness intestinal biopsies would be necessary for further definition, yet no overt neoplastic criteria is present at this time. Management for inflammatory bowel is recommended.



PATIENT

Zoe Runyan

SPECIES

Feline

BREED

Domestic Shorthair

SEX

Spayed female

AGE

10 years

WEIGHT

8.74 lbs

INTERPRETED BY

Eric Lindquist, DMV
DABVP, Cert. IVUSS

**IMAGING
PERFORMED BY**

Dr. Brenner

HOSPITAL NAME

Riverside Animal Clinic

REFERRING VET

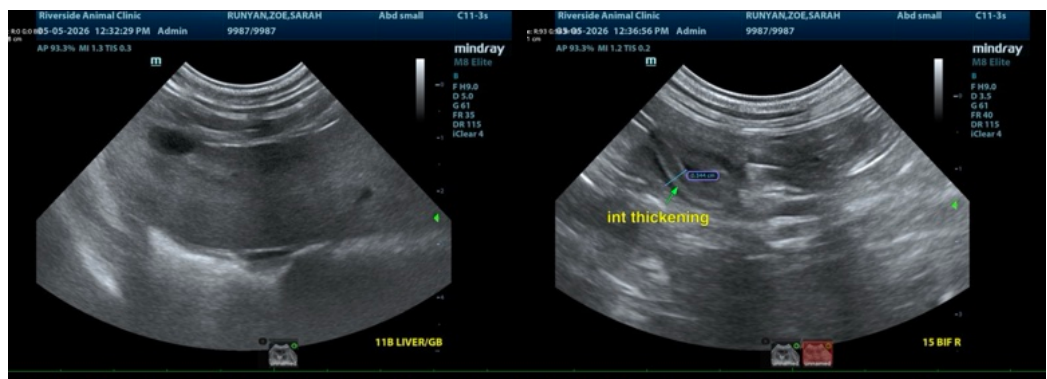
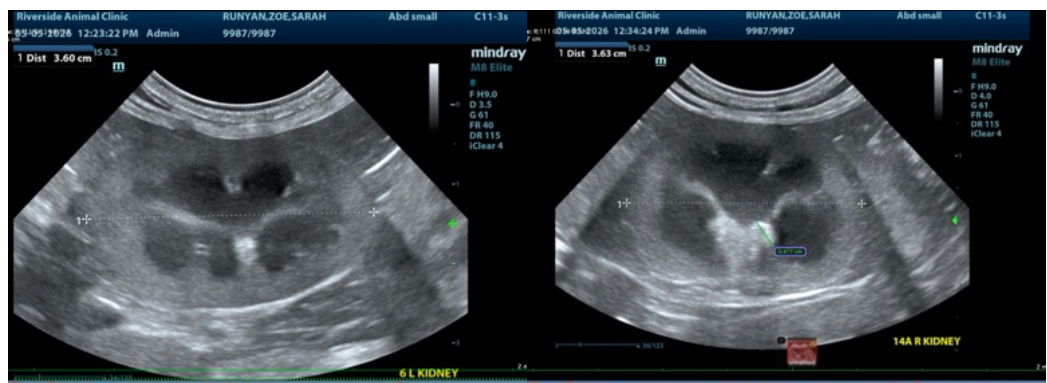
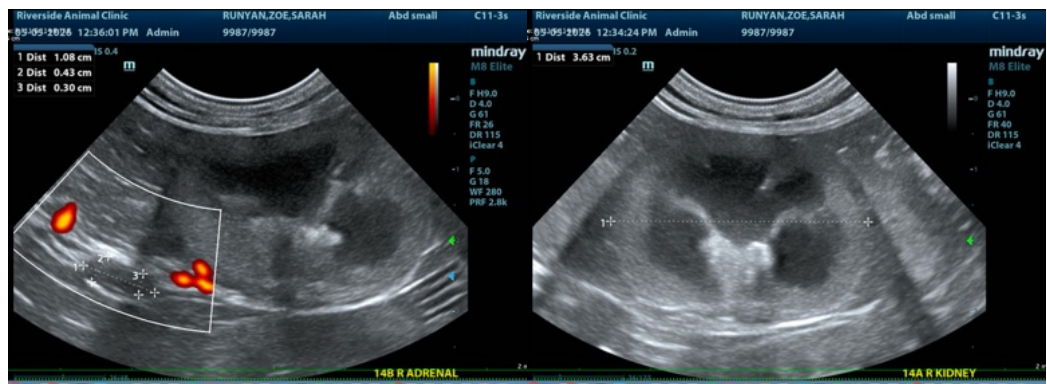
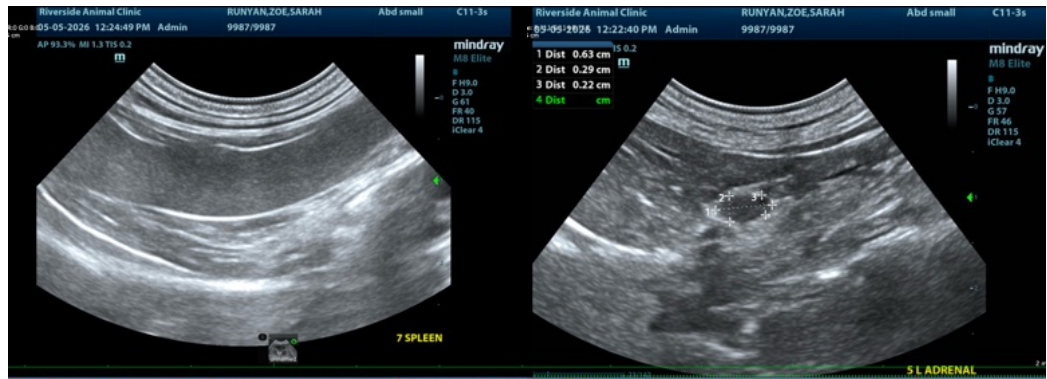
Dr. Brenner

INVOICE

75213

DATE

5/5/26





PATIENT

Zoe Runyan

SPECIES

Feline

BREED

Domestic Shorthair

SEX

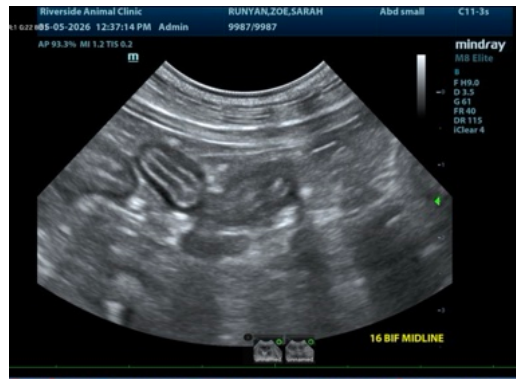Spayed female

AGE

10 years

WEIGHT

8.74 lbs



The information and recommendations provided are based on the images presented by the referring veterinarian/sonographer. No evaluation can be communicated regarding pathology that was not visible in the image/video clips provided.

Thank you for this referral. If the clinical or image interpretation does not parallel your findings or if I can be of any further assistance please contact me.

Eric Lindquist, DMV, DABVP (CFM), Cert. IVUSS, CEO of SonoPath.com

info@SonoPath.com

INTERPRETED BY

Eric Lindquist, DMV
DABVP, Cert. IVUSS

IMAGING PERFORMED BY

Dr. Brenner

HOSPITAL NAME

Riverside Animal Clinic

REFERRING VET

Dr. Brenner

INVOICE

75213

DATE

5/5/26