



PATIENT

Whisky Bott-
Wentworth

SPECIES

Canine

BREED

English Springer
Spaniel

SEX

Neutered Male

AGE

5 Years

WEIGHT

46 Pounds

INTERPRETED BY

Eric Lindquist, DMV,
DABVP (Canine &
Feline), Cert. IVUSS

**IMAGING
PERFORMED BY**

Rebecca Hamilton

HOSPITAL NAME

Willowbrook AC

REFERRING VET

Dr Bott-Wentworth

INVOICE

35951

DATE

5/5/26

PRESENTING CLINICAL SIGNS

History: Scanning, rule out cancer, R/O cardiopathology, positive for coccidia and round worms.

Meds: Dasaquin, Sentinel spectrum, Bravecto

Abnormal PE/Chem/CBC/UA Results: WBC 5.6 (5.8-16.2) Amylase 318 (337-1469) +roundworm and Coccidia, USG, 1.004 not first am urine.

ULTRASONOGRAPHIC EXAMINATION OF THE HEART & ABDOMEN

CANINE CARDIAC PARAMETERS	MR VMAX (m/s)	TR VMAX (m/s)	LA/AO (M-Mode)	LA/AO (Heart Base; Swe)	FS (%)	EF (%)	EPSS (cm)
NORMAL PARAMETER	4.5-5.5	<2.7	1.3	Up to 1.6	28-40	40-100	<0.6
PATIENT	--	--	1.0	1.1	--	--	0.8
CANINE CARDIAC PARAMETERS	HR (BPM)	AV VMAX (m/s)	PV MAX (m/s)	BODY WEIGHT (lbs)	LAD LA MAX 4 Chamber	LVIDd Avg; 2D and m- mode short axis (cm)	LVIDs Avg; 2D and m-mode short axis (cm)
NORMAL PARAMETER	50-100	0.7-1.7	0.7-1.6				
PATIENT	60	1.30	.70	46	--	3.2	--

Cardiac Presentation

The echocardiogram in this patient demonstrated normal **left atrial** size based on 3 separate methods of LA evaluation. The cranial and caudal **mitral** valve leaflets presented normal linear structure, extension in systole, and union in diastole with normal kinesis. The left ventricle presented normal volume and wall thickness, yet contractility was slightly subnormal. The **right atrium** and auricle revealed normal size, structure and content. No evidence of masses was noted. **Tricuspid** valvular assessment demonstrated adequate linear morphology and kinesis. The **right ventricle** was of normal size (1/3 diameter of LV), chordae structure, myocardial echogenicity and thickness. **Pulmonary outflow** tract assessment revealed normal valve structure, laminar flow, and diameter (approx.1:1 pa/ao ratio). No visible **pericardial** or free pleura fluid was noted. The cranial **mediastinum and pericardial and extra-cardiac regions** were free of masses in the visible window.

Urinary System

The **urinary bladder**, trigone, and pelvic urethra presented normal thicknesses and normal tone. The ureters were not visible which is normal. No uroliths or sediment were visualized and anechoic urine was present. No evidence of inflammatory or neoplastic changes were noted. Ureteral papillae were



PATIENT

Whisky Bott-
Wentworth

SPECIES

Canine

BREED

English Springer
Spaniel

SEX

Neutered Male

AGE

5 Years

WEIGHT

46 Pounds

INTERPRETED BY

Eric Lindquist, DMV,
DABVP (Canine &
Feline), Cert. IVUSS

**IMAGING
PERFORMED BY**

Rebecca Hamilton

HOSPITAL NAME

Willowbrook AC

REFERRING VET

Dr Bott-Wentworth

INVOICE

35951

DATE

5/5/26

normal. The pelvic urethra was imaged 2.0 cm beyond the cystourethral junction. The residual prostate measured 1.0 cm.

The **kidneys** revealed normal size and structure, corticomedullary definition and ratio for this age. The cortices presented largely uniform texture with normal echogenic relationship to liver and spleen. Medullary structure differed distinctly from the cortex, and no evidence of pelvic dilation was present. The capsules were acceptably uniform without significant irregularities. The left kidney measured 6.0 cm. The right kidney measured 6.0 cm.

Adrenal Glands

Both **adrenal glands** were visualized and recognized as having normal shape, size, position and echogenicity for this breed. The phrenic vasculature, glandular echogenicity and detail were unremarkable. Capsule, cortex, and medullary definition were normal for this age patient. The left adrenal gland measured 0.5 cm. The right adrenal gland measured 0.5 cm at the caudal pole and 0.7 cm at the cranial pole.

Spleen

The **spleen** presented a smooth homogeneous parenchyma hyperechoic to liver and renal cortical parenchyma. The capsule was smooth without noticeable expansion or deviation from within the spleen or adjacent pathology. The splenic vasculature demonstrated normal volume without signs of congestion or thrombosis. No sonographic evidence of acute or chronic inflammatory, neoplastic, or infarctual changes were noted.

Liver

The **liver** images submitted revealed subjectively normal liver size, contour, and structure. Parenchymal echogenicity was naturally coarse and hypoechoic to the spleen. Vascular and biliary tracts were of normal volume with no evidence of congestion. The gallbladder presented acceptably thin walls with primarily anechoic content. The cystic and common bile ducts were normal. No pathological hepatic lymphadenopathy was evident. No overt structural evidence of inflammatory, infiltrative or regenerative pathology was evident.

Gastrointestinal

Examination of the **gastrointestinal tract** revealed a stomach and intestine free of stasis, of normal wall thickness, acceptable curvilinear mural detail, and peristaltic activity. Small and large intestine demonstrated normal luminal chyme and stool consistency respectively. No obstructive or overt infiltrative disease was noted. No associated abnormal lymphatic activity was noted.

Pancreas

The base and limbs of the **pancreas** were observed to be largely isoechoic to surrounding omental fat. Pancreatic duct and capsular contour were acceptably normal, and parenchyma respected normal curvilinear patterns. No overt evidence of active inflammatory or neoplastic disease was noted.

ULTRASONOGRAPHIC FINDINGS

- Left ventricle normal volume and wall thickness, yet contractility was slightly subnormal.
- Normal abdomen- no evidence of pathology



PATIENT

Whisky Bott-
 Wentworth

SPECIES

Canine

BREED

English Springer
 Spaniel

SEX

Neutered Male

AGE

5 Years

WEIGHT

46 Pounds

INTERPRETED BY

Eric Lindquist, DMV,
 DABVP (Canine &
 Feline), Cert. IVUSS

IMAGING PERFORMED BY

Rebecca Hamilton

HOSPITAL NAME

Willowbrook AC

REFERRING VET

Dr Bott-Wentworth

INVOICE

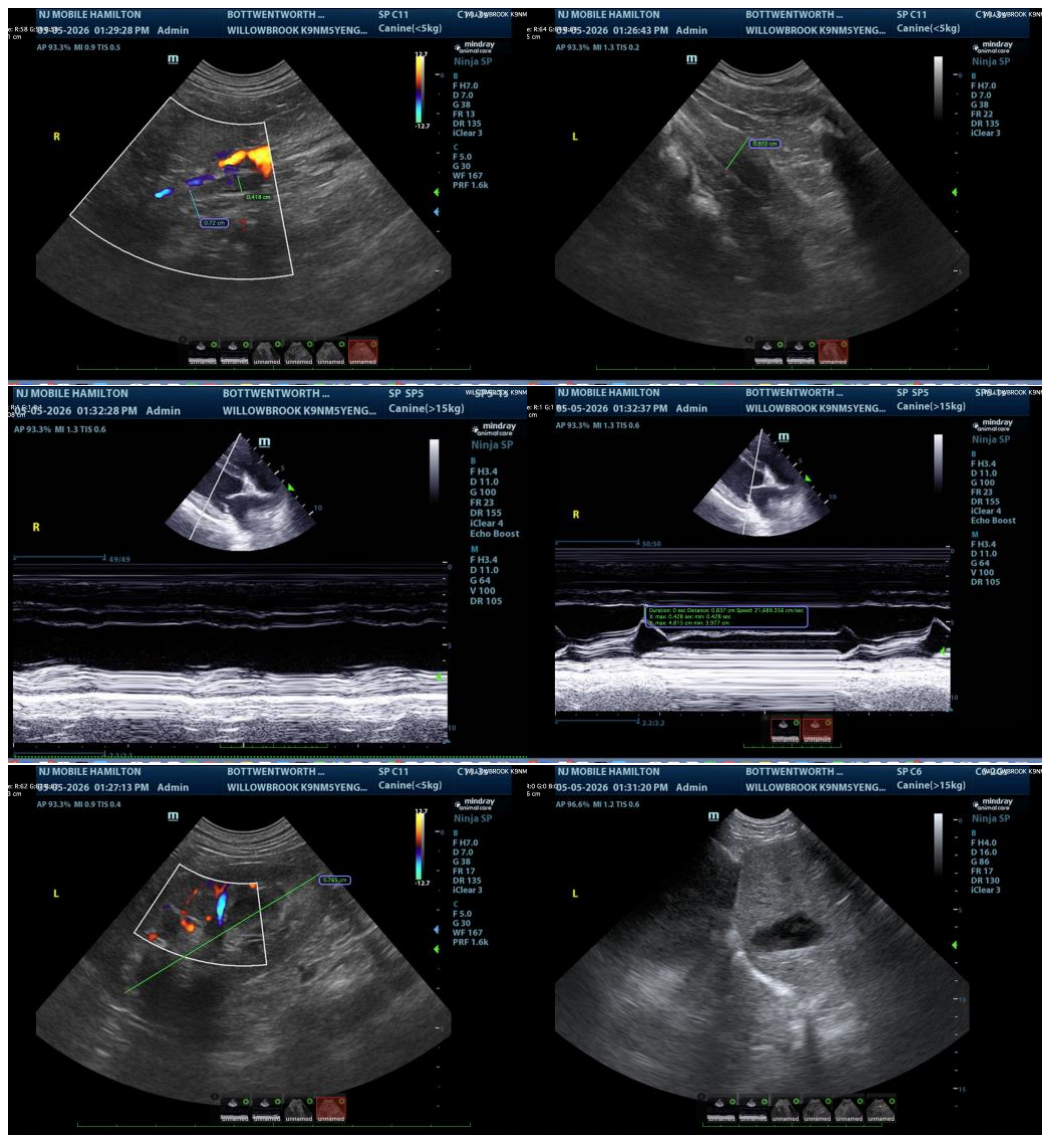
35951

DATE

5/5/26

INTERPRETATION OF THE FINDINGS & FURTHER RECOMMENDATIONS

Contractility was slightly subnormal, which would be normal for a sedated patient, however, if not sedated, then other systemic causes, such as hypothyroidism, Addison's and bradyarrhythmia should all be investigated. Dietary issues with taurine deficiency are also a potential. Otherwise, if the patient is an athletic patient, this may be a normal variant.





PATIENT

Whisky Bott-
 Wentworth

SPECIES

Canine

BREED

English Springer
 Spaniel

SEX

Neutered Male

AGE

5 Years

WEIGHT

46 Pounds

INTERPRETED BY

Eric Lindquist, DMV,
 DABVP (Canine &
 Feline), Cert. IVUSS

**IMAGING
 PERFORMED BY**

Rebecca Hamilton

HOSPITAL NAME

Willowbrook AC

REFERRING VET

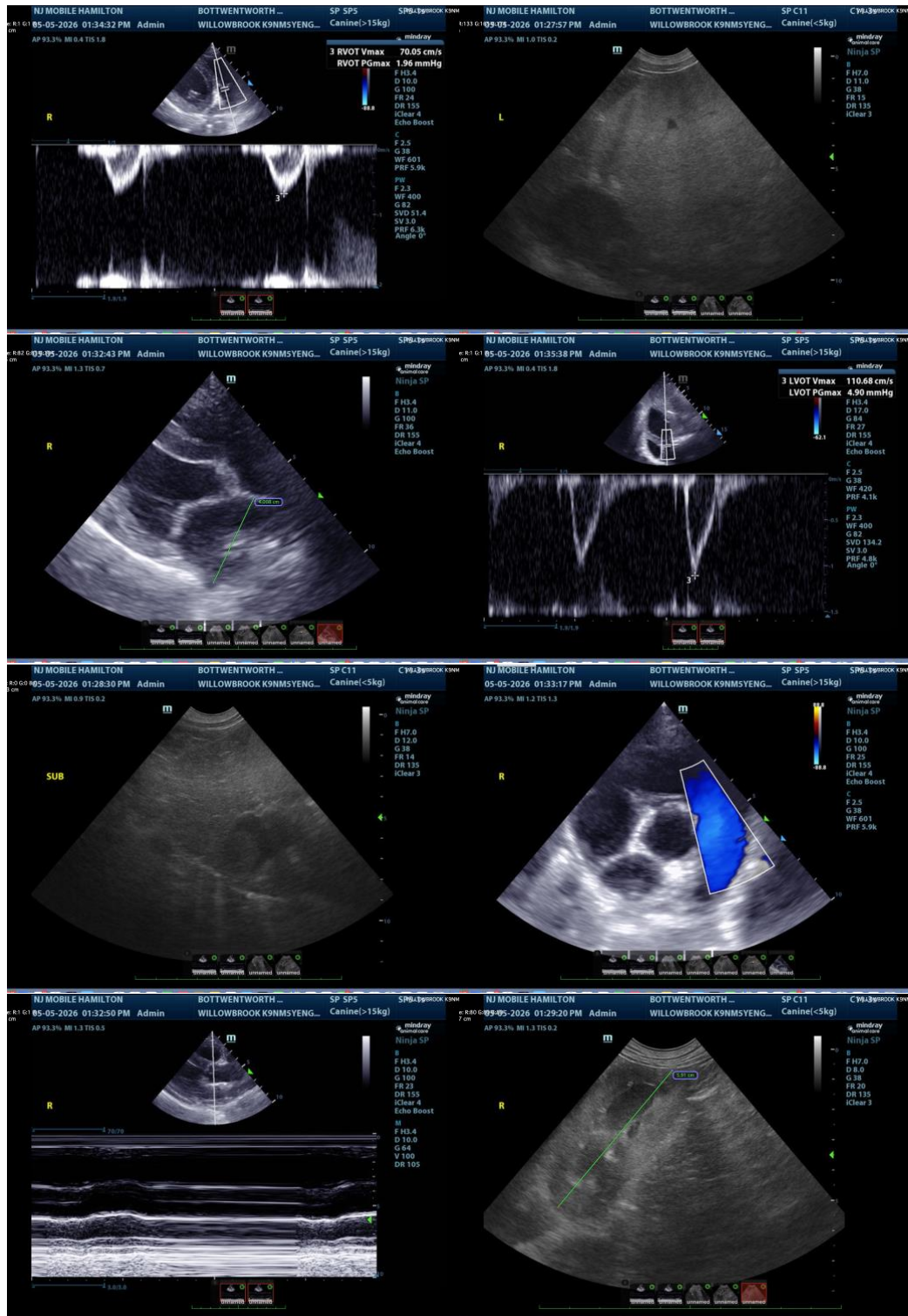
Dr Bott-Wentworth

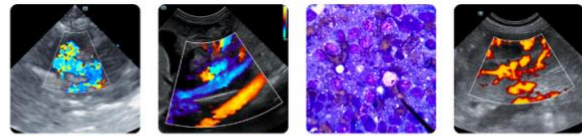
INVOICE

35951

DATE

5/5/26





PATIENT

Whisky Bott-
Wentworth

SPECIES

Canine

BREED

English Springer
Spaniel

SEX

Neutered Male

AGE

5 Years

WEIGHT

46 Pounds

INTERPRETED BY

Eric Lindquist, DMV,
DABVP (Canine &
Feline), Cert. IVUSS

**IMAGING
PERFORMED BY**

Rebecca Hamilton

HOSPITAL NAME

Willowbrook AC

REFERRING VET

Dr Bott-Wentworth

INVOICE

35951

DATE

5/5/26

The information and recommendations provided are based on the images presented by the referring veterinarian/sonographer. No evaluation can be communicated regarding pathology that was not visible in the image/video clips provided.

Thank you for this referral. If the clinical or image interpretation does not parallel your findings or if I can be of any further assistance please contact me.

Eric Lindquist, DMV, DABVP(CFM), Cert. IVUSS,
CEO, Owner, Founder -- SonoPath.com
info@SonoPath.com