



PATIENT

Teddy Streiter

SPECIES

Canine

BREED

Airdale Terrier

SEX

Male

AGE

8 Years

WEIGHT

77.3 lbs

INTERPRETED BY

Eric Lindquist, DMV,
DABVP(CFM), Cert.
IVUSS

IMAGING PERFORMED BY

Vincent Ravancho CVT

HOSPITAL NAME

Whippany Veterinary
Hospital

REFERRING VET

Dr. Enoch/Smith

INVOICE

15819

DATE

05/05/26

PRESENTING CLINICAL SIGNS

Cardiac Murmur 3/6. Recurrent hematuria w/ no bacterial component. R/O valvular dz, prostate dz, calculi, neoplasia. Sedated with Gabapentin, Acepromazine, Melatonin 5mg 2hrs before.

Abnormal PE/Chem/CBC/UA Results: U/A - increased RBC, pH 8-9, Struvite crystals.

ULTRASONOGRAPHIC EXAMINATION OF THE HEART & ABDOMEN

CANINE CARDIAC PARAMETERS	MR VMAX (m/s)	TR VMAX (m/s)	LA/AO (M-Mode)	LA/AO (Heart Base; Swe)	FS (%)	EF (%)	EPSS (cm)
NORMAL PARAMETER	4.5-5.5	<2.7	1.3	Up to 1.6	28-40	40-100	<0.6
PATIENT	5.58	2.0	1.0	1.2	30	59	0.5
CANINE CARDIAC PARAMETERS	HR (BPM)	AV VMAX (m/s)	PV MAX (m/s)	BODY WEIGHT (lbs)	LAD LA MAX 4 Chamber	LVIDd Avg; 2D and m-mode short axis (cm)	LVIDs Avg; 2D and m-mode short axis (cm)
NORMAL PARAMETER	50-100	0.7-1.7	0.7-1.6				
PATIENT	80	1.9	10.7	77.3	4.3	3.7	

Cardiac Presentation

The echocardiogram in this patient demonstrated normal **left atrial** size based on 3 different LA measurement methods. Chamber volumes and echogenicity were normal. The cranial and caudal **mitral** valve leaflets presented vegetative thickening consistent with endocardiosis. Doppler indicated measurable insufficiency. The **left ventricle** presented normal thicknesses with linear contour and was not dilated nor restricted. The **myocardium** presented normal echogenicity without subjective evidence of significant fibrotic or ischemic disease. **Contractility** of the ventricular walls was adequate and in normal range for this patient evidenced by the fractional shortening measurement and subjective evaluation of the different regions of the myocardium. The **left ventricular outflow** tract demonstrated normal laminar flow and subjective structural integrity. The **right atrium** and auricle revealed normal size, structure and content. No evidence of masses was noted or chamber overload. **Tricuspid** valvular assessment demonstrated measurable insufficiency. The **right ventricle** was of normal size (1/3 diameter of LV), chordae structure, myocardial echogenicity and thickness. Trivial **pulmonic** insufficiency was noted yet not clinically significant. No visible **pericardial** or free pleura fluid was noted. No echographically detectable evidence of infiltrative disease was visible. The cranial **mediastinum and pericardial regions** were free of masses in the visible window.

Urinary System

The **urinary bladder**, trigone, and pelvic urethra presented normal thicknesses and normal tone. The ureters were not visible which is normal. No uroliths or sediment were visualized, and anechoic urine



PATIENT

Teddy Streiter

SPECIES

Canine

BREED

Airdale Terrier

SEX

Male

AGE

8 Years

WEIGHT

77.3 lbs

INTERPRETED BY

Eric Lindquist, DMV,
DABVP(CFM), Cert.
IVUSS

IMAGING PERFORMED BY

Vincent Ravancho CVT

HOSPITAL NAME

Whippany Veterinary
Hospital

REFERRING VET

Dr. Enoch/Smith

INVOICE

15819

DATE

05/05/26

was present. No evidence of inflammatory or neoplastic changes were noted. Ureteral papillae were normal.

The **prostate** was uniformly enlarged with lobar swelling appeared to impinge upon the urethra and mildly deviate the descending colon. The prostatic tissue was hyperechoic containing focal areas of decreased echogenicity. These changes are suggestive of either chronic inflammatory episodes, benign cystic pathology or both. Underlying neoplasia cannot be completely ruled-out but is lower on the differential list. This presentation is most consistent with benign prostatic hyperplasia with possible active prostatitis. Neutering or off-label Finasteride (Propecia) (0.1-0.5 mg/kg Sid) treatment is indicated +/- FNA or prostatic wash cytology and culture. The prostate measured 4.1 cm. The left testicle was slight subnormal in size with moderate degenerative changes measuring 3.3 cm. The right testicle was unremarkable. The prostate presented with minor hypoechoic nodular change measuring 0.50 cm.

The **kidneys** revealed normal size and structure, corticomedullary definition and ratio for this age. The cortices presented largely uniform texture with normal echogenic relationship to liver and spleen. Medullary structure differed distinctly from the cortex and no evidence of pelvic dilation was present. The capsules were acceptably uniform without significant irregularities. The left kidney measured 6.95 cm in length. The right kidney measured 7.77 cm in length.

Adrenal Glands

Both **adrenal glands** were visualized and recognized as having normal shape, size, position and echogenicity for this breed. The phrenic vasculature, glandular echogenicity and detail were unremarkable. Capsule, cortex, and medullary definition were normal for this age patient. The left adrenal gland measured 3.0 cm x 0.54 cm width at the cranial pole and 0.59 cm width at the caudal pole. The right adrenal gland measured 1.49 cm x 0.87 cm width at the cranial pole and 0.53 cm width at the caudal pole.

Spleen

The **spleen** revealed a focal 0.50 cm nodule in the mid cranial body that does not appear disruptive however, should be monitored.

Liver

The **liver** images submitted revealed subjectively normal liver size, contour, and structure. Parenchymal echogenicity was naturally coarse and hypoechoic to the spleen. Vascular and biliary tracts were of normal volume with no evidence of congestion. The gallbladder presented acceptably thin walls with primarily anechoic content. The cystic and common bile ducts were normal. No pathological hepatic lymphadenopathy was evident. No overt structural evidence of inflammatory, infiltrative or regenerative pathology was evident.

Gastrointestinal

Examination of the **gastrointestinal tract** revealed a stomach and intestine free of stasis, of normal wall thickness, acceptable curvilinear mural detail, and peristaltic activity. Small and large intestine demonstrated normal luminal chyme and stool consistency respectively. No obstructive or overt infiltrative disease was noted. No associated abnormal lymphatic activity was noted.

Pancreas



PATIENT

Teddy Streiter

The base and limbs of the **pancreas** were observed to be largely isoechoic to surrounding omental fat. Pancreatic duct and capsular contour were acceptably normal and parenchyma respected normal curvilinear patterns. No overt evidence of active inflammatory or neoplastic disease was noted.

SPECIES

Canine

ULTRASONOGRAPHIC FINDINGS

- Compensated stage B1 valvular disease.
- Left testicle degenerative changes.
- BPH prostate with minor nodular change.
- Focal splenic nodule.

BREED

Airdale Terrier

INTERPRETATION OF THE FINDINGS & FURTHER RECOMMENDATIONS

SEX

Male

The heart is stable without clinical disease. No overt contraindication for anesthesia of brief to moderate duration. I suggest Torbutrol premed, Propofol induction, Isoflo maintenance or similar protocol if anesthesia is desired. Blood pressure, EKG and chest radiographs are recommended if not already performed. Target white coat negative systolic pressure of < 160 mmHg. If higher than this ACE-inhibitor is suggested to reach this level. Recheck echocardiogram is recommended in 6-12 months, earlier if murmur grade increases or clinical signs initiate.

AGE

8 Years

WEIGHT

77.3 lbs

Recheck sonogram in one month regarding the splenic nodule. Neutering should be considered regarding the prostatic and testicular situation if any clinical signs are persistently an issue. Otherwise, the following protocol could be considered:

INTERPRETED BY

Eric Lindquist, DMV,
DABVP(CFM), Cert.
IVUSS

Finasteride at 1 mg/kg/day can be utilized as an off-label approach to reducing prostatic size in BPH cases. Coverage for prostatitis would also likely be appropriate with Fluoroquinolone/Baytril or similar. A recheck sonogram is recommended in 3-4 weeks with reassessment of the urinalysis and evaluation of any inflammatory sediment.

**IMAGING
PERFORMED BY**

Vincent Ravancho CVT

HOSPITAL NAME

Whippany Veterinary
Hospital

REFERRING VET

Dr. Enoch/Smith

INVOICE

15819

DATE

05/05/26



PATIENT

Teddy Streiter

SPECIES

Canine

BREED

Airdale Terrier

SEX

Male

AGE

8 Years

WEIGHT

77.3 lbs

INTERPRETED BY

Eric Lindquist, DMV,
 DABVP(CFM), Cert.
 IVUSS

IMAGING PERFORMED BY

Vincent Ravancho CVT

HOSPITAL NAME

Whippany Veterinary
 Hospital

REFERRING VET

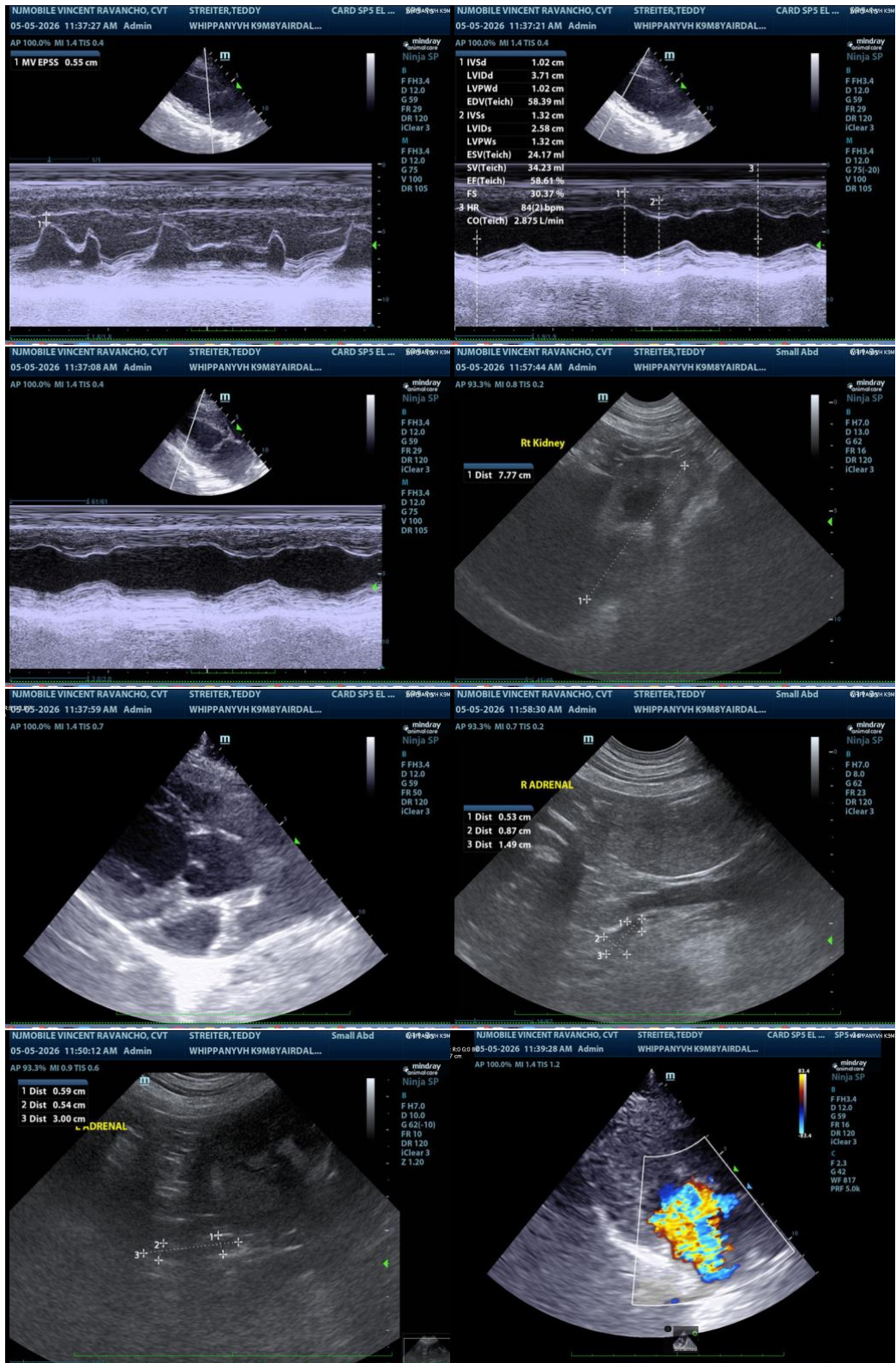
Dr. Enoch/Smith

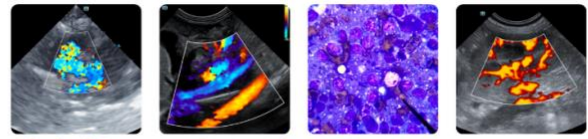
INVOICE

15819

DATE

05/05/26





PATIENT

Teddy Streiter

SPECIES

Canine

BREED

Airdale Terrier

SEX

Male

AGE

8 Years

WEIGHT

77.3 lbs

INTERPRETED BY

Eric Lindquist, DMV,
 DABVP(CFM), Cert.
 IVUSS

IMAGING PERFORMED BY

Vincent Ravancho CVT

HOSPITAL NAME

Whippany Veterinary
 Hospital

REFERRING VET

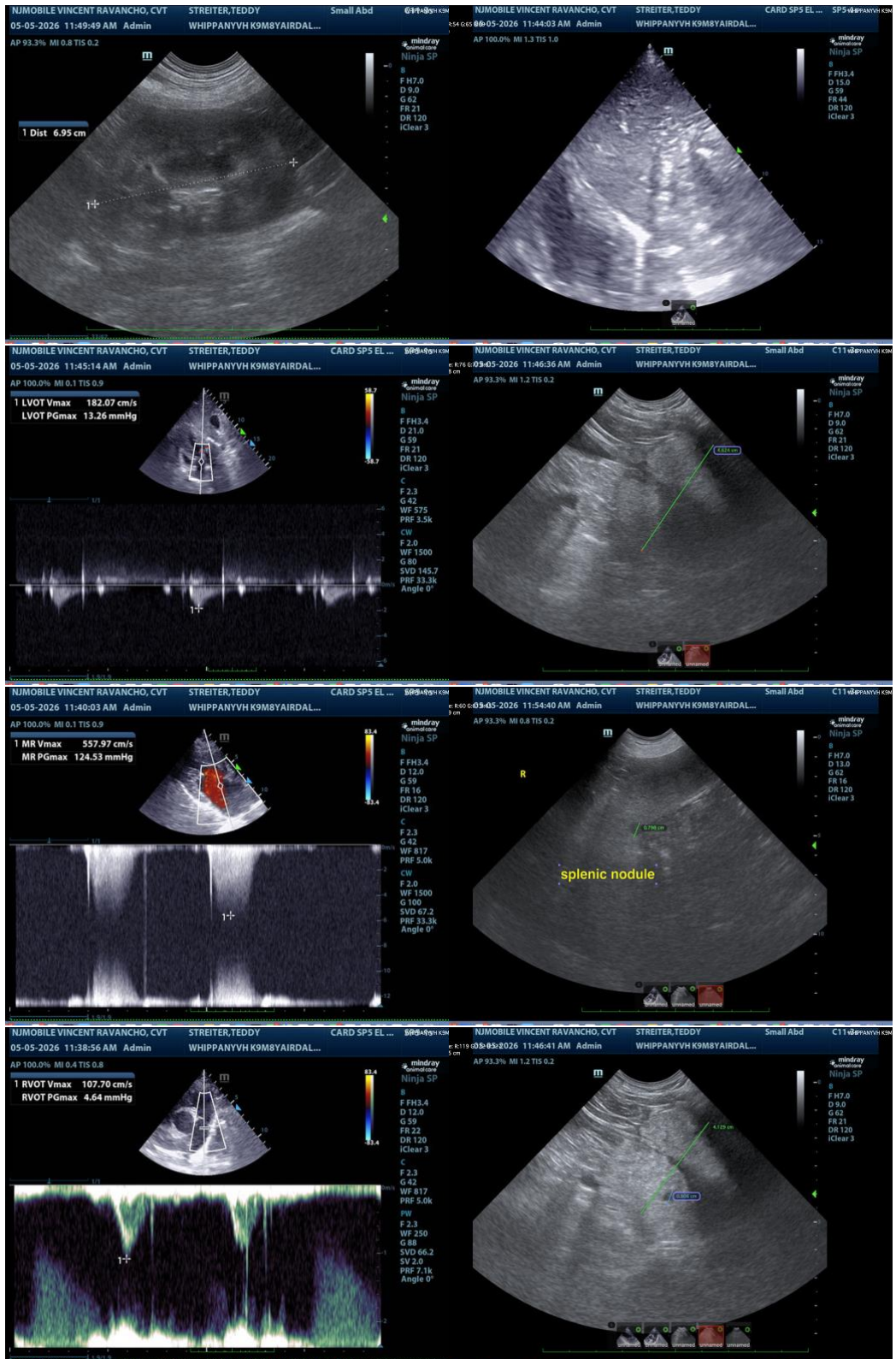
Dr. Enoch/Smith

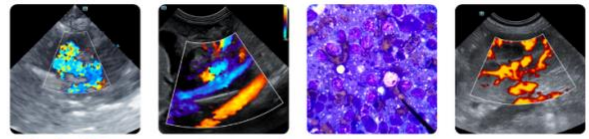
INVOICE

15819

DATE

05/05/26





PATIENT

Teddy Streiter

The information and recommendations provided are based on the images presented by the referring veterinarian/sonographer. No evaluation can be communicated regarding pathology that was not visible in the image/video clips provided.

SPECIES

Canine

Thank you for this referral. If the clinical or image interpretation does not parallel your findings or if I can be of any further assistance, please contact me.

BREED

Airdale Terrier

Eric Lindquist, DMV, DABVP(CFM), Cert. IVUSS,

CEO, Owner, Founder -- SonoPath.com

info@SonoPath.com

SEX

Male

AGE

8 Years

WEIGHT

77.3 lbs

INTERPRETED BY

Eric Lindquist, DMV,
DABVP(CFM), Cert.
IVUSS

**IMAGING
PERFORMED BY**

Vincent Ravancho CVT

HOSPITAL NAME

Whippany Veterinary
Hospital

REFERRING VET

Dr. Enoch/Smith

INVOICE

15819

DATE

05/05/26