



PATIENT

Clyde Morgan

SPECIES

Canine

BREED

Chihuahua

SEX

Neutered Male

AGE

12 Years

WEIGHT

5.8

INTERPRETED BY

Eric Lindquist, DMV,
DABVP(CFM), Cert.
IVUSS

IMAGING PERFORMED BY

Bill McGee DVM,
DABVP

HOSPITAL NAME

Bridgeport Animal
Hospital PLLC

REFERRING VET

Lauren Smith-Bennett
DVM

INVOICE

15847

DATE

05/05/26

PRESENTING CLINICAL SIGNS

History of a chronic cough. An echocardiogram was performed a year ago showing B1 valvular disease. A recheck echo was requested

ULTRASONOGRAPHIC EXAMINATION OF THE HEART

CANINE CARDIAC PARAMETERS	MR VMAX (m/s)	TR VMAX (m/s)	LA/AO (M-Mode)	LA/AO (Heart Base; Swe)	FS (%)	EF (%)	EPSS (cm)
NORMAL PARAMETER	4.5-5.5	<2.7	1.3	Up to 1.6	28-40	40-100	<0.6
PATIENT	>5.0	3.0	1.3	1.4	48	82	NM
CANINE CARDIAC PARAMETERS	HR (BPM)	AV VMAX (m/s)	PV MAX (m/s)	BODY WEIGHT	LAD LA MAX 4 Chamber	LVIDd Avg; 2D and m-mode short axis (cm)	LVIDs Avg; 2D and m-mode short axis (cm)
NORMAL PARAMETER	50-100	0.7-1.7	0.7-1.6				
PATIENT	80-90	0.98	0.95	5.8	1.85	1.9	--

Cardiac Presentation

The echocardiogram in this patient revealed mitral and tricuspid insufficiency with normal volumes in all four chambers. Contractility was adequate and compensatory. Periodic arrhythmia was noted. No pericardial or pleural effusion was present.

ULTRASONOGRAPHIC FINDINGS

- Stable stage B1 valvular disease with MR and TR.

INTERPRETATION OF THE FINDINGS & FURTHER RECOMMENDATIONS

The cough is noncardiogenic in this patient. The heart is stable without clinical disease. No overt contraindication for anesthesia of brief to moderate duration. I suggest Torbutrol premed, Propofol induction, Isoflo maintenance or similar protocol if anesthesia is desired. Blood pressure, EKG and chest radiographs are recommended if not already performed. Target white coat negative systolic pressure of < 160 mmHg. If higher than this ACE-inhibitor is suggested to reach this level. Recheck echocardiogram is recommended in 6-12 months, earlier if murmur grade increases or clinical signs initiate.



PATIENT

Clyde Morgan

SPECIES

Canine

BREED

Chihuahua

SEX

Neutered Male

AGE

12 Years

WEIGHT

5.8

INTERPRETED BY

Eric Lindquist, DMV,
DABVP(CFM), Cert.
IVUSS

IMAGING PERFORMED BY

Bill McGee DVM,
DABVP

HOSPITAL NAME

Bridgeport Animal
Hospital PLLC

REFERRING VET

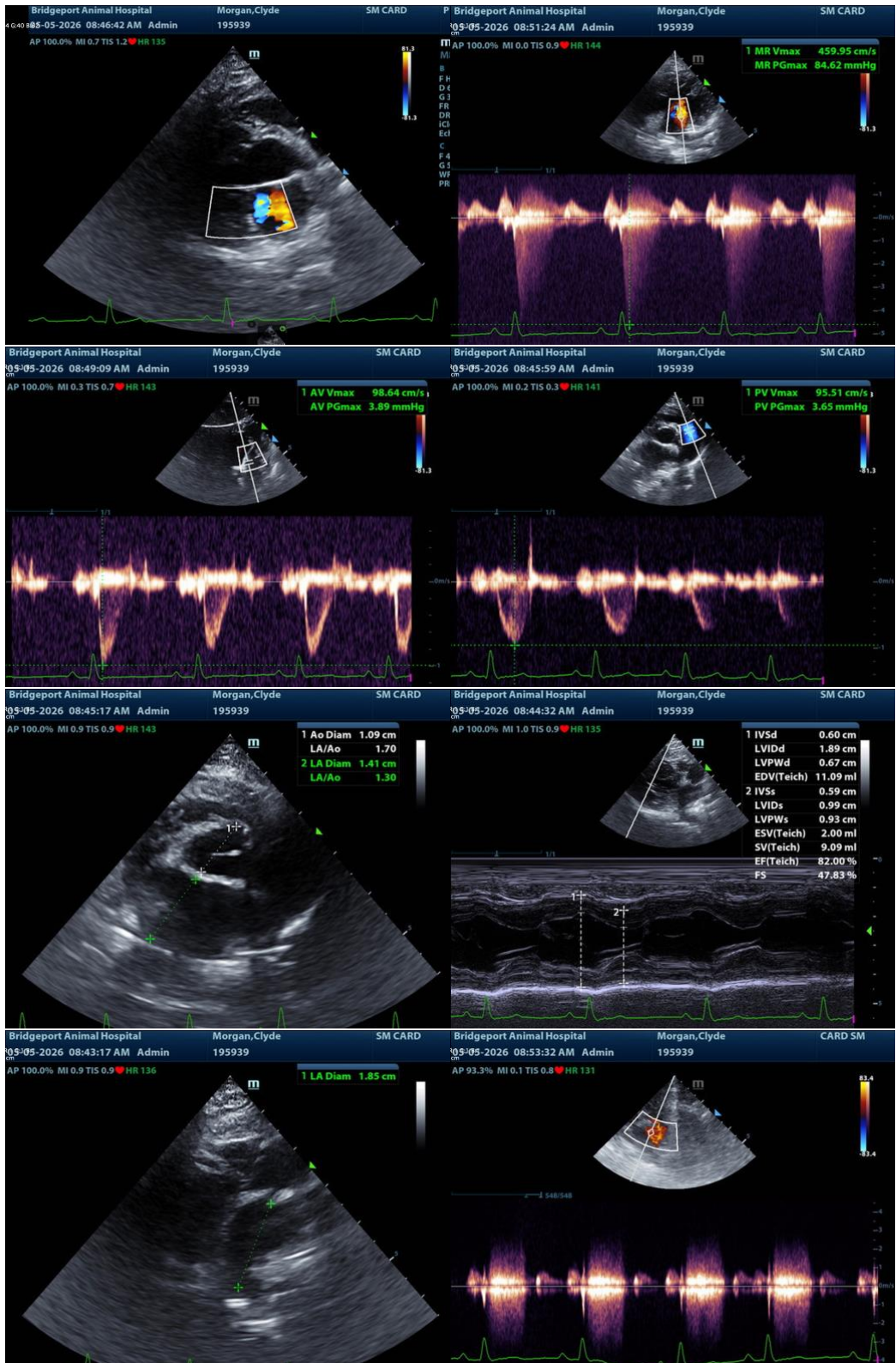
Lauren Smith-Bennett
DVM

INVOICE

15847

DATE

05/05/26





PATIENT

Clyde Morgan

SPECIES

Canine

BREED

Chihuahua

SEX

Neutered Male

AGE

12 Years

WEIGHT

5.8

INTERPRETED BY

Eric Lindquist, DMV,
DABVP(CFM), Cert.
IVUSS

IMAGING PERFORMED BY

Bill McGee DVM,
DABVP

HOSPITAL NAME

Bridgeport Animal
Hospital PLLC

REFERRING VET

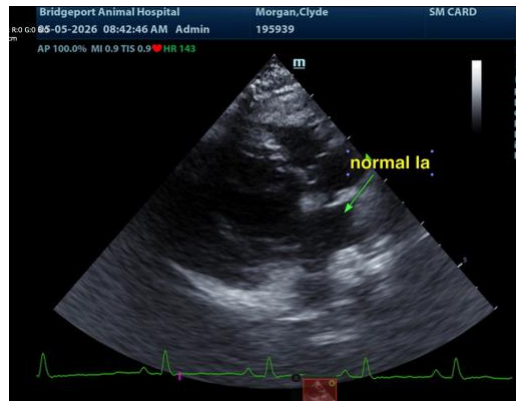
Lauren Smith-Bennett
DVM

INVOICE

15847

DATE

05/05/26



The information and recommendations provided are based on the images presented by the referring veterinarian/sonographer. No evaluation can be communicated regarding pathology that was not visible in the image/video clips provided.

Thank you for this referral. If the clinical or image interpretation does not parallel your findings or if I can be of any further assistance, please contact me.

Eric Lindquist, DMV, DABVP(CFM), Cert. IVUSS,

CEO, Owner, Founder -- SonoPath.com

info@SonoPath.com