

PATIENT

Wonton Clark

PRESENTING CLINICAL SIGNS

History: recheck from yesterday showed intestinal obstructive pattern dog has been NPO

SPECIES

Canine

ULTRASONOGRAPHIC EXAMINATION OF THE ABDOMEN

Gastrointestinal

Examination of the **gastrointestinal tract** revealed a resolved obstructive pattern. The stomach and upper small intestine are largely empty with a portion of jejunum that revealed a 3.0 cm, soft shadowing structure that appears to be static. However, the colon was filled with normal stool. The chyme appears to have passed into the colon. However, this region of the jejunum should be monitored.

BREED

Mix

SEX

Neutered male

ULTRASONOGRAPHIC FINDINGS

Resolved obstructive pattern.

AGE

2 years

INTERPRETATION OF THE FINDINGS & FURTHER RECOMMENDATIONS

I recommend outpatient therapy at this time with a recheck sonogram in 5-7 days if the patient is stable.

WEIGHT

42.6 lbs

INTERPRETED BY

Eric Lindquist, DMV
DABVP, Cert. IVUSS

IMAGING PERFORMED BY

Jenn

HOSPITAL NAME

Rockaway AH

REFERRING VET

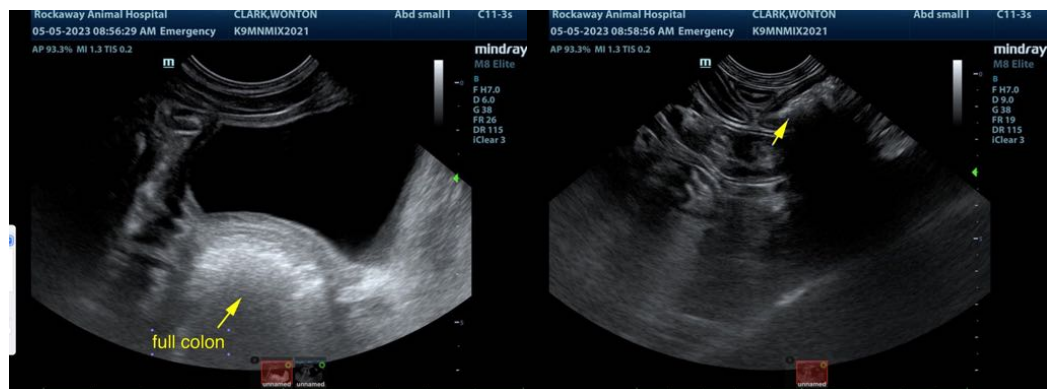
Dr. Maniar

INVOICE

44181

DATE

5/4/23



The information and recommendations provided are based on the images presented by the referring veterinarian/sonographer. No evaluation can be communicated regarding pathology that was not visible in the image/video clips provided.

Thank you for this referral. If the clinical or image interpretation does not parallel your findings or if I can be of any further assistance please contact me.

Eric Lindquist, DMV, DABVP, Cert. IVUSS, CEO of SonoPath.com
info@SonoPath.com