

**DATE PRESENTING CLINICAL SIGNS**

5/5/23

History: Decreased long term coat thickness/thinning of coat. Now drinking a lot of water; other pet coming for u/s based on cushings diagnosis, owner wants both pets checked but recommend low dose dex suppression test/ further evaluation

PATIENT

Nikko Rulli

Current Medications: Gabapentin 50mg BID, Denamarin Advanced SID

SPECIES

Canine

Lab Results: 12/20/22 Superchem CBC Accuplex- Accuplex 4 all negative. CBC- HCT 50%, Platelets 462 (170-400), rest WNL. Superchem- ALT 188 (12-118), ALP 1248 (5-131), Triglycerides 637 (29-291), chol 374 (92-324), BUN 17, CREAT 0.5. 05/01/2023: CBC w electrolytes, Chem 17- ALB 4.0 (2.2-3.9), ALT 331 (10-125), ALKPPOS 1780 (23-212), CI 108 (109-122), Retic 128.3 (10-110), PCT 0.51% (0.14-0.46)

BREED

Maltese Mix

Date of Previous IntraPet Ultrasound: 6/22/21. See attached.

Sedation: Not required to complete full diagnostic ultrasound.

Stat Report: Not requested.

Imaging Performed By: Rachel Brillhart, RDMS.

SEX

Neutered Male

ULTRASONOGRAPHIC EXAMINATION OF THE ABDOMEN**AGE**

12/1/11

Urinary System

The **urinary bladder**, trigone, and pelvic urethra presented normal thicknesses and normal tone. The ureters were not visible which is normal. No uroliths or sediment were visualized and anechoic urine was present. No evidence of inflammatory or neoplastic changes were noted. Ureteral papillae were normal.

WEIGHT

9.4 Pounds

The **kidneys** revealed largely normal size and structure, corticomedullary definition and ratio (cortex 1/3 of medulla) were essentially maintained with some moderate age-related loss of curvilinear patterns regarding the capsule and C/M junction. The cortices presented largely uniform texture with some increased echogenicity expected for his age patient. Medullary structure differed distinctly from that of the cortex and no evidence of pelvic dilation was present. The left kidney measured 4.37 cm. The right kidney measured 3.83 cm.

INTERPRETED BY

Eric Lindquist, DMV
DABVP, Cert. IVUSS

Adrenal Glands

The **adrenal glands** were prominent in size. The left adrenal gland measured 2.1 cm x 0.69 cm at the caudal pole and 0.67 cm at the cranial pole. The right adrenal gland measured the upper limits of normal, measuring 1.41 cm x 0.84 cm at the cranial pole and 0.65 cm at the caudal pole.

HOSPITAL NAME

Jacksonville VH

Spleen

The **spleen** presented a smooth homogeneous parenchyma hyperechoic to liver and renal cortical parenchyma. The capsule was smooth without noticeable expansion or deviation from within the spleen or adjacent pathology. The splenic vasculature demonstrated normal volume without signs of congestion or thrombosis. No sonographic evidence of acute or chronic inflammatory, neoplastic, or infarctual changes were noted.

REFERRING VET

Dr. Thai

INVOICE

22341

Liver

The **liver** was uniformly swollen. The liver presented coarse architecture with mildly increased portal markings and subtle, mixed echogenic changes. This is consistent with vacuolar hepatopathy and some level of remodeling and history of inflammatory component. There was no overt suspicion of neoplasia. This is mild change. Nonobstructive minor calculus(3.0 mm) was noted in the gallbladder.

Gastrointestinal

Examination of the **gastrointestinal tract** revealed a stomach and intestine free of stasis, of normal wall thickness, acceptable curvilinear mural detail, and peristaltic activity. Small and large intestine demonstrated normal luminal chyme and stool consistency respectively. No obstructive or overt infiltrative disease was noted. No associated abnormal lymphatic activity was noted.

Pancreas

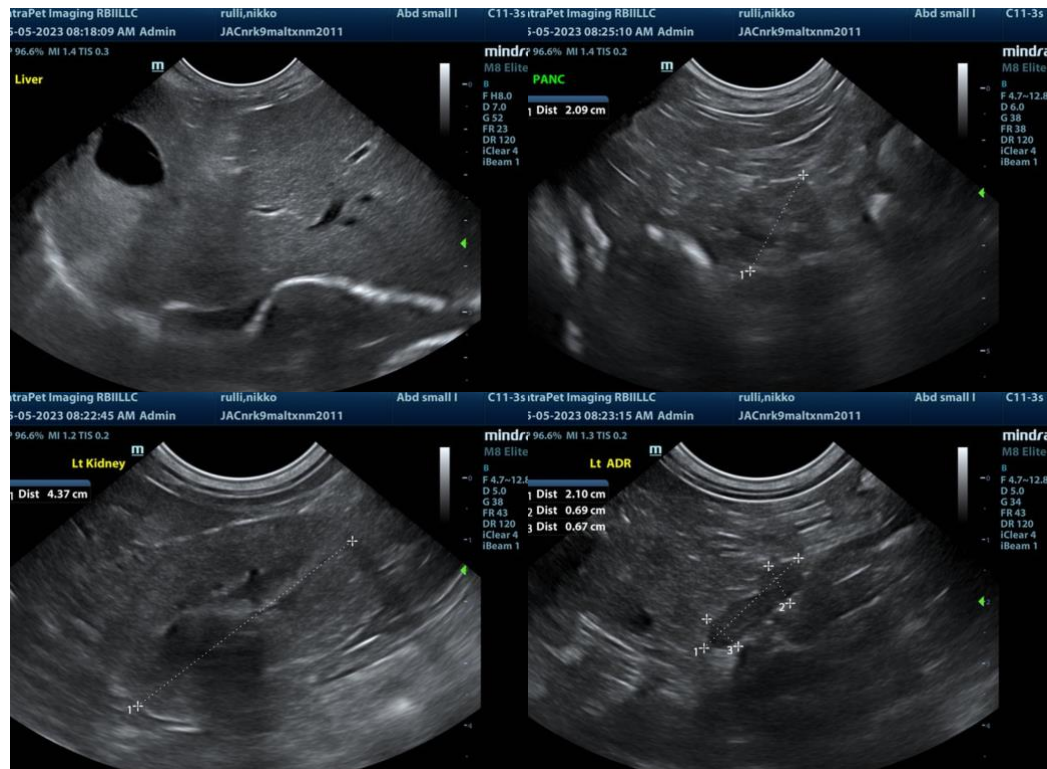
The **pancreas** was prominent, hypoechoic and irregular with remodeling. The left limb measured up to 2.0 cm.

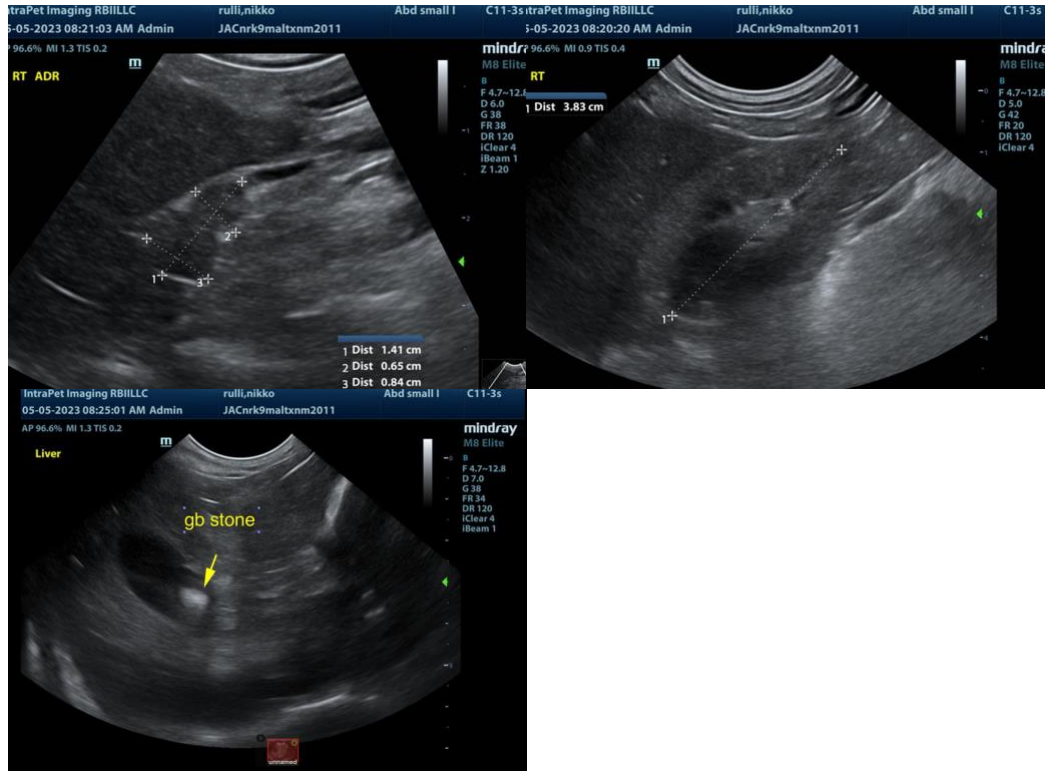
ULTRASONOGRAPHIC FINDINGS

- Benign hepatopathy with minor remodeling
- Gallbladder calculus- ursodiol therapy could be considered to attempt to dissolve the calculus, however, it's highly variable in effectiveness patient to patient.
- Pancreatic remodeling, likely owing to past episodes of pancreatitis
- Prominent adrenal glands, potential emerging PDH
- Age-related renal changes

INTERPRETATION OF THE FINDINGS & FURTHER RECOMMENDATIONS

Given the patient history, full endocrine work up with adrenal panel (to University of Tennessee), as well as thyroid assessment is warranted if not already performed. Subxiphoid palpation is warranted to assess for any discomfort in the region of the pancreas. All in all, the abdomen appears benign and stable.





The information and recommendations provided are based on the images presented by the referring veterinarian. No evaluation can be communicated regarding pathology that was not visible in the image/video clips provided.

Thank you for this referral. If the clinical or image interpretation does not parallel your findings or if I can be of any further assistance please contact me.

Eric Lindquist, DMV, DABVP, Cert. IVUSS, CEO of SonoPath.com
info@SonoPath.com