



**PATIENT**

Molly Cole

**SPECIES**

Canine

**BREED**

Pitbull

**SEX**

Spayed Female

**AGE**

8 Years

**WEIGHT**

54 Pounds

**INTERPRETED BY**

Eric Lindquist, DMV  
DABVP, Cert. IVUSS

**IMAGING PERFORMED BY**

Heather

**HOSPITAL NAME**

ACC Flanders

**REFERRING VET**

Dr. Hallihan

**INVOICE**

22313

**DATE**

5/5/23

**PRESENTING CLINICAL SIGNS**

History: Pre-dental diagnostics had 2 tabs trazodone before dropped off

Abnormal PE/Chem/CBC/UA Results: 3/8/23 - total protein - 8.6(hi) glob - 5.1 (hi), beta 2.9 (hi)

**ULTRASONOGRAPHIC EXAMINATION OF THE ABDOMEN**

**Urinary System**

The **urinary bladder**, trigone, and pelvic urethra presented normal thicknesses and normal tone. The ureters were not visible which is normal. No uroliths or sediment were visualized and anechoic urine was present. No evidence of inflammatory or neoplastic changes were noted. Ureteral papillae were normal.

The **kidneys** revealed normal size and structure, corticomedullary definition and ratio for this age. The cortices presented largely uniform texture with normal echogenic relationship to liver and spleen. Medullary structure differed distinctly from the cortex and no evidence of pelvic dilation was present. The capsules were acceptably uniform without significant irregularities. The left kidney measured 5.87 cm. The right kidney measured 6.5 cm.

**Adrenal Glands**

The **adrenal glands** were not visualized.

**Spleen**

The **spleen** was mildly enlarged and slightly folded upon itself cranially. Subtle heterogenous parenchymal changes were noted in the spleen.

**Liver**

The **liver** images submitted revealed subjectively normal liver size, contour, and structure. Parenchymal echogenicity was naturally coarse and hypoechoic to the spleen. Vascular and biliary tracts were of normal volume with no evidence of congestion. The gallbladder presented acceptably thin walls with primarily anechoic content. The cystic and common bile ducts were normal. No pathological hepatic lymphadenopathy was evident. No overt structural evidence of inflammatory, infiltrative or regenerative pathology was evident.

**Gastrointestinal**

There was some residual chyme and gas was noted in the **stomach**, yet not pathological. This is consistent with end post prandial presentation. Transit of chyme into the small intestine was normal. Curvilinear patterns were maintained throughout the GI tract. No evidence of pathology. Small and large intestine demonstrated normal luminal chyme and stool consistency respectively. No obstructive or overt infiltrative disease was noted. No associated abnormal lymphatic activity was noted.

**Pancreas**

The base and limbs of the **pancreas** were observed to be largely isoechoic to surrounding omental fat. Pancreatic duct and capsular contour were acceptably normal and parenchyma respected normal curvilinear patterns. No overt evidence of active inflammatory or neoplastic disease was noted.

**Other**



**PATIENT**

A rapid view of the **heart** revealed no evident pathology.

Molly Cole

**ULTRASONOGRAPHIC FINDINGS**

**SPECIES**

- Slight splenic enlargement
- Partially full stomach

Canine

**INTERPRETATION OF THE FINDINGS & FURTHER RECOMMENDATIONS**

**BREED**

Given the globulin elevations, I recommend FNA when under sedation for a dental procedure. Assuming that the patient is postprandial, the material in the stomach would most fit with ingesta. No overt contraindication to anesthetic procedure.

Pitbull

**SEX**

Spayed Female

**AGE**

8 Years

**WEIGHT**

54 Pounds

**INTERPRETED BY**

Eric Lindquist, DMV  
DABVP, Cert. IVUSS

**IMAGING PERFORMED BY**

Heather

**HOSPITAL NAME**

ACC Flanders

**REFERRING VET**

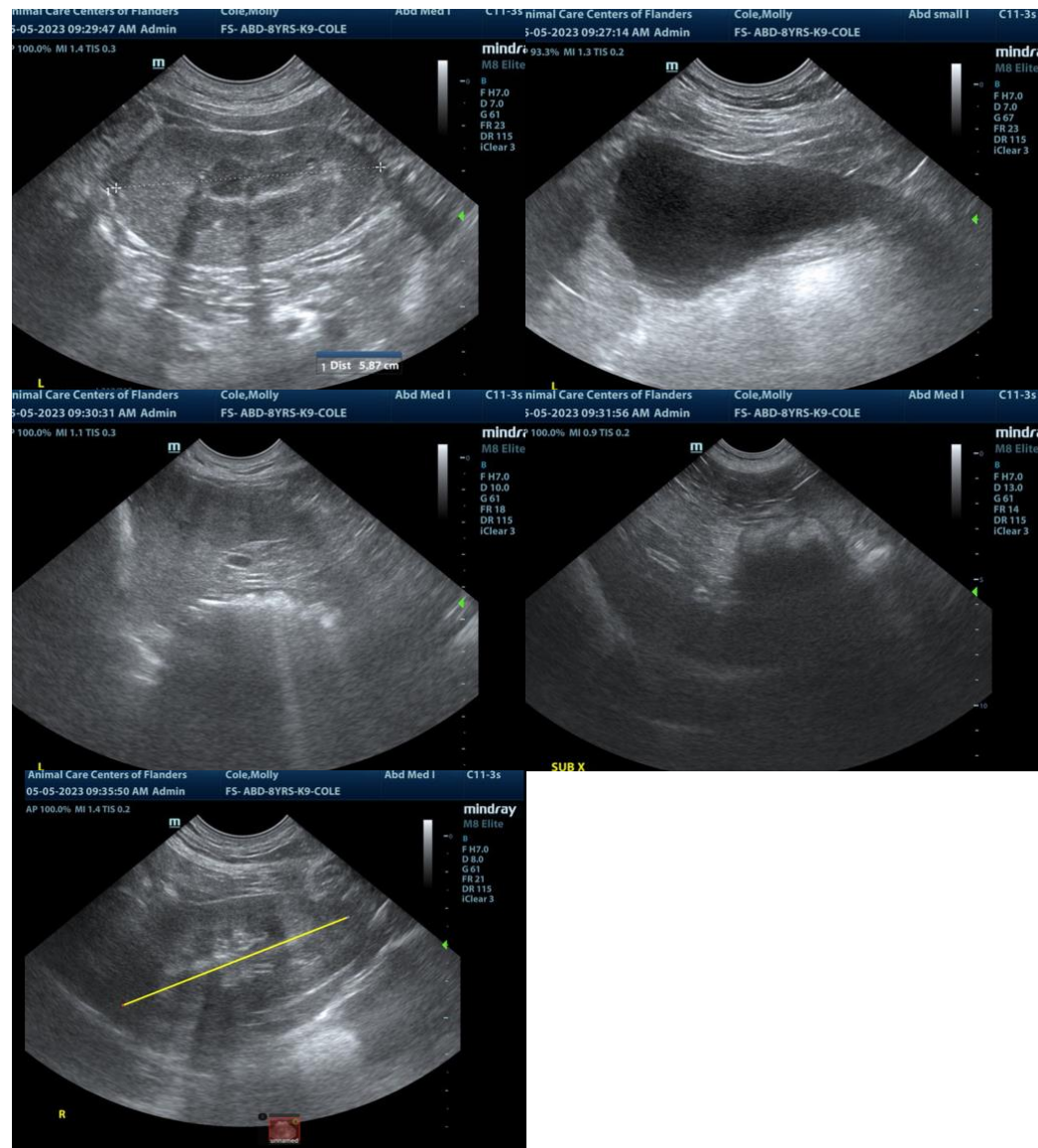
Dr. Hallihan

**INVOICE**

22313

**DATE**

5/5/23



The information and recommendations provided are based on the images presented by the referring veterinarian. No evaluation can be communicated regarding pathology that was not visible in the image/video clips provided.



**PATIENT**

Molly Cole

Thank you for this referral. If the clinical or image interpretation does not parallel your findings or if I can be of any further assistance please contact me.

**SPECIES**

Canine

**Eric Lindquist**, DMV, DABVP, Cert. IVUSS, CEO of SonoPath.com  
info@SonoPath.com

**BREED**

Pitbull

**SEX**

Spayed Female

**AGE**

8 Years

**WEIGHT**

54 Pounds

**INTERPRETED BY**

Eric Lindquist, DMV  
DABVP, Cert. IVUSS

**IMAGING  
PERFORMED BY**

Heather

**HOSPITAL NAME**

ACC Flanders

**REFERRING VET**

Dr. Hallihan

**INVOICE**

22313

**DATE**

5/5/23