



**PATIENT PRESENTING CLINICAL SIGNS**

Maddie Malino History: recheck from yesterday 4 cm gastric material and chyme dog has been NPO

**SPECIES ULTRASONOGRAPHIC EXAMINATION OF THE ABDOMEN**

Canine

**Gastrointestinal**

**BREED**

The stomach revealed persistently shadowing material in the stomach measuring 3.5 cm. Mild gastric hypertrophy was noted. The small intestine was empty.

Frenchie

**ULTRASONOGRAPHIC FINDINGS**

**SEX**

Persistent gastric foreign matter and concurrent gastric hypertrophy.

Spayed female

**AGE**

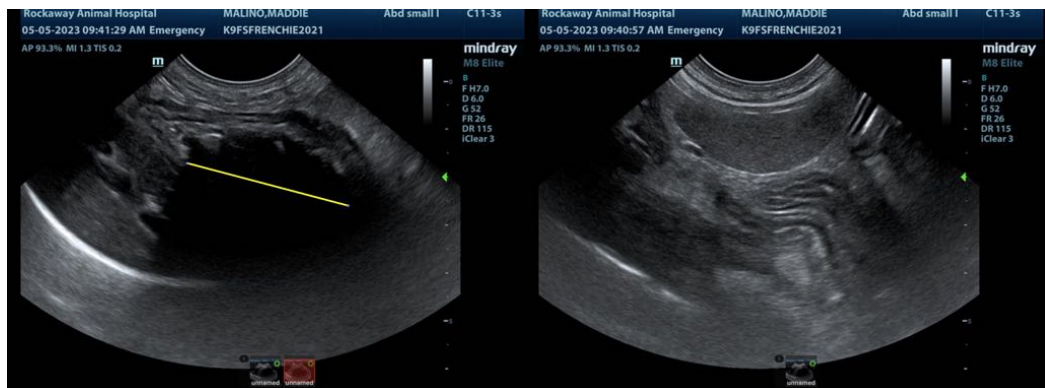
**INTERPRETATION OF THE FINDINGS & FURTHER RECOMMENDATIONS**

2 years

Gastrotomy and GI biopsies are indicated. Rubber structure or similar is suspected.

**WEIGHT**

26 lbs



**INTERPRETED BY**

Eric Lindquist, DMV  
DABVP, Cert. IVUSS

**IMAGING PERFORMED BY**

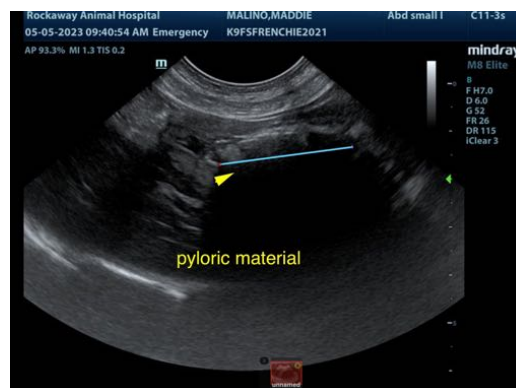
Jenn

**HOSPITAL NAME**

Rockaway AH

**REFERRING VET**

Dr. Maniar



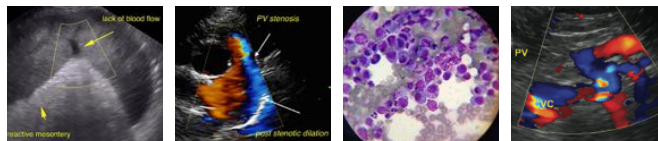
**INVOICE**

44183

**DATE**

5/5/23

The information and recommendations provided are based on the images presented by the referring veterinarian/sonographer. No evaluation can be communicated regarding pathology that was not visible in the image/video clips provided.



**PATIENT**

Maddie Malino

Thank you for this referral. If the clinical or image interpretation does not parallel your findings or if I can be of any further assistance please contact me.

**SPECIES**

Canine

**Eric Lindquist**, DMV, DABVP, Cert. IVUSS, CEO of SonoPath.com  
info@SonoPath.com

**BREED**

Frenchie

**SEX**

Spayed female

**AGE**

2 years

**WEIGHT**

26 lbs

**INTERPRETED BY**

Eric Lindquist, DMV  
DABVP, Cert. IVUSS

**IMAGING  
PERFORMED BY**

Jenn

**HOSPITAL NAME**

Rockaway AH

**REFERRING VET**

Dr. Maniar

**INVOICE**

44183

**DATE**

5/5/23