



**PATIENT PRESENTING CLINICAL SIGNS**

Elton Vega Bloody discharge/diarrhea (frank blood only). Straining

**SPECIES** Abnormal PE/Chem/CBC/UA Results: Alb: 4.1, ALk: 20, Tbili: 2.2, amy: 366

Canine

**ULTRASONOGRAPHIC EXAMINATION OF THE ABDOMEN**

**BREED** *Urinary System*

Schichon

The **urinary bladder**, trigone, and pelvic urethra presented normal thicknesses and normal tone. The ureters were not visible which is normal. No uroliths or sediment were visualized and anechoic urine was present. No evidence of inflammatory or neoplastic changes were noted. Ureteral papillae were normal.

**SEX**

Neutered Male

**AGE**

1 Year

The **kidneys** revealed normal size and structure, corticomedullary definition and ratio for this age. The cortices presented largely uniform texture with normal echogenic relationship to liver and spleen. Medullary structure differed distinctly from the cortex and no evidence of pelvic dilation was present. The capsules were acceptably uniform without significant irregularities. The left kidney measured 4.15 cm. The right kidney measures 4.15 cm.

**WEIGHT**

17 Pounds

*Adrenal Glands*

Both **adrenal glands** were visualized and recognized as having normal shape, size, position and echogenicity for this breed. The phrenic vasculature, glandular echogenicity and detail were unremarkable. Capsule, cortex, and medullary definition were normal for this age patient. The left adrenal gland measured 1.15 cm x 0.42 cm. The right adrenal gland measured 1.69 cm x 0.44 cm at the caudal pole and 0.80 cm at the cranial pole.

**INTERPRETED BY**

Eric Lindquist, DMV

DABVP, Cert. IVUSS

*Spleen*

The **spleen** presented a smooth homogeneous parenchyma hyperechoic to liver and renal cortical parenchyma. The capsule was smooth without noticeable expansion or deviation from within the spleen or adjacent pathology. The splenic vasculature demonstrated normal volume without signs of congestion or thrombosis. No sonographic evidence of acute or chronic inflammatory, neoplastic, or infarctual changes were noted.

**IMAGING PERFORMED BY**

Dr. A Rodriguez

**HOSPITAL NAME**

Foxfield Vet Services

*Liver*

The **liver** images submitted revealed subjectively normal liver size, contour, and structure. Parenchymal echogenicity was naturally coarse and hypoechoic to the spleen. Vascular and biliary tracts were of normal volume with no evidence of congestion. The gallbladder presented acceptably thin walls with primarily anechoic content. The cystic and common bile ducts were normal. No pathological hepatic lymphadenopathy was evident. No overt structural evidence of inflammatory, infiltrative or regenerative pathology was evident.

**REFERRING VET**

Dr. A Rodriguez

**INVOICE**

47153

**DATE**

5/5/23

*Gastrointestinal*

The **stomach** was unremarkable. The small intestine revealed a minor amount of entrapped chyme or small foreign matter measuring approximately 1.0 cm. The colon revealed a minor amount of chyme in the transverse colon.



**PATIENT**

**Pancreas**

Elton Vega

The base and limbs of the **pancreas** were observed to be largely isoechoic to surrounding omental fat. Pancreatic duct and capsular contour were acceptably normal and parenchyma respected normal curvilinear patterns. No overt evidence of active inflammatory or neoplastic disease was noted.

**SPECIES**

Canine

**ULTRASONOGRAPHIC FINDINGS**

**BREED**

- Transiting foreign matter or chyme entrapment
- Structurally unremarkable abdomen otherwise

Schichon

**SEX**

Recommend medical management in this patient, as this material should pass. Recheck sonogram in 24 hours after NPO status. IV fluid support and supportive care warranted. Bilirubin should be reevaluated to assess if it is persistent as opposed to pathological, as the liver appears normal.

Neutered Male

**AGE**

1 Year

**WEIGHT**

17 Pounds

**INTERPRETED BY**

Eric Lindquist, DMV  
DABVP, Cert. IVUSS

**IMAGING PERFORMED BY**

Dr. A Rodriguez

**HOSPITAL NAME**

Foxfield Vet Services

**REFERRING VET**

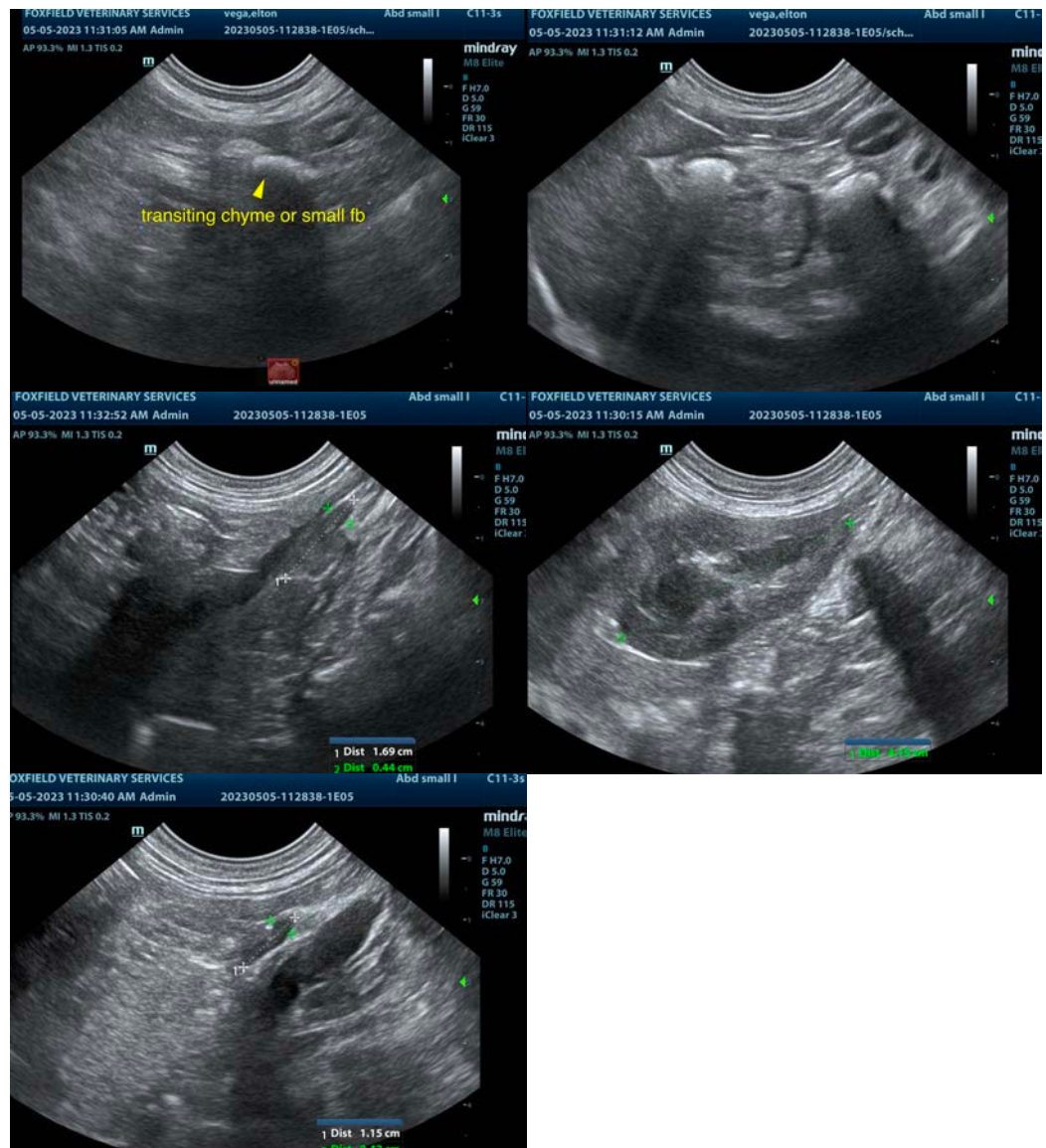
Dr. A Rodriguez

**INVOICE**

47153

**DATE**

5/5/23





**PATIENT**

Elton Vega

The information and recommendations provided are based on the images presented by the referring veterinarian/sonographer. No evaluation can be communicated regarding pathology that was not visible in the image/video clips provided.

**SPECIES**

Canine

Thank you for this referral. If the clinical or image interpretation does not parallel your findings or if I can be of any further assistance please contact me.

**BREED**

Schichon

Eric Lindquist, DMV, DABVP, Cert. IVUSS, CEO of SonoPath.com

[info@SonoPath.com](mailto:info@SonoPath.com)

**SEX**

Neutered Male

**AGE**

1 Year

**WEIGHT**

17 Pounds

**INTERPRETED BY**

Eric Lindquist, DMV

DABVP, Cert. IVUSS

**IMAGING  
PERFORMED BY**

Dr. A Rodriguez

**HOSPITAL NAME**

Foxfield Vet Services

**REFERRING VET**

Dr. A Rodriguez

**INVOICE**

47153

**DATE**

5/5/23