



**PATIENT PRESENTING CLINICAL SIGNS**

Bradley Tafuro History: Grade 2/6 murmur.

**SPECIES** Abnormal PE/Chem/CBC/UA Results: BP 172/79(128), 174/106(120), 141/91(103)

Canine

**ULTRASONOGRAPHIC EXAMINATION OF THE HEART**

| BREED          | CANINE CARDIAC PARAMETERS | MR VMAX (m/s) | TR VMAX (m/s) | LA/AO (Boon method) | LA/AO (Heart Base; Swe) | FS (%)                          | EF (%)                                   | EPSS (cm)                                |
|----------------|---------------------------|---------------|---------------|---------------------|-------------------------|---------------------------------|--|--|
| French Bulldog |                           |               |               |                     |                         |                                 |  |  |
| SEX            | NORMAL PARAMETER          | 4.5-5.5       | <2.7          | 1.3                 | <1.3                    | 28-40                           | 40-100                                   | <0.6                                     |
| Neutered Male  | PATIENT                   | --            | --            | NM                  | --                      | --                              | --                                       | NM                                       |
| AGE            | CANINE CARDIAC PARAMETERS | HR (BPM)      | AV VMAX (m/s) | PV MAX (m/s)        | BODY WEIGHT (kg)        | LA 2D short axis Base view (cm) | LVIDd Avg; 2D and m-mode short axis (cm) | LVIDs Avg; 2D and m-mode short axis (cm) |
| 12 Years       |                           |               |               |                     |                         |                                 |  |  |
| WEIGHT         | NORMAL PARAMETER          | 50-100        | 0.7-1.7       | 0.7-1.6             |                         |                                 |  |  |
| 34.3           | PATIENT                   | --            | --            |                     | --                      | --                              | --                                       | --                                       |

**INTERPRETED BY Cardiac Presentation**

Eric Lindquist, DMV  
DABVP, Cert. IVUSS

The cardiac presentation in this patient revealed a mixed hypoechoic mass, appeared to be deriving from the heart base and right auricle. The patient was volume contracted. Arrhythmogenic activity was present. Visibility was poor. Some pleural and pericardial effusion was present.

**IMAGING PERFORMED BY ULTRASONOGRAPHIC FINDINGS**

JK

- Cardiac mass with arrhythmia
- Slight pleural and pericardial effusion

**HOSPITAL NAME INTERPRETATION OF THE FINDINGS & FURTHER RECOMMENDATIONS**

Hamburg VC

Prognosis is poor.

**REFERRING VET**

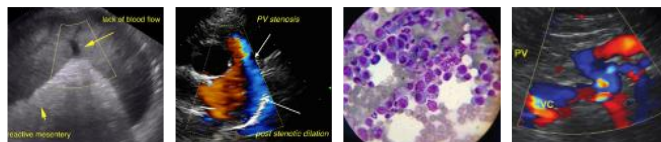
Dr. Denheyer

**INVOICE**

22314

**DATE**

5/5/23



## PATIENT

Bradley Tafuro

## SPECIES

Canine

## BREED

French Bulldog

## SEX

Neutered Male

## AGE

12 Years

## WEIGHT

34.3

## INTERPRETED BY

Eric Lindquist, DMV  
DABVP, Cert. IVUSS

## IMAGING PERFORMED BY

JK

## HOSPITAL NAME

Hamburg VC

## REFERRING VET

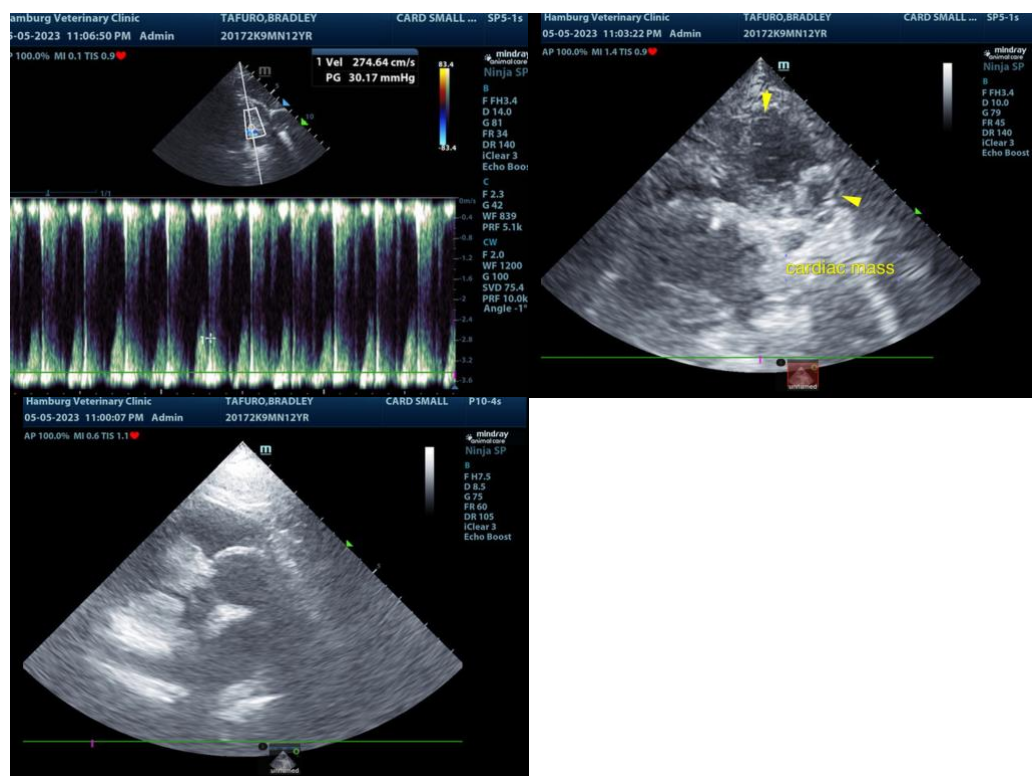
Dr. Denheyer

## INVOICE

22314

## DATE

5/5/23



The information and recommendations provided are based on the images presented by the referring veterinarian. No evaluation can be communicated regarding pathology that was not visible in the image/video clips provided.

Thank you for this referral. If the clinical or image interpretation does not parallel your findings or if I can be of any further assistance please contact me.

**Eric Lindquist**, DMV, DABVP, Cert. IVUSS, CEO of SonoPath.com  
info@SonoPath.com