



**PATIENT**

Bear Hinsch

**SPECIES**

Canine

**BREED**

Golden Retriever

**SEX**

Intact Male

**AGE**

9 Years 10 Months

**WEIGHT**

64.7 Pounds

**INTERPRETED BY**

Eric Lindquist, DMV  
DABVP, Cert. IVUSS

**IMAGING PERFORMED BY**

Dr. Katie Buss

**HOSPITAL NAME**

Kings VH

**REFERRING VET**

Dr. Katie Buss

**INVOICE**

22328

**DATE**

5/5/23

**PRESENTING CLINICAL SIGNS**

History: Bear was here today for an abdominal ultrasound and chest radiographs as a met. check after having a liposarcoma removed 11/8/22.

**ULTRASONOGRAPHIC EXAMINATION OF THE ABDOMEN**

**Urinary System**

The **urinary bladder**, trigone, and pelvic urethra presented normal thicknesses and normal tone. The ureters were not visible which is normal. No uroliths or sediment were visualized and anechoic urine was present. No evidence of inflammatory or neoplastic changes were noted. Ureteral papillae were normal.

The **prostate** was uniformly enlarged with lobar swelling appeared to impinge upon the urethra and mildly deviate the descending colon. The prostatic tissue was hyperechoic containing focal areas of decreased echogenicity. These changes are suggestive of either chronic inflammatory episodes, benign cystic pathology or both. Underlying neoplasia cannot be completely ruled-out but is lower on the differential list. This presentation is most consistent with benign prostatic hyperplasia with possible active prostatitis. Neutering or off-label Finasteride (Propecia) (0.1-0.5 mg/kg Sid) treatment is indicated +/- FNA or prostatic wash cytology and culture. This is a mild change. The prostate measured approximately 3.41 cm.

The **kidneys** revealed normal size and structure, corticomedullary definition and ratio for this age. The cortices presented largely uniform texture with normal echogenic relationship to liver and spleen. Medullary structure differed distinctly from the cortex and no evidence of pelvic dilation was present. The capsules were acceptably uniform without significant irregularities. The left kidney measured 6.0 cm. The right kidney measured 6.0 cm.

**Adrenal Glands**

The **left adrenal gland** was visualized and recognized as having normal shape, size, position and echogenicity for this breed. The phrenic vasculature, glandular echogenicity and detail were unremarkable. Capsule, cortex, and medullary definition were normal for this age patient. The left adrenal gland measured 0.52 cm.

The **right adrenal gland** was not visualized.

**Spleen**

The **spleen** was slightly heterogenous and caudal folding was noted. These are largely expected changes for this age patient.

**Liver**

The **liver** images from right and left intercostal as well as subcostal views revealed subjectively normal liver size, contour, and structure. Some minor age-related parenchymal remodeling was noted but likely not clinically significant at this time. Vascular and biliary tracts were of normal volume and no evidence of congestion was noted. The gallbladder presented some dependent debris with essentially normal contour. The cystic and common bile ducts were normal. No overt evidence of active inflammatory, infiltrative or regenerative pathology was noted but should be paired with current or



**PATIENT**

Bear Hinsch

past LE elevations regarding any clinical significance to this presentation. The hepatic lymph nodes were unremarkable.

**Gastrointestinal**

**SPECIES**

Canine

Examination of the **gastrointestinal tract** revealed a stomach and intestine free of stasis, of normal wall thickness, acceptable curvilinear mural detail, and peristaltic activity. Small and large intestine demonstrated normal luminal chyme and stool consistency respectively. No obstructive or overt infiltrative disease was noted. No associated abnormal lymphatic activity was noted.

**BREED**

Golden Retriever

**Pancreas**

**SEX**

Intact Male

The base and limbs of the **pancreas** were observed to be largely isoechoic to surrounding omental fat. Pancreatic duct and capsular contour were acceptably normal and parenchyma respected normal curvilinear patterns. No overt evidence of active inflammatory or neoplastic disease was noted.

**AGE**

9 Years 10 Months

**ULTRASONOGRAPHIC FINDINGS**

- Structurally unremarkable abdomen
- Slightly heterogenous spleen
- BPH prostate

**INTERPRETATION OF THE FINDINGS & FURTHER RECOMMENDATIONS**

No overt evidence of metastatic disease or primary disease.

**WEIGHT**

64.7 Pounds

**INTERPRETED BY**

Eric Lindquist, DMV  
DABVP, Cert. IVUSS

**IMAGING PERFORMED BY**

Dr. Katie Buss

**HOSPITAL NAME**

Kings VH

**REFERRING VET**

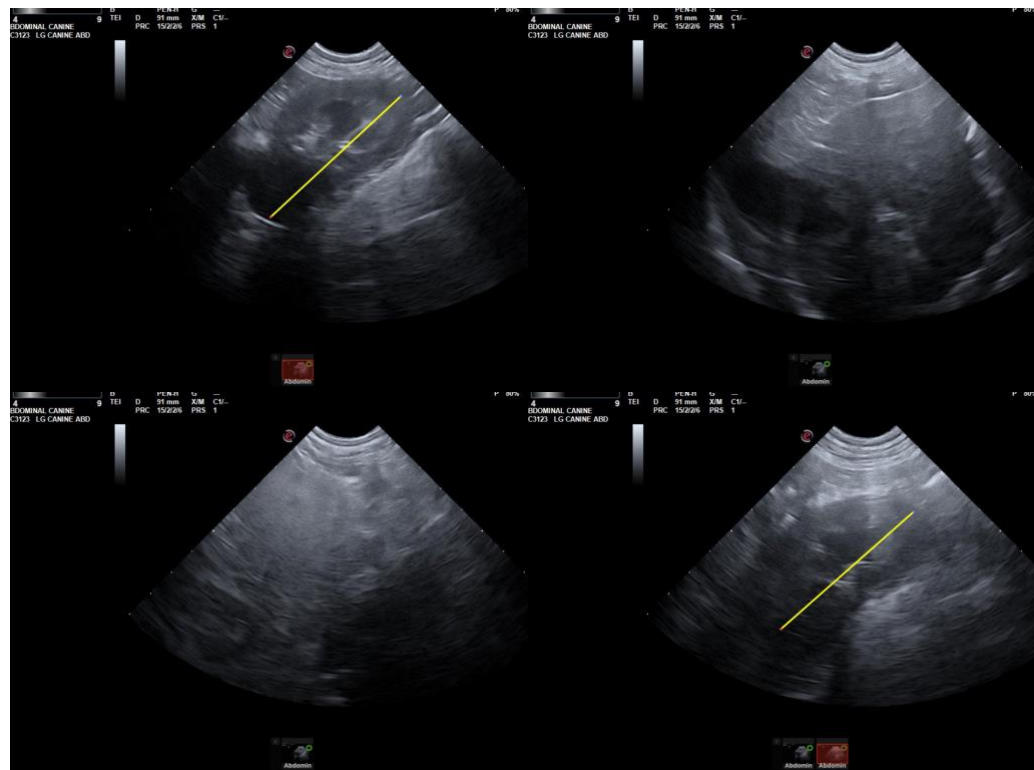
Dr. Katie Buss

**INVOICE**

22328

**DATE**

5/5/23





**PATIENT**

Bear Hinsch

**SPECIES**

Canine

**BREED**

Golden Retriever

**SEX**

Intact Male

**AGE**

9 Years 10 Months

**WEIGHT**

64.7 Pounds

**INTERPRETED BY**

Eric Lindquist, DMV  
DABVP, Cert. IVUSS

**IMAGING  
PERFORMED BY**

Dr. Katie Buss

**HOSPITAL NAME**

Kings VH

**REFERRING VET**

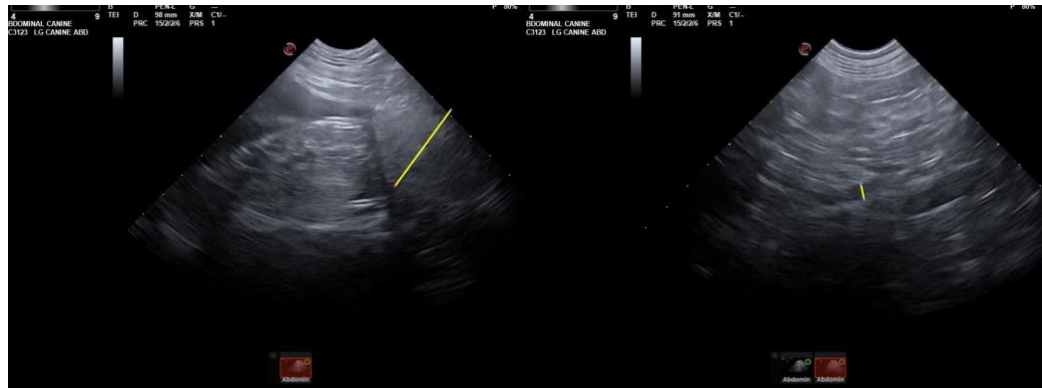
Dr. Katie Buss

**INVOICE**

22328

**DATE**

5/5/23



The information and recommendations provided are based on the images presented by the referring veterinarian. No evaluation can be communicated regarding pathology that was not visible in the image/video clips provided.

Thank you for this referral. If the clinical or image interpretation does not parallel your findings or if I can be of any further assistance please contact me.

**Eric Lindquist**, DMV, DABVP, Cert. IVUSS, CEO of SonoPath.com  
info@SonoPath.com