

**DATE**

5/5/22

PATIENT

Sasha Decapite

SPECIES

Canine

BREED

Pomeranian

SEX

Spayed Female

AGE

3/12/12

WEIGHT

15.8 Pounds

INTERPRETED BYEric Lindquist, DMV
DABVP, Cert. IVUSS**IMAGING PERFORMED BY**

Rachel Brillhart RDMS

HOSPITAL NAME

Alexander AH

REFERRING VET

Dr. Alexander

INVOICE

37428

PRESENTING CLINICAL SIGNS

Hair loss and ravenous appetite.

Current Medications: None.

Lab Results: ALT = 779, ALKP = 6640, GGT = 46, BUN = 48 Chol = 648, Trgi = 693, PSL = 306. U/A pending

Date of Previous IntraPet Ultrasound: No previous.

Sedation: Not required to complete full diagnostic ultrasound.

Stat Report: Not requested.

ULTRASONOGRAPHIC EXAMINATION OF THE ABDOMEN**Urinary System**

The **urinary bladder**, trigone, and pelvic urethra presented normal thicknesses and normal tone. The ureters were not visible which is normal. No uroliths or sediment were visualized and anechoic urine was present. No evidence of inflammatory or neoplastic changes were noted. Ureteral papillae were normal.

The **kidneys** revealed largely normal size and structure, corticomedullary definition and ratio (cortex 1/3 of medulla) were essentially maintained with some age-related loss of curvilinear patterns regarding the capsule and C/M junction. The cortices presented largely uniform texture with some increased echogenicity expected for his age patient. Medullary structure differed distinctly from that of the cortex. Mineralization noted in both kidneys. The right kidney measured 4.24 cm. The left kidney measured 4.88 cm with trace pyelectasia noted.

Adrenal Glands

The **adrenal glands** appeared slightly enlarged and swollen. No evidence of focal capsular expansion or invasion into the phrenic veins were noted. No overt suspicion of neoplasia was noted. This is considered likely a hyperplastic change associated with stress or adrenal endocrinopathy (PDH). If isosthenuria is persistently present and the patient morphologically suggests Cushing's disease then ACTH testing would be indicated. The right adrenal gland measured 2.08 cm x 1.03 cm at the cranial pole and 0.83 cm at the caudal pole. The left adrenal gland measured 2.7 cm x 0.89 cm at the caudal pole and 0.75 cm at the cranial pole.

Spleen

The **spleen** presented a smooth homogeneous parenchyma hyperechoic to liver and renal cortical parenchyma. The capsule was smooth without noticeable expansion or deviation from within the spleen or adjacent pathology. The splenic vasculature demonstrated normal volume without signs of congestion or thrombosis. No sonographic evidence of acute or chronic inflammatory, neoplastic, or infarctual changes were noted.

Liver

The **liver** was uniformly swollen with minor, excessive gallbladder debris and over distension with dependent and suspended bile without evidence of overt mucocele formation. However, excessive sludge was present. The liver presented coarse architecture with mildly increased portal markings and subtle, mixed echogenic changes. This is consistent with vacuolar hepatopathy and some level of remodeling and history of inflammatory component. There was no overt suspicion of neoplasia. Occasional hyperechoic lipogranulomatous nodules noted.

Gastrointestinal

The **stomach** itself was unremarkable. Mucosal speckling noted in the small intestine, yet not likely a clinical issue.

Pancreas

The base and limbs of the **pancreas** were observed to be largely isoechoic to surrounding omental fat. Some parenchymal remodeling, however, with mild deviation from curvilinear normalcy was observed. Pancreatic duct and capsular irregularities were present consistent with age related changes. If pain upon imaging (+ Murphy sign) was present or if the patient is focally painful in subxyphoid palpation then low-grade smoldering chronic pancreatitis should be suspected.

ULTRASONOGRAPHIC FINDINGS

- Bilateral adrenal hypertrophy – likely PDH/Cushing's
- Benign hepatopathy
- Splenic mineralization
- Geriatric abdomen

INTERPRETATION OF THE FINDINGS & FURTHER RECOMMENDATIONS

If USG is < 1.020 , workup for PDH would be indicated.

Efficient & Accurate Cushing's Work up-Lindquist

Notes regarding Cushing's Clinical Presentations:

Nearly all Cushing's dogs have SAP elevations and true PU/PD (USG < 1.025) and most are polyphagic. Cushing's dogs are > 6 years and usually > 9 years old, usually have poor skin coats, body scores $> 3/5$, and are usually sedentary animals.

Its important to remember that Cushing's dogs usually look and play the part and other diseases cause false + stress related cortisol spikes. On rare occasion a Cushing's dog will not follow the rules but this is truly an exception.

Potential Cushing's patient workups can be costly and frustrating if not definitive and, in my experience, the non-definitive patient usually has something else going on that may be contributing to some of the clinical signs a Cushing's dog will have, especially SAP elevations or PU/PD. Based on this prelude of information I came up with the following algorithm in the spirit of diagnostic efficiency.

The following suggested protocol is based on current available literature on Cushing's disease and extensive clinical-sonographic experience evaluation + Cushing's and False + LDDST & ACTH stim. cases in order to maximize the efficiency of a Cushing's workup in practice.

Screen first, workup second

1) **UA:** Repeatable (2-3 urine samples) Urine specific gravity & urine cortisol/creatinine ratio (UCCR): If **repeatable USG < 10.20 and + UCCR** move to next step 2.

Note: UA is inexpensive and easy to obtain and if UA criteria is not met for Cushing's then resources can be spent into other more pertinent diagnostics or left on hold until the UA criteria is met in emerging Cushing's cases.

2) **Sonogram:** Does the patient **have concurrent disease** clinically or sonographically as non-Cushing's illness will influence the potential false + LDDST or even ACTH stim. The sonogram gives a global perspective of the internal health of the patient to be considered in the Cushing's workup as an assessment of concurrent disease. Is there a concurrent neoplastic process, UTI pancreatitis, mucocele....? Are the adrenals enlarged (Cushing's-PDH, stress, age related or breed variant), or atrophied (iatrogenic Cushing's or adrenal burnout), have asymmetric enlargement (Adrenal tumor, hyperplasia, adenoma, age related variant), or is there vascular invasion (Invasive pheo with false + UA criteria or adenocarcinoma or phrenic thrombosis)? The sonogram answers these questions proactively.

3) **LDDST** (0.01 D-Sodium phosphate mg/kg IV) (Better screening test but plagued with false +) Use if there is potential early Cushing's or if adrenal asymmetry present on sonogram suspecting tumor. Use LDDST in cats at a higher dose (0.1 mg/kg IV).

OR

4) **ACTH stim.** (Better confirming test but can have false +) Use if the patient "looks" Cushingoid or if bilateral adrenal enlargement is present, or high normal width on sonogram, or if iatrogenic Cushing's suspected (Cortisone Tx in past).

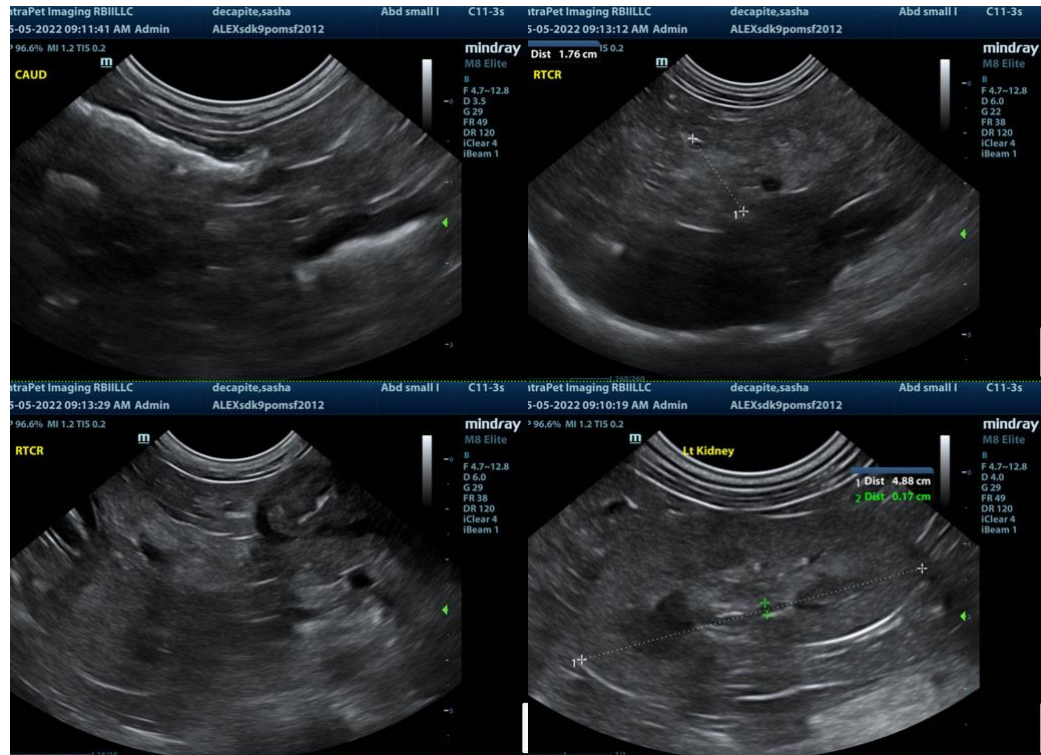
5) If **diabetic** then run both LDDST & ACTH stim.

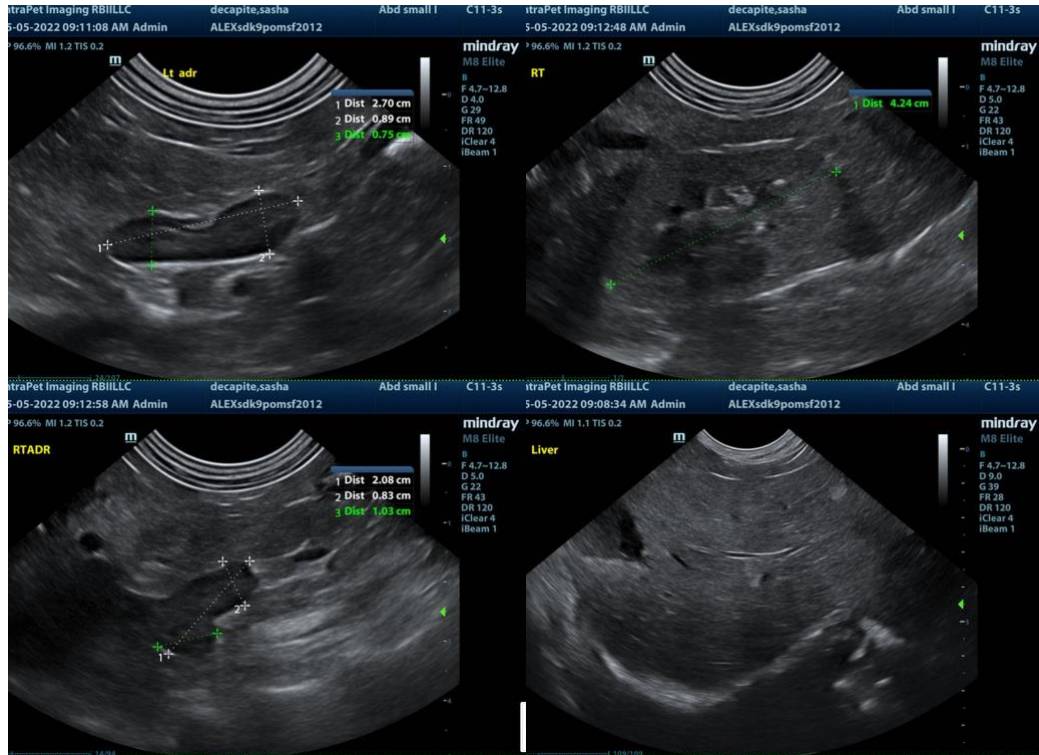
5) Run a **serial blood pressure** in a BP friendly non "white coat effect" atmosphere. Run at least 3 at different times over a few hours or when eating as the patient tends to be calm when eating or give Torbutrol when entering the facility.

6) **Perform CT** of the pituitary to identify macro adenoma expansion if any lethargy or dullness or other central clinical CNS signs are minimally present.

Suggested reading:

Behrend EN, Kooistra HS, Nelson R, et al. Diagnosis of Spontaneous Canine Hyperadrenocorticism: 2012 ACVIM Consensus Statement (Small Animal). J Vet Intern Med 2013;27:1292–1304 .





The information and recommendations provided are based on the images presented by the referring veterinarian/sonographer. No evaluation can be communicated regarding pathology that was not visible in the image/video clips provided.

Thank you for this referral. If the clinical or image interpretation does not parallel your findings or if I can be of any further assistance please contact me.

Eric Lindquist, DMV, DABVP, Cert. IVUSS, CEO of SonoPath.com
info@SonoPath.com