



PATIENT

Rob Roy Sinatra

PRESENTING CLINICAL SIGNS

History: on and off app, for 3 days- vomited initially and will respond to cerenia fluids and famotidine but then in about 24 hours regresses and won't eat
Abnormal PE/Chem/CBC/UA Results: CBC/CHem/ SPec WNL

SPECIES

Canine

ULTRASONOGRAPHIC EXAMINATION OF THE ABDOMEN

Urinary System

BREED

Yorkie

The **urinary bladder**, trigone, and pelvic urethra presented normal thicknesses and normal tone. The pelvic urethra was imaged 1.0 cm beyond the cystourethral junction. The ureters were not visible which is normal. No uroliths or sediment were visualized and anechoic urine was present. No evidence of inflammatory or neoplastic changes was noted. Ureteral papillae were normal.

SEX

Neutered male

AGE

5 years

The **kidneys** revealed normal size and structure, corticomedullary definition and ratio for this age. The cortices presented largely uniform texture with normal echogenic relationship to liver and spleen. Medullary structure differed distinctly from the cortex and no evidence of pelvic dilation was present. The capsules were acceptably uniform without significant irregularities. The right kidney measured 4.0 cm.

WEIGHT

14 lbs

Adrenal Glands

The left **adrenal gland** was visualized and recognized as having normal shape, size, position and echogenicity for this breed. The phrenic vasculature, glandular echogenicity and detail were unremarkable. Capsule, cortex, and medullary definition were normal for this age patient. The left adrenal gland measured 0.5 cm. The right adrenal gland was not visualized.

INTERPRETED BY

Eric Lindquist, DMV
DABVP, Cert. IVUSS

IMAGING PERFORMED BY

Dr. Scott

Spleen

The **spleen** presented a smooth homogeneous parenchyma hyperechoic to liver and renal cortical parenchyma. The capsule was smooth without noticeable expansion or deviation from within the spleen or adjacent pathology. The splenic vasculature demonstrated normal volume without signs of congestion or thrombosis. No sonographic evidence of acute or chronic inflammatory, neoplastic, or infarctual changes was noted.

HOSPITAL NAME

HoHoKus VH

REFERRING VET

Dr. Scott

Liver

The **liver** images submitted revealed subjectively normal liver size, contour, and structure. Parenchymal echogenicity was naturally coarse and hypoechoic to the spleen. Vascular and biliary tracts were of normal volume with no evidence of congestion. The gallbladder presented acceptably thin walls with primarily anechoic content. The cystic and common bile ducts were normal. No pathological hepatic lymphadenopathy was evident. No overt structural evidence of inflammatory, infiltrative or regenerative pathology was evident.

INVOICE

30180

DATE

5/5/22



PATIENT

Rob Roy Sinatra

Gastrointestinal

The **gastrointestinal tract** revealed an edematous wall and hyperperistalsis with no loss of mural detail. Minor enhanced surrounding fat was noted around the regions of the gastrointestinal serosa. There was no evidence of foreign body or neoplastic criteria. Images from the stomach, small intestine and colon were presented. This is most consistent with gastroenteritis owing to viral, bacterial/endotoxin or possible parasitic disease.

SPECIES

Canine

BREED

Yorkie

Pancreas

The **pancreas** revealed heterogenous parenchymal changes at the right base.

SEX

Neutered male

ULTRASONOGRAPHIC FINDINGS

AGE

5 years

Gastroenteritis.

Minor pancreatitis.

WEIGHT

14 lbs

INTERPRETATION OF THE FINDINGS & FURTHER RECOMMENDATIONS

24 hour n.p.o. with IV fluid support and GI protectants are all indicated.

INTERPRETED BY

Eric Lindquist, DMV
DABVP, Cert. IVUSS

IMAGING PERFORMED BY

Dr. Scott

HOSPITAL NAME

HoHoKus VH

REFERRING VET

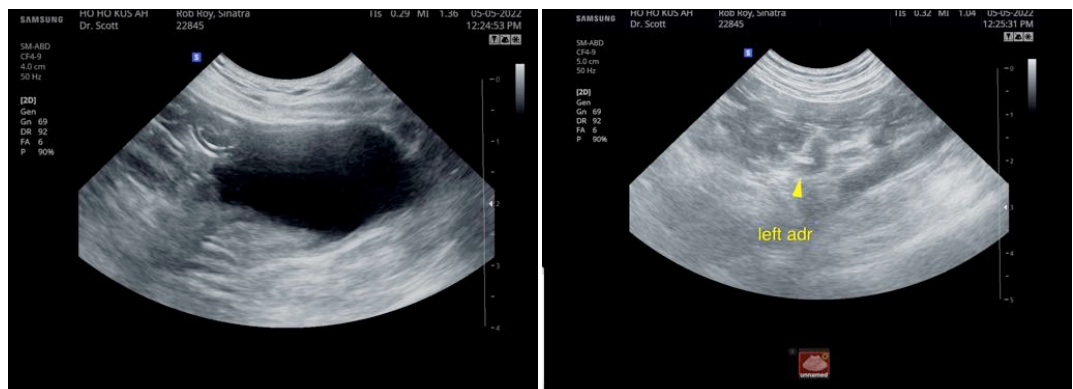
Dr. Scott

INVOICE

30180

DATE

5/5/22





PATIENT

Rob Roy Sinatra

SPECIES

Canine

BREED

Yorkie

SEX

Neutered male

AGE

5 years

WEIGHT

14 lbs

INTERPRETED BY

Eric Lindquist, DMV
DABVP, Cert. IVUSS

IMAGING PERFORMED BY

Dr. Scott

HOSPITAL NAME

HoHoKus VH

REFERRING VET

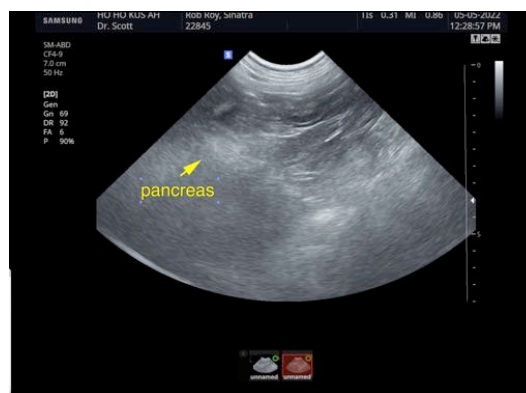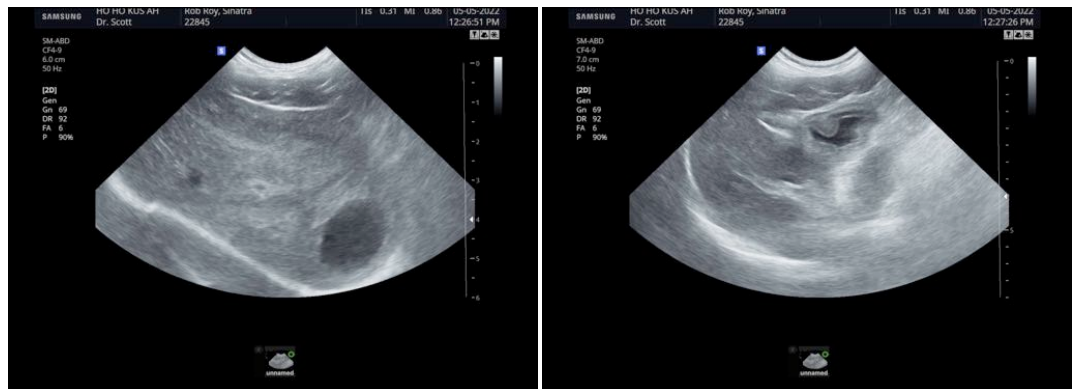
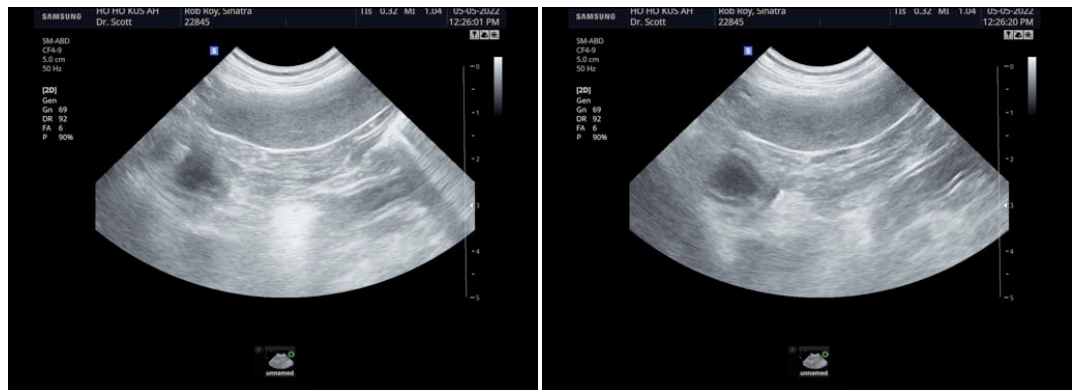
Dr. Scott

INVOICE

30180

DATE

5/5/22



The information and recommendations provided are based on the images presented by the referring veterinarian/sonographer. No evaluation can be communicated regarding pathology that was not visible in the image/video clips provided.

Thank you for this referral. If the clinical or image interpretation does not parallel your findings or if I can be of any further assistance please contact me.

Eric Lindquist, DMV, DABVP, Cert. IVUSS, CEO of SonoPath.com



PATIENT

info@SonoPath.com

Rob Roy Sinatra

SPECIES

Canine

BREED

Yorkie

SEX

Neutered male

AGE

5 years

WEIGHT

14 lbs

INTERPRETED BY

Eric Lindquist, DMV
DABVP, Cert. IVUSS

**IMAGING
PERFORMED BY**

Dr. Scott

HOSPITAL NAME

HoHoKus VH

REFERRING VET

Dr. Scott

INVOICE

30180

DATE

5/5/22