



PATIENT

Olie Pence

SPECIES

Canine

BREED

Miniature Schnauzer

SEX

Neutered male

AGE

11 years

WEIGHT

10.7 kg

PRESENTING CLINICAL SIGNS

Recheck echocardiogram based off of recommendations from last echo report from Inland Empire Veterinary Imaging on 04/2021 prior to anesthesia for dentistry. Blood pressure and Echo performed shortly after sedation with Butorphanol 10 mg/mL 0.25 mL IV. Labs for blood currently pending. Abnormal PE/Chem/CBC/UA Results: Heart murmur 4/6, patient is non-clinical. Blood pressure 144/100 (112).

ULTRASONOGRAPHIC EXAMINATION OF THE HEART

The echocardiogram in this patient demonstrated normal **left atrial** size based on 3 different LA measurement methods. Chamber volumes and echogenicity were normal. Trivial **mitral** insufficiency noted in this patient, not clinically significant. The **left ventricle** presented thicknesses with linear contour and was not dilated nor restricted. The **myocardium** presented normal echogenicity without subjective evidence of significant fibrotic or ischemic disease. **Contractility** of the ventricular walls was adequate and in normal range for this patient evidenced by the fractional shortening measurement and subjective evaluation of the different regions of the myocardium. The **left ventricular outflow** tract demonstrated normal laminar flow and subjective structural integrity. The **right atrium** and auricle revealed normal size, structure and content. No evidence of masses was noted or chamber overload. **Tricuspid** valvular assessment demonstrated adequate linear morphology. The **right ventricle** was of normal size (1/3 diameter of LV), chordae structure, myocardial echogenicity and thickness. **Pulmonic** tract assessment revealed normal valve structure, laminar flow, and diameter (approx.1:1 pa/ao ratio). No visible **pericardial** or free pleura fluid was noted. No echographically detectable evidence of infiltrative disease was visible. The cranial **mediastinum** and **pericardial** regions were free of masses in the visible window. Periodic arrhythmia noted during the exam. Baseline EKG indicated. Hepatic veins were not dilated.

INTERPRETED BY

Eric Lindquist, DMV
DABVP, Cert. IVUSS

IMAGING PERFORMED BY

Dr. Stegemoller

HOSPITAL NAME

North Idaho AH

REFERRING VET

Dr. Mehra

CANINE CARDIAC PARAMETERS	MR VMAX (m/s)	TR VMAX (m/s)	LA/AO (Boon method)	LA/AO (Heart Base; Swe)	FS (%)	EF (%)	EPSS (cm)
NORMAL PARAMETER	4.5-5.5	<2.7	1.3	<1.3	28-40	40-100	<0.6
PATIENT			1.3	1.2			0.2
CANINE CARDIAC PARAMETERS	HR (BPM)	AV VMAX (m/s)	PV MAX (m/s)	BODY WEIGHT (kg)	LA 2D short axis Base view (cm)	LVIDd Avg; 2D and m-mode short axis (cm)	LVIDs Avg; 2D and m-mode short axis (cm)
NORMAL PARAMETER	50-100	0.7-1.7	0.7-1.6				
PATIENT		2.0	0.9		2.7		

INVOICE

37444

DATE

5/5/22

ULTRASONOGRAPHIC FINDINGS

- Trivial mitral insufficiency
- Periodic arrhythmia - EKG indicated.



PATIENT

Olie Pence

SPECIES

Canine

BREED

Miniature Schnauzer

SEX

Neutered male

AGE

11 years

WEIGHT

10.7 kg

INTERPRETED BY

Eric Lindquist, DMV
DABVP, Cert. IVUSS

IMAGING PERFORMED BY

Dr. Stegemoller

HOSPITAL NAME

North Idaho AH

REFERRING VET

Dr. Mehra

INVOICE

37444

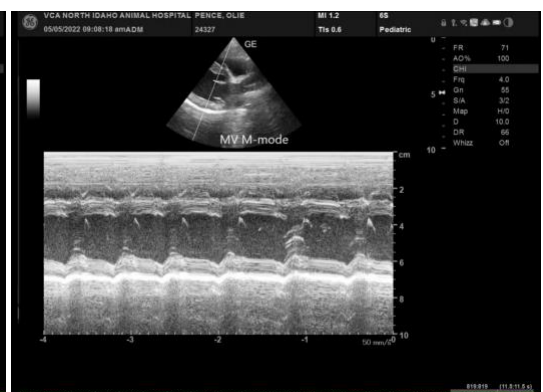
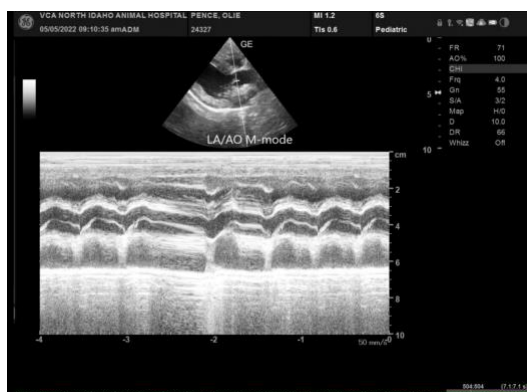
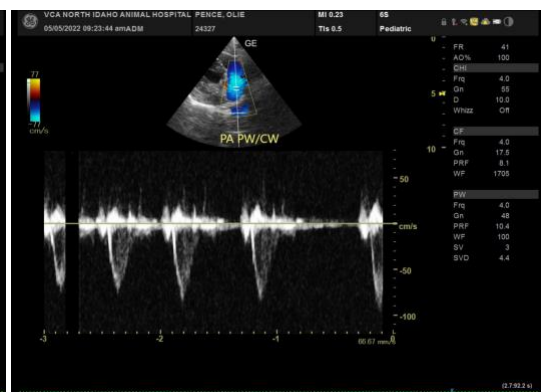
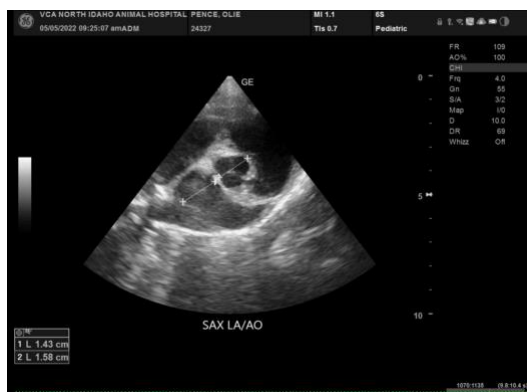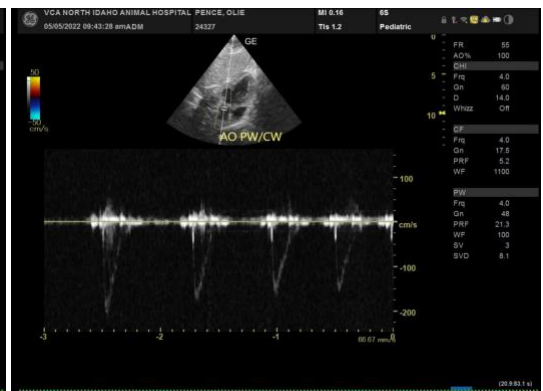
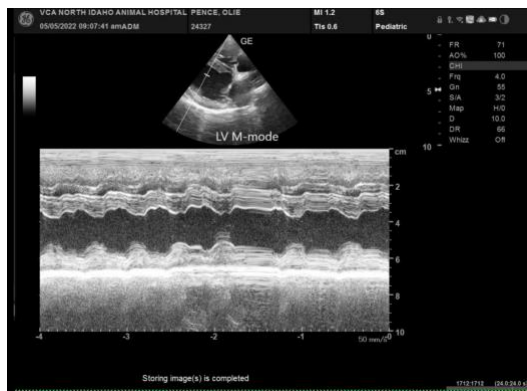
DATE

5/5/22

INTERPRETATION OF THE FINDINGS & FURTHER RECOMMENDATIONS

No progression from the prior echocardiogram. The mitral doppler may be underestimated. However, no evidence of volume overload or functional cardiac disease present. No contraindication to anesthetic procedure, if necessary.

The heart is stable without clinical disease. No overt contraindication for anesthesia of brief to moderate duration. I suggest Torbutrol premed, Propofol induction, Isoflurane maintenance or similar protocol if anesthesia is desired. Blood pressure recommended if not already performed and target white coat negative systolic pressure of < 160 mmHg. If higher than this ACE-inhibitor is suggested to reach this level. Recheck echocardiogram is recommended in 6 months, earlier if murmur grade increases or clinical signs initiate.





PATIENT

Olie Pence

SPECIES

Canine

BREED

Miniature Schnauzer

SEX

Neutered male

AGE

11 years

WEIGHT

10.7 kg

INTERPRETED BY

Eric Lindquist, DMV
DABVP, Cert. IVUSS

**IMAGING
PERFORMED BY**

Dr. Stegemoller

HOSPITAL NAME

North Idaho AH

REFERRING VET

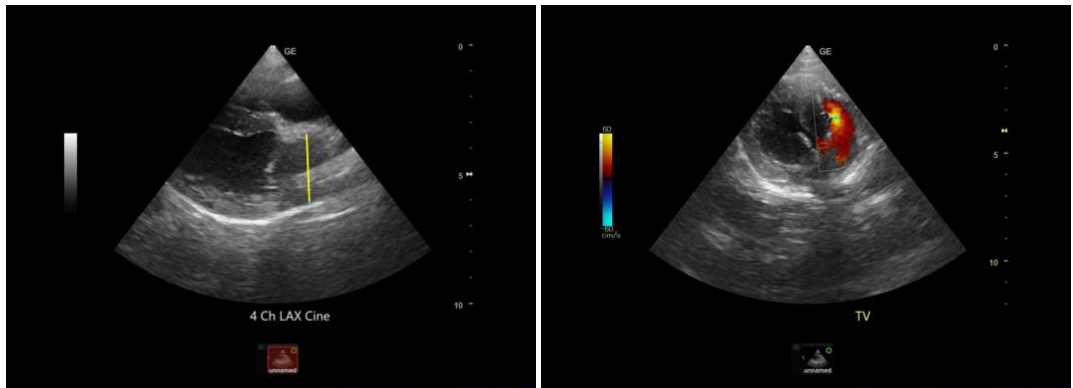
Dr. Mehra

INVOICE

37444

DATE

5/5/22



The information and recommendations provided are based on the images presented by the referring veterinarian/sonographer. No evaluation can be communicated regarding pathology that was not visible in the image/video clips provided.

Thank you for this referral. If the clinical or image interpretation does not parallel your findings or if I can be of any further assistance please contact me.

Eric Lindquist, DMV, DABVP, Cert. IVUSS, CEO of SonoPath.com
info@SonoPath.com