

**DATE**

5/5/22

PATIENT

Harley Lawson

SPECIES

Canine

BREED

Pug X

SEX**AGE**

8/12/07

WEIGHT

34 Pounds

INTERPRETED BYEric Lindquist, DMV
DABVP, Cert. IVUSS**IMAGING PERFORMED BY**

Rachel Brillhart RDMS

HOSPITAL NAME

Bay Country VH

REFERRING VET

Dr. Smith

INVOICE

37429

PRESENTING CLINICAL SIGNS

Owner reports persistent PU/PD with inappropriate urination.

Current Medications: Trilostane and Gabapentin.

Lab Results: USG 1.004, normal ACTH stim and urine culture. BUN 8, ALP 840

Date of Previous IntraPet Ultrasound: No previous.

Sedation: Not required to complete full diagnostic ultrasound.

Stat Report: Not requested.

ULTRASONOGRAPHIC EXAMINATION OF THE ABDOMEN**Urinary System**

The **urinary bladder**, trigone, and pelvic urethra presented normal thicknesses and normal tone. The ureters were not visible which is normal. No uroliths or sediment were visualized and anechoic urine was present.

No evidence of inflammatory or neoplastic changes were noted. Ureteral papillae were normal.

The **kidneys** revealed largely normal size and structure, corticomedullary definition and ratio (cortex 1/3 of medulla) were essentially maintained with some age-related loss of curvilinear patterns regarding the capsule and C/M junction. The cortices presented largely uniform texture with some increased echogenicity expected for his age patient. Medullary structure differed distinctly from that of the cortex and no evidence of pelvic dilation was present. Mineralization noted in both kidneys. The left kidney measured 5.74 cm. The right kidney measured 5.74 cm.

Adrenal Glands

The **adrenal glands** appeared slightly enlarged and swollen. No evidence of focal capsular expansion or invasion into the phrenic veins were noted. No overt suspicion of neoplasia was noted. This is considered likely a hyperplastic change associated with stress or adrenal endocrinopathy (PDH). If isosthenuria is persistently present and the patient morphologically suggests Cushing's disease then ACTH testing would be indicated. The right adrenal gland measured 2.43 cm x 1.38 cm at the cranial pole and 0.72 cm at the caudal pole. The left adrenal gland measured 2.13 cm x 0.94 cm at the caudal pole and 0.93 cm at the cranial pole.

Spleen

The **spleen** revealed an expansive 2.32 cm x 1.28 cm hypoechoic mass with capsular expansion. Generalized splenic enlargement noted with scalloping contour.

Liver

The **liver** was uniformly swollen with minor, excessive gallbladder debris and over distension with dependent and suspended bile without evidence of overt mucocele formation. However, excessive sludge was present. The liver presented coarse architecture with mildly increased portal markings and subtle, mixed echogenic changes. This is consistent with vacuolar hepatopathy and some level of remodeling and history of inflammatory component. There was no overt suspicion of neoplasia. Polypoid changes noted in the gallbladder as well.

Gastrointestinal

Examination of the **gastrointestinal tract** revealed a stomach and intestine free of stasis, of normal wall thickness, acceptable curvilinear mural detail, and peristaltic activity. Small and large intestine demonstrated normal luminal chyme and stool consistency respectively. No obstructive or overt infiltrative disease was noted. No associated abnormal lymphatic activity was noted.

Pancreas

The base and limbs of the **pancreas** were observed to be largely isoechoic to surrounding omental fat. Some parenchymal remodeling, however, with mild deviation from curvilinear normalcy was observed. Pancreatic duct and capsular irregularities were present consistent with age related changes. If pain upon imaging (+ Murphy sign) was present or if the patient is focally painful in subxyphoid palpation then low-grade smoldering chronic pancreatitis should be suspected.

Other

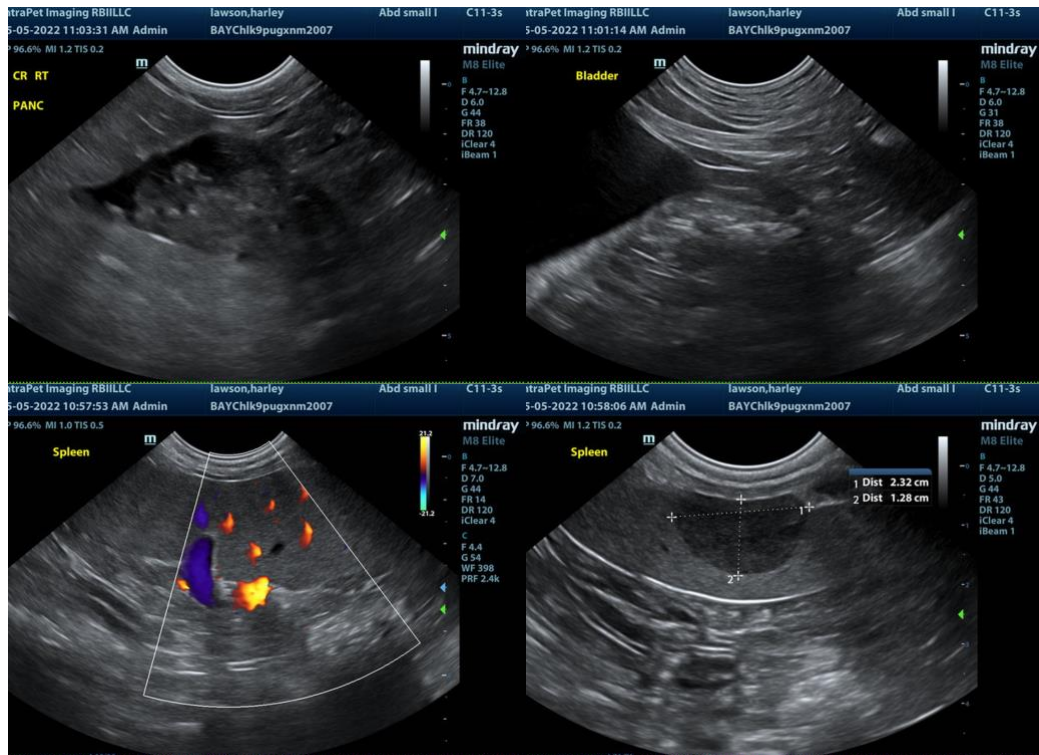
Rapid view of the heart revealed no evident pathology in the right auricle.

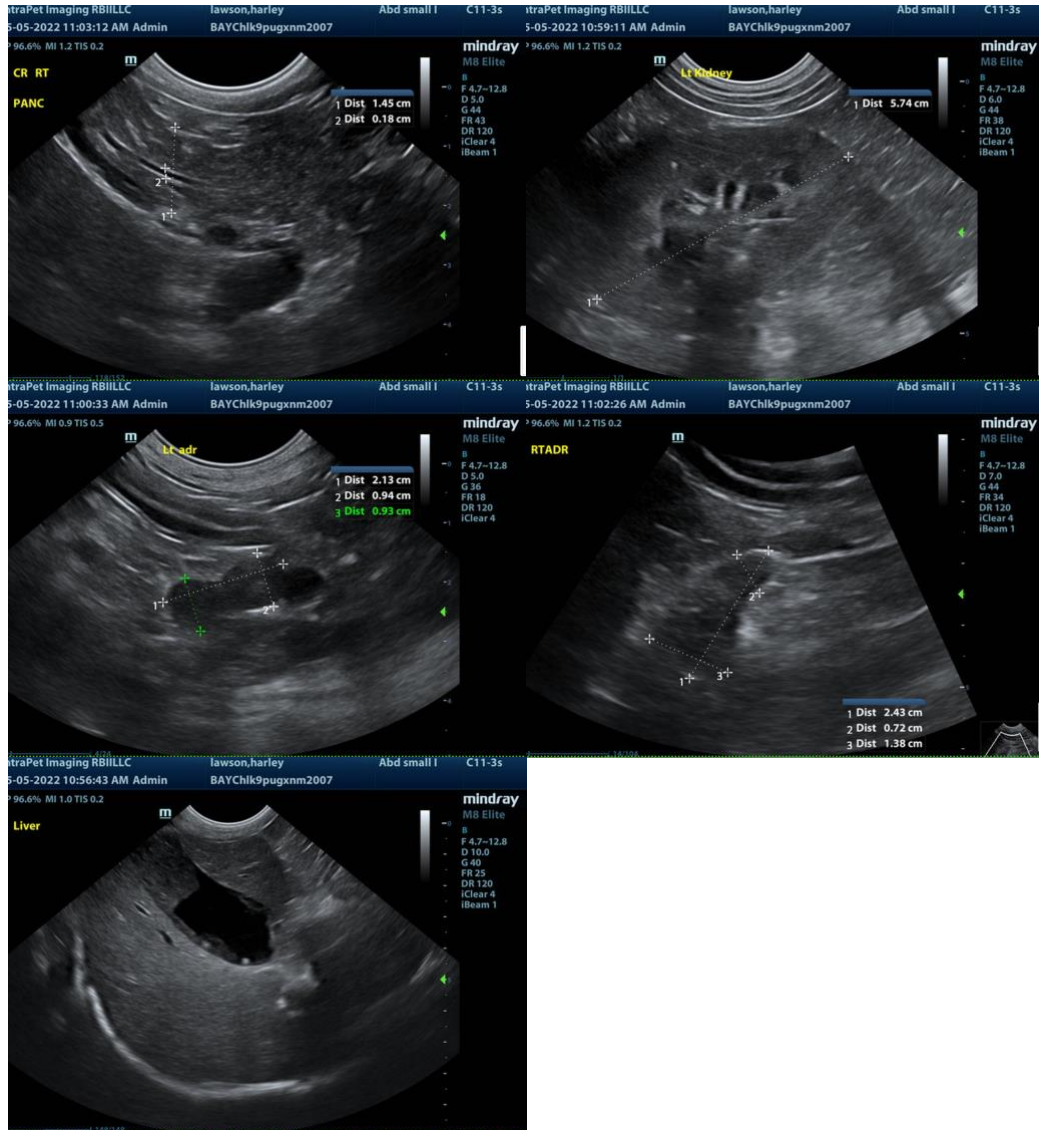
ULTRASONOGRAPHIC FINDINGS

- Bilateral adrenal hypertrophy – consistent with PDH on Trilostane.
- Pancreatic remodeling
- Benign hepatopathy and excessive gallbladder debris
- Splenic mass/nodule with mild generalized enlargement

INTERPRETATION OF THE FINDINGS & FURTHER RECOMMENDATIONS

Reassessment of the ACTH stimulation warranted to assess for dysregulation. Other potential for PU/PD could be UTI and concurrent DI. However, recommend focusing on the potential dysregulation of pituitary dependent hyperadrenocorticism. Ursodiol therapy warranted to help evacuate the gallbladder. Splenectomy could be justified or ultrasound guided FNA of the splenic nodule/mass and monitoring for 3-4 weeks for any growth. Round cell neoplasia, hemangiosarcoma, pronounced hyperplasia all possible.





The information and recommendations provided are based on the images presented by the referring veterinarian/sonographer. No evaluation can be communicated regarding pathology that was not visible in the image/video clips provided.

Thank you for this referral. If the clinical or image interpretation does not parallel your findings or if I can be of any further assistance please contact me.

Eric Lindquist, DMV, DABVP, Cert. IVUSS, CEO of SonoPath.com
info@SonoPath.com