



## PATIENT

Peaches Hernandez

## SPECIES

Canine

## BREED

Yorkie

## SEX

Male

## AGE

15 years

## WEIGHT

6.4 lbs

## INTERPRETED BY

Eric Lindquist, DMV  
DABVP, Cert. IVUSS

## IMAGING PERFORMED BY

Dr. Salas

## HOSPITAL NAME

Tenafly VC

## REFERRING VET

Dr. Salas

## INVOICE

75161

## DATE

5/4/26

## PRESENTING CLINICAL SIGNS

History: Liver/gb sonogram done due to sludge seen on AFAST during ER visit for CHF. Today we performed echo and liver/gb u/s.

## ULTRASONOGRAPHIC EXAMINATION OF THE ABDOMEN

The **liver** images from right and left intercostal as well as subcostal views revealed subjectively normal liver size, contour, and structure. Some age-related parenchymal remodeling was noted but likely not clinically significant at this time. Vascular and biliary tracts were of normal volume and no evidence of congestion was noted. The gallbladder was mildly overdistended with some striating bile and dependent debris.

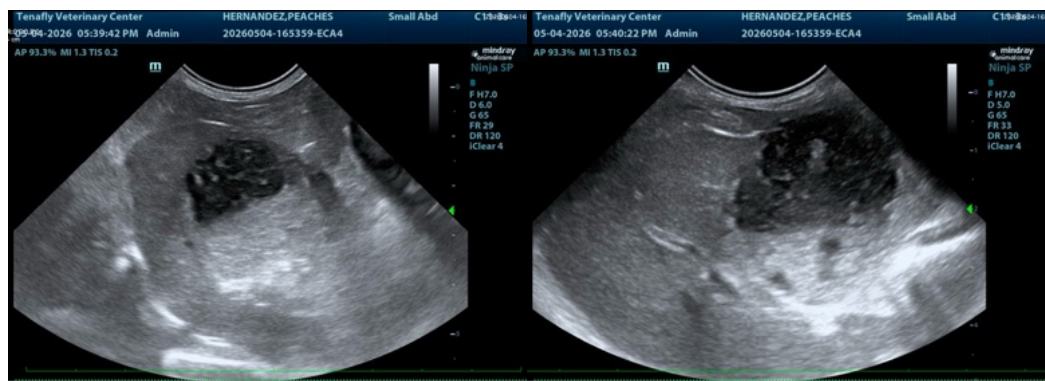
## ULTRASONOGRAPHIC FINDINGS

Emerging gallbladder mucocele.

Age related hepatic changes.

## INTERPRETATION OF THE FINDINGS & FURTHER RECOMMENDATIONS

Ursodiol therapy is warranted. Gallbladder motility study is recommended.





## PATIENT

Peaches Hernandez

## SPECIES

Canine

## BREED

Yorkie

## SEX

Male

## AGE

15 years

## WEIGHT

6.4 lbs

## INTERPRETED BY

Eric Lindquist, DMV  
DABVP, Cert. IVUSS

## IMAGING PERFORMED BY

Dr. Salas

## HOSPITAL NAME

Tenafly VC

## REFERRING VET

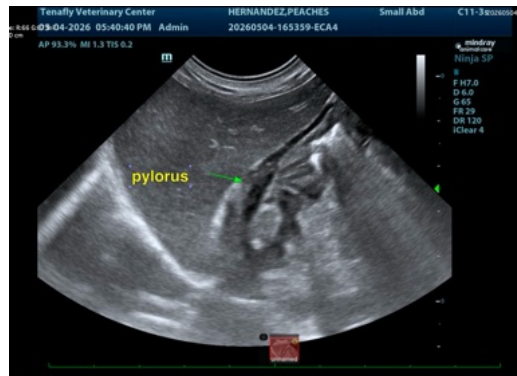Dr. Salas

## INVOICE

75161

## DATE

5/4/26



The information and recommendations provided are based on the images presented by the referring veterinarian/sonographer. No evaluation can be communicated regarding pathology that was not visible in the image/video clips provided.

Thank you for this referral. If the clinical or image interpretation does not parallel your findings or if I can be of any further assistance please contact me.

Eric Lindquist, DMV, DABVP (CFM), Cert. IVUSS, CEO of SonoPath.com

[info@SonoPath.com](mailto:info@SonoPath.com)