



**PATIENT**

Glee Chambless

**SPECIES**

Canine

**BREED**

French Bulldog

**SEX**

Spayed female

**AGE**

10 years

**WEIGHT**

20 lbs

**INTERPRETED BY**

Eric Lindquist, DMV  
DABVP, Cert. IVUSS

**IMAGING  
PERFORMED BY**

Dr. Favis

**HOSPITAL NAME**

Ruidoso Animal Clinic

**REFERRING VET**

Dr. Favis

**INVOICE**

44168

**DATE**

5/4/23

**PRESENTING CLINICAL SIGNS**

History: No clinical signs at all, hypoalbuminemia noted on routine BW  
Abnormal PE/Chem/CBC/UA Results: PE wnl, CBC - NSF; Chemistry - albumin 2.3, USG - 1.032, no proteinuria noted

**ULTRASONOGRAPHIC EXAMINATION OF THE ABDOMEN**

**Urinary System**

The **urinary bladder**, trigone, and pelvic urethra presented normal thicknesses and normal tone. The ureters were not visible which is normal. No uroliths or sediment were visualized and anechoic urine was present. No evidence of inflammatory or neoplastic changes was noted. Ureteral papillae were normal.

The **kidneys** revealed largely normal size and structure, corticomedullary definition and ratio (cortex 1/3 of medulla) were essentially maintained with some age-related loss of curvilinear patterns regarding the capsule and C/M junction. The cortices presented largely uniform texture with some increased echogenicity expected for his age patient. Medullary structure differed distinctly from that of the cortex and no evidence of pelvic dilation was present. The left kidney measured 4.5 cm. The right kidney measured 5.0 cm.

**Adrenal Glands**

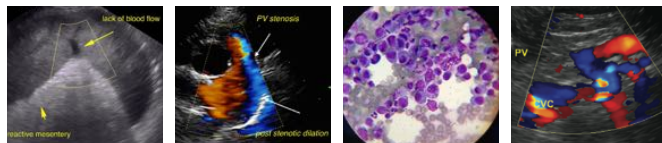
Both **adrenal glands** were visualized and recognized as having normal shape, size, position and echogenicity for this breed. The phrenic vasculature, glandular echogenicity and detail were unremarkable. Capsule, cortex, and medullary definition were normal for this age patient. The left adrenal gland measured 0.5 cm at the caudal pole and 0.35 cm at the cranial pole. The right adrenal gland measured 0.74 cm.

**Spleen**

The **spleen** presented a smooth homogeneous parenchyma hyperechoic to liver and renal cortical parenchyma. The capsule was smooth without noticeable expansion or deviation from within the spleen or adjacent pathology. The splenic vasculature demonstrated normal volume without signs of congestion or thrombosis. No sonographic evidence of acute or chronic inflammatory, neoplastic, or infarctual changes was noted.

**Liver**

The **liver** images submitted revealed subjectively normal liver size, contour, and structure. Parenchymal echogenicity was naturally coarse and hypoechoic to the spleen. Vascular and biliary tracts were of normal volume with no evidence of congestion. The gallbladder presented acceptably thin walls with primarily anechoic content. The cystic and common bile ducts were normal. No pathological hepatic lymphadenopathy was evident. No overt structural evidence of inflammatory, infiltrative or regenerative pathology was evident.



**PATIENT**

Glee Chambless

**SPECIES**

Canine

**BREED**

French Bulldog

**SEX**

Spayed female

**AGE**

10 years

**WEIGHT**

20 lbs

**INTERPRETED BY**

Eric Lindquist, DMV  
DABVP, Cert. IVUSS

**IMAGING PERFORMED BY**

Dr. Favis

**HOSPITAL NAME**

Ruidoso Animal Clinic

**REFERRING VET**

Dr. Favis

**INVOICE**

44168

**DATE**

5/4/23

**Gastrointestinal**

The **gastrointestinal tract** revealed diffuse, hyperechoic fogging or overlay throughout the small intestine as well as areas of mucosal striations and speckling. This striation + fogging effect appeared to exclusively affect the mucosal layer with the submucosa, muscularis and serosa left in-tact. Reactive mesentery was present associated with the serosa indicative of active inflammation. This is most consistent with protein losing enteropathy/lymphangectasia. Full thickness biopsies or endoscopy guided biopsies would be ideal to confirm. No obstructive disease or obvious suspicion of neoplasia.

**Pancreas**

The base and limbs of the **pancreas** were observed to be largely isoechoic to surrounding omental fat. Pancreatic duct and capsular contour were acceptably normal and parenchyma respected normal curvilinear patterns. No overt evidence of active inflammatory or neoplastic disease was noted.

**Free Abdomen**

Trace amounts of free fluid were noted.

**ULTRASONOGRAPHIC FINDINGS**

Diffuse mucosal fogging/lymphangectasia pattern.

Free fluid.

**INTERPRETATION OF THE FINDINGS & FURTHER RECOMMENDATIONS**

Presuming no significant proteinuria is present, then treatment for protein losing enteropathy is indicated. If the albumin has dropped to less than 1.5 at the time of the sonogram even though reported to be 2.3, then a more acute protein losing enteropathy is likely. Otherwise, I cannot completely rule out an underlying neoplastic event that may be causing secondary free fluid. Empirical treatment for PLE is recommended such as the following. Recheck sonogram is recommended in 10-14 days or earlier if clinical signs are worsening.

Part or all of this protocol may be considered based on your clinical impression of the patient:

**OBJECTIVE: keep albumin levels > 2 g/dl, avoid thromboembolism and cavitory effusions, monitor concurrent PLN (Wheaton Terrier PLE/PLN) and liver disease:**

**Plasma** 10 mL / kilogram IV over 4 hours

Or **Human albumin** 2 ml/kg/h over 10 hours. Total daily volume 20.l/kg/day

**And Colloids/Hetastarch**

10 to 20 mL per kilogram per day and dogs

10 to 15 mL per kilogram per day cats

(Can bolus first 1/3 of dose over 15 minutes)

& maintain on LRS maintenance otherwise.

**Metronidazole** (10-20 mg/kg po bid)

**Famotidine** 1 mg/kg Iv Im po dc Sid /bid

**Sucralfate** 0.5-1 g po tid dogs, 0.5 g bid cats in slurry Or **Misoprostol** 1-5 ug/kg po tid



**PATIENT**

Glee Chambless

**Diet:** Highly digestible high quality protein, low fiber, low fat diet (< 15% of dry matter). Hydrolyzed protein or novel protein. Purina HA or Royal Canine HP or similar.

**SPECIES**

Canine

**Prednisone** or prednisolone 2 mg/kg bid x 3-5 days then 2 mg/kg sid. **Chlorambucil** in refractive severe IBD/alimentary lymphoma cases (monitor cbc for rare bone marrow suppression) 4 mg/m<sup>2</sup> Q 24-48 hours.

**BREED**

French Bulldog

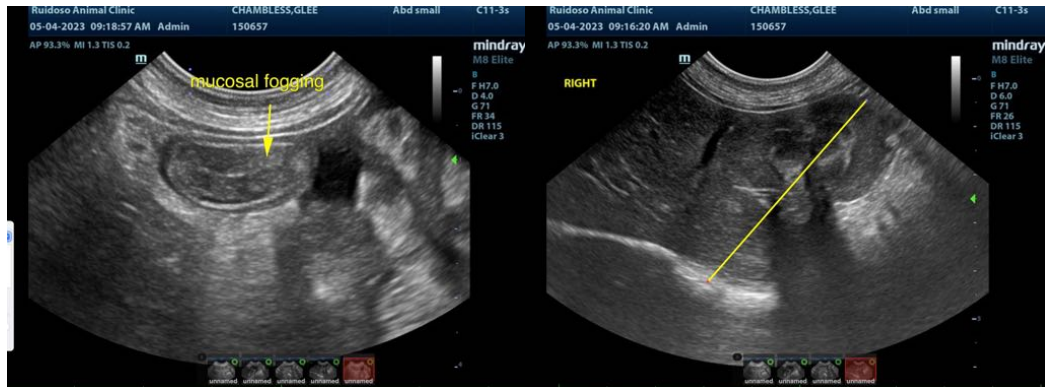
**Cobalamine** (B12) 250-1500 ug/dog weekly x 6 weeks.

**Calcium** supplementation if necessary.

**Aspirin** 0.5-1 mg/kg/day or **Clopidrel** (Plavix) 1-5 mg/kg/day.

**SEX**

Spayed female

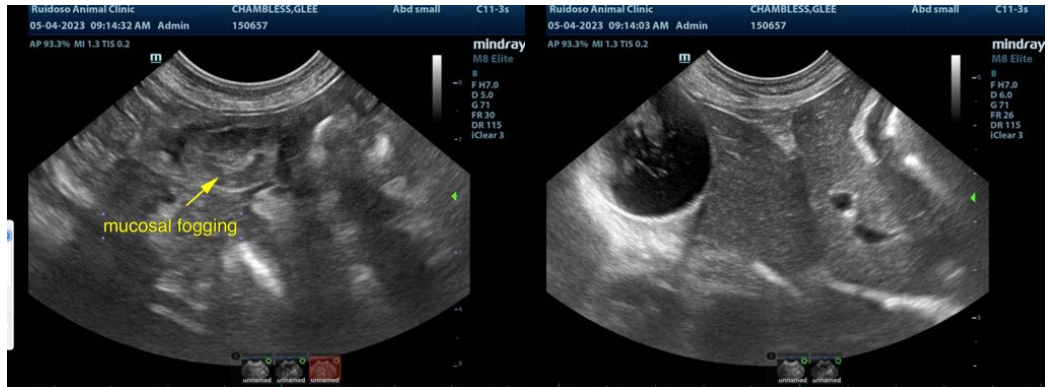

**AGE**

10 years

**WEIGHT**

20 lbs



**INTERPRETED BY**

Eric Lindquist, DMV  
DABVP, Cert. IVUSS

**IMAGING PERFORMED BY**

Dr. Favis

**HOSPITAL NAME**

Ruidoso Animal Clinic

**REFERRING VET**

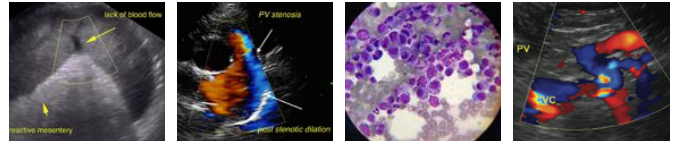
Dr. Favis

**INVOICE**

44168

**DATE**

5/4/23



**PATIENT**

Glee Chambless

**SPECIES**

Canine

**BREED**

French Bulldog

**SEX**

Spayed female

**AGE**

10 years

**WEIGHT**

20 lbs

**INTERPRETED BY**

Eric Lindquist, DMV  
DABVP, Cert. IVUSS

**IMAGING PERFORMED BY**

Dr. Favis

**HOSPITAL NAME**

Ruidoso Animal Clinic

**REFERRING VET**

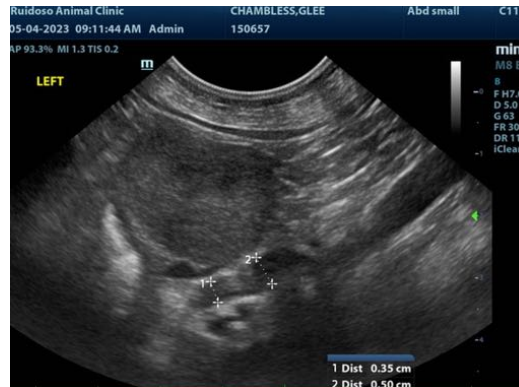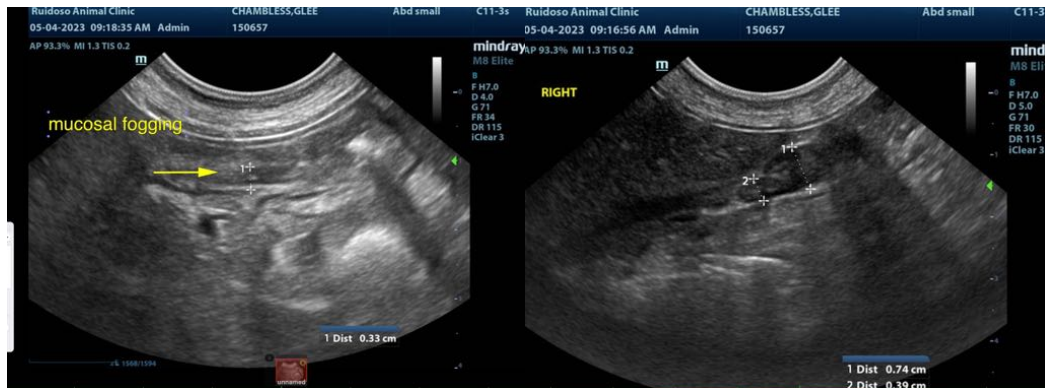
Dr. Favis

**INVOICE**

44168

**DATE**

5/4/23



The information and recommendations provided are based on the images presented by the referring veterinarian/sonographer. No evaluation can be communicated regarding pathology that was not visible in the image/video clips provided.

Thank you for this referral. If the clinical or image interpretation does not parallel your findings or if I can be of any further assistance please contact me.

**Eric Lindquist, DMV, DABVP, Cert. IVUSS, CEO of SonoPath.com**  
info@SonoPath.com