



PATIENT

Charlie Slanila

SPECIES

Canine

BREED

Beagle Mix

SEX

Spayed female

AGE

1 year

WEIGHT

37 lbs

INTERPRETED BY

Eric Lindquist, DMV
DABVP, Cert. IVUS

IMAGING PERFORMED BY

Jenn

HOSPITAL NAME

Rockaway AH

REFERRING VET

Dr. Maniar

INVOICE

44150

DATE

5/4/23

PRESENTING CLINICAL SIGNS

History: recheck stomach was over distended with progressively shadowing material up to 7.0 mm possible foreign material with chyme, carpeting

ULTRASONOGRAPHIC EXAMINATION OF THE ABDOMEN

Gastrointestinal

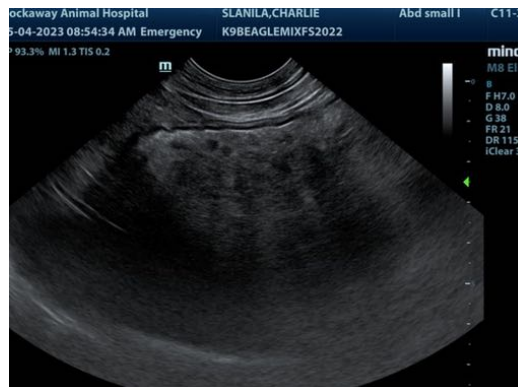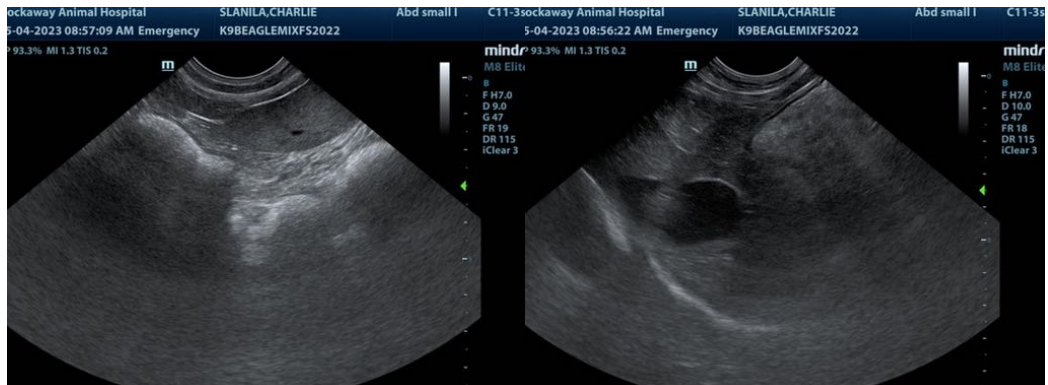
The stomach was over distended with chyme and partially shadowing material. This is similar to the prior sonogram. There was no significant change. The colon revealed normal stool consistency.

ULTRASONOGRAPHIC FINDINGS

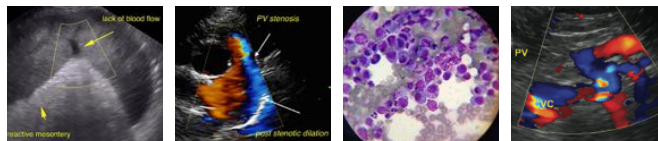
Delayed outflow pattern.

INTERPRETATION OF THE FINDINGS & FURTHER RECOMMENDATIONS

If the patient was n.p.o. then exploratory surgery is indicated. The cause of delayed outflow is not evident.



The information and recommendations provided are based on the images presented by the referring veterinarian/sonographer. No evaluation can be communicated regarding pathology that was not visible in the image/video clips provided.



PATIENT

Charlie Slanila

Thank you for this referral. If the clinical or image interpretation does not parallel your findings or if I can be of any further assistance please contact me.

SPECIES

Canine

Eric Lindquist, DMV, DABVP, Cert. IVUSS, CEO of SonoPath.com
info@SonoPath.com

BREED

Beagle Mix

SEX

Spayed female

AGE

1 year

WEIGHT

37 lbs

INTERPRETED BY

Eric Lindquist, DMV
DABVP, Cert. IVUSS

**IMAGING
PERFORMED BY**

Jenn

HOSPITAL NAME

Rockaway AH

REFERRING VET

Dr. Maniar

INVOICE

44150

DATE

5/4/23