



PATIENT

Gus Topper

PRESENTING CLINICAL SIGNS

presented for vomiting and drooling not walking straight and increased RR

SPECIES

Feline

ULTRASONOGRAPHIC EXAMINATION OF THE HEART

BREED

DSH

SEX

Neutered Male

AGE

14 Years

WEIGHT

16 Pounds

FELINE CARDIAC PARAMETERS	BODY WEIGHT (kg)	HR (BPM)	IVSd (cm)	LVIDd (cm)	LVWd (cm)	FS (%)	EF (%)
NORMAL PARAMETER	-----	150-240	0.3-0.6	1.0-2.1	0.25-0.6	35-67	80-100
PATIENT		NM					
FELINE CARDIAC PARAMETERS	LA/AO (Boon)	LA/AO HEART BASE (Sisson)	LA 2D 4-chamber long axis AS to FW (Sisson) (cm)	LVOT VEL. (m/s)	RVOT VEL. (m/s)	IVRT (m/)	
NORMAL PARAMETER	<1.5	0.88-1.79	0.7-1.7	<1.6	<1.3	40-60	
PATIENT	1.7	1.86			0.7	NM	

Adapted from June Boon, Veterinary Echocardiography, 1998
Sisson D et al. JVIM 1991; 5: 232, Jacobs et al. Am J Vet Res 1985; 46:1705

Cardiac Presentation

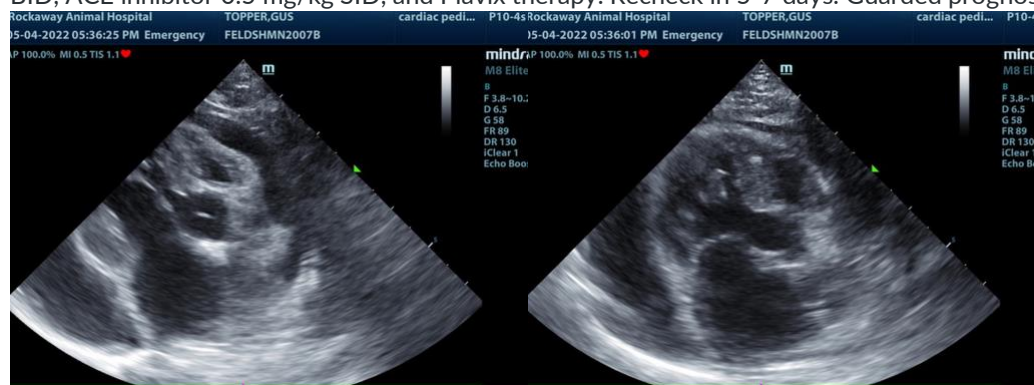
Left atrial size was excessive. Mitral insufficiency was present. Septal and free wall thicknesses were normal. Contractility was adequate. Slight pleural effusion and moderate pericardial effusion present. Rapid echocardiogram owing to the precarious nature of the presentation.

ULTRASONOGRAPHIC FINDINGS

- Unclassified cardiomyopathy

INTERPRETATION OF THE FINDINGS & FURTHER RECOMMENDATIONS

This is most consistent with unclassified cardiomyopathy. Left atrial enlargement and pericardial effusion is likely owing to left-sided failure. No evident tamponade effect at this time. However, an underlying neoplastic event cannot be ruled out. Recommend abdominal sonogram as well as to assess for related disease. Triple therapy with off-label Pimobendan at 0.3 mg/kg BID, Lasix at 6.25 mg/kg BID, ACE inhibitor 0.5 mg/kg SID, and Plavix therapy. Recheck in 5-7 days. Guarded prognosis.



INTERPRETED BY

Eric Lindquist, DMV

DABVP, Cert. IVUSS

IMAGING PERFORMED BY

Jenn

HOSPITAL NAME

Rockaway AH

REFERRING VET

Dr. Maniar

INVOICE

37358

DATE

5/4/22



PATIENT

Gus Topper

SPECIES

Feline

BREED

DSH

SEX

Neutered Male

AGE

14 Years

WEIGHT

16 Pounds

INTERPRETED BY

Eric Lindquist, DMV

DABVP, Cert. IVUSS

IMAGING PERFORMED BY

Jenn

HOSPITAL NAME

Rockaway AH

REFERRING VET

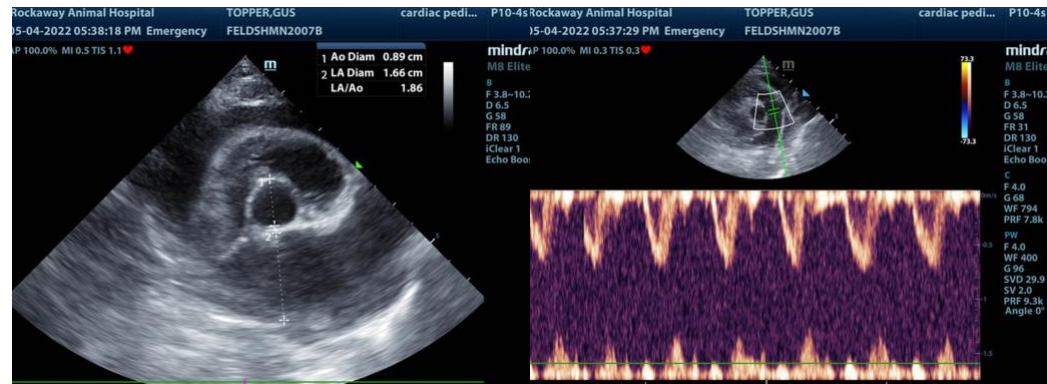
Dr. Maniar

INVOICE

37358

DATE

5/4/22



The information and recommendations provided are based on the images presented by the referring veterinarian/sonographer. No evaluation can be communicated regarding pathology that was not visible in the image/video clips provided.

Thank you for this referral. If the clinical or image interpretation does not parallel your findings or if I can be of any further assistance please contact me.

Eric Lindquist, DMV, DABVP, Cert. IVUSS, CEO of SonoPath.com

info@SonoPath.com