



PATIENT PRESENTING CLINICAL SIGNS

Cesar Lieff Large multi lobed swelling ventral neck both sides of trachea. Has had considerable weight loss. Was 40kg June 2021. BCS now 3/9. No current meds.
Abnormal PE/Chem/CBC/UA Results: CBC normal, Chem ALP elevated 143, stage 1 renal disease.
U/A Sp grav 1.022, Bilirubin 1+ and occasional struvite crystals otherwise NSF

SPECIES

Canine

ULTRASONOGRAPHIC EXAMINATION OF THE THYROID & CERVICAL REGION

BREED

American Bully

The thyroid and cervical region was fully imaged in this patient. Through transmission was difficult owing to the density of the pathology and likely thickened skin in this patient. However, the left region revealed multifocal expansive, mixed hyperechoic and hypoechoic masses owing to coalescing nodules up to 2.06 cm x 1.67 cm. The entire region measured approximately 6.0 cm. Normal thyroid tissue was not noted on the left. However, this was present in the right. The nodular changes extended over to the right cervical region, yet were primarily occupying the left cervical region. The visible trachea was unremarkable as were other regional tissues.

SEX

Neutered Male

INTERPRETATION OF THE FINDINGS & FURTHER RECOMMENDATIONS

AGE

10 Years

I'm presuming this pathology is deriving from the thyroid. However, salivary gland involvement cannot be completely ruled out. CT of the region would be recommended as well as ultrasound guided FNA of the nodular changes for further definition. I do not believe this is a surgical issue. Abdominal sonogram and chest radiographs recommended to further assess causes of weight loss related disease. Likely thyroid carcinoma or other neoplastic event.

WEIGHT

33.4 kg

INTERPRETED BY

Eric Lindquist, DMV
DABVP, Cert. IVUSS

IMAGING PERFORMED BY

Crystal Hill

HOSPITAL NAME

Westoak AH

REFERRING VET

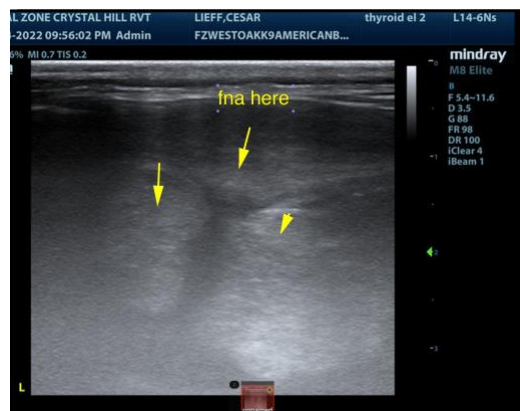
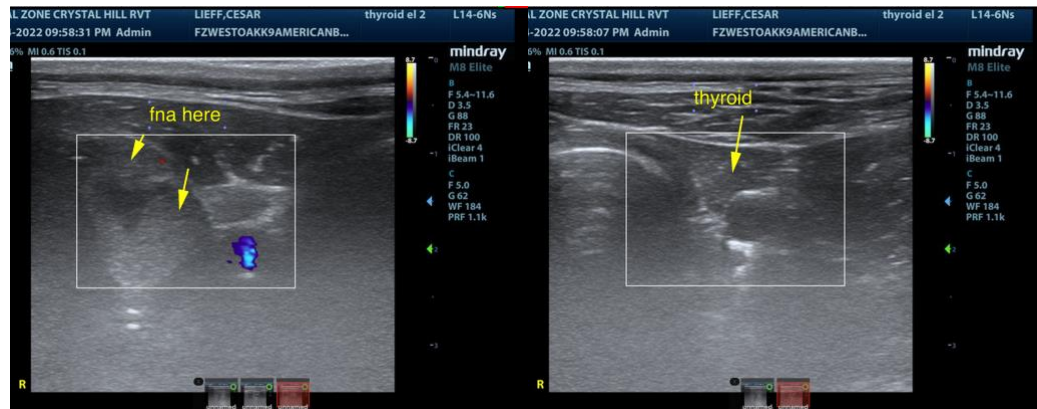
Dr. Kohlmaier

INVOICE

37378

DATE

5/4/22





PATIENT

Cesar Loeff

The information and recommendations provided are based on the images presented by the referring veterinarian/sonographer. No evaluation can be communicated regarding pathology that was not visible in the image/video clips provided.

SPECIES

Canine

Thank you for this referral. If the clinical or image interpretation does not parallel your findings or if I can be of any further assistance please contact me.

Eric Lindquist, DMV, DABVP, Cert. IVUSS, CEO of SonoPath.com

info@SonoPath.com

BREED

American Bully

SEX

Neutered Male

AGE

10 Years

WEIGHT

33.4 kg

INTERPRETED BY

Eric Lindquist, DMV

DABVP, Cert. IVUSS

IMAGING PERFORMED BY

Crystal Hill

HOSPITAL NAME

Westoak AH

REFERRING VET

Dr. Kohlmaier

INVOICE

37378

DATE

5/4/22