



**PATIENT**

Tucker Clark

**SPECIES**

Canine

**BREED**

German Shorthair  
Pointer

**SEX**

Neutered male

**AGE**

12 years

**WEIGHT**

56 lbs

**PRESENTING CLINICAL SIGNS**

Scan due to gradual increase in blood Calcium level, weight loss ( 13.4# in 9 months, 8.4# in 10wks). History of frequent VPC's but normal echocardiogram. Getting weaker in rear limbs. Drinking more than usual.

Abnormal PE/Chem/CBC/UA Results: PE: BCS 2/5, Nails long, Sclerosis normal for age, dental wear, multiple subcu masses, pale gums and sclera, chronic left cranial cruciate rupture. 3/5/22 LAST LABS UA: SG 1.012, pH 8.0, clear sediment CBC: normal Chem: Ca 14.2 mg/dL, ALP 207 U/L, Chol 445 mg/dL, Triglyceride 240 mg/dL, Creatine Kinase 295 U/L cPL Normal proBNP Normal Total T4 0.9ug/dL, Free T4 normal HELA: Negative Fecal antigen screen and flotation: Negative

**ULTRASONOGRAPHIC EXAMINATION OF THE ABDOMEN**

**Urinary System**

The **urinary bladder**, trigone, and pelvic urethra presented normal thicknesses and normal tone. The ureters were not visible which is normal. A minor amount of suspended debris was noted. No evidence of inflammatory or neoplastic changes was noted. Ureteral papillae were normal.

The residual prostate measured 1.0 cm.

The **kidneys** revealed normal size and structure, corticomedullary definition and ratio for this age. The cortices presented largely uniform texture with normal echogenic relationship to liver and spleen. Medullary structure differed distinctly from the cortex and no evidence of pelvic dilation was present. The capsules were acceptably uniform without significant irregularities. The left kidney measured 6.32 cm. The right kidney measured 5.45 cm.

**INTERPRETED BY**

Eric Lindquist, DMV,  
DABVP, Cert. IVUSS,  
CEO of SonoPath.com

**Adrenal Glands**

The left **adrenal gland** was mildly enlarged and uniform measuring 2.92 x 1.04 cm at the caudal pole and 0.8 cm at the cranial pole. The right adrenal gland is also uniformly enlarged and mildly heterogenous measuring up to 1.7 cm with capsular expansion without capsular escape noted.

**IMAGING PERFORMED BY**

Dr. Anderson

**Spleen**

The **spleen** presented a smooth homogeneous parenchyma hyperechoic to liver and renal cortical parenchyma. The capsule was smooth without noticeable expansion or deviation from within the spleen or adjacent pathology. The splenic vasculature demonstrated normal volume without signs of congestion or thrombosis. No sonographic evidence of acute or chronic inflammatory, neoplastic, or infarctual changes was noted.

**HOSPITAL NAME**

Elizabeth AH

**REFERRING VET**

Dr. Anderson

**Liver**

The **liver** images from right and left intercostal as well as subcostal views revealed subjectively normal liver size, contour, and structure. Some age-related parenchymal remodeling was noted but likely not clinically significant at this time. Vascular and biliary tracts were of normal volume and no evidence of congestion was noted. The gallbladder wall was slightly echogenic with a trace amount of debris.

**INVOICE**

30818

**DATE**

5/31/22



**PATIENT**

**Gastrointestinal**

Tucker Clark

Examination of the **gastrointestinal tract** revealed a stomach and intestine free of stasis, of normal wall thickness, acceptable curvilinear mural detail, and peristaltic activity. Small and large intestine demonstrated normal luminal chyme and stool consistency respectively. No obstructive or overt infiltrative disease was noted. No associated abnormal lymphatic activity was noted.

**SPECIES**

Canine

**BREED**

German Shorthair Pointer

**Pancreas**

The base and limbs of the **pancreas** were observed to be largely isoechoic to surrounding omental fat. Pancreatic duct and capsular contour were acceptably normal and parenchyma respected normal curvilinear patterns. No overt evidence of active inflammatory or neoplastic disease was noted.

**SEX**

Neutered male

**Free Abdomen**

The esophagus, trachea, carotid, salivary glands and regional soft tissue all appeared normal. The left thyroid lobe revealed two separate hypoechoic, expansive nodules that measured 0.6 cm and 0.54 cm. The nodules occupied the mid thyroid lobe. This is strongly suggestive for parathyroid adenoma. The right thyroid lobe was unremarkable.

**AGE**

12 years

**WEIGHT**

56 lbs

**ULTRASONOGRAPHIC FINDINGS**

Bilateral adrenal enlargement.

**INTERPRETED BY**

Age related renal changes.

Eric Lindquist, DMV, DABVP, Cert. IVUSS, CEO of SonoPath.com

Hepatic remodeling.

Left thyroid nodules. Consistent with parathyroid adenomas.

**IMAGING PERFORMED BY**

Dr. Anderson

**INTERPRETATION OF THE FINDINGS & FURTHER RECOMMENDATIONS**

Surgical intervention upon the left thyroid gland is recommended if hypercalcemia panel supports primary hyperparathyroidism.

**HOSPITAL NAME**

Elizabeth AH

**REFERRING VET**

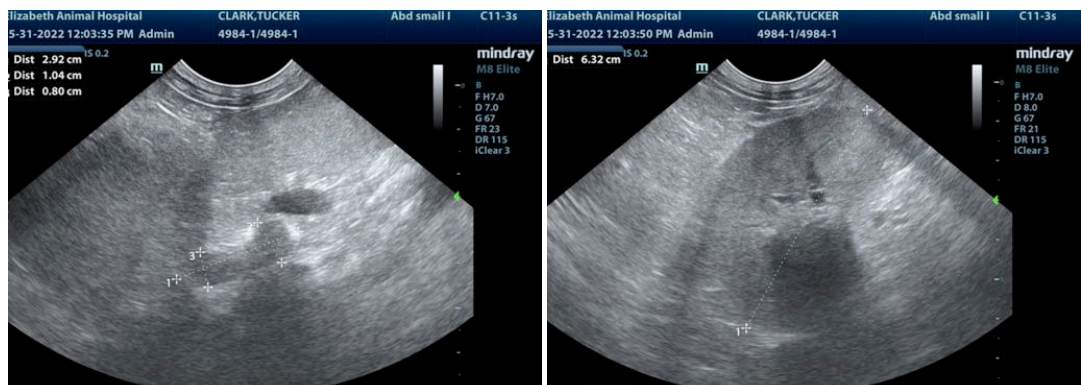
Dr. Anderson

**INVOICE**

30818

**DATE**

5/31/22





**PATIENT**

Tucker Clark

**SPECIES**

Canine

**BREED**

German Shorthair Pointer

**SEX**

Neutered male

**AGE**

12 years

**WEIGHT**

56 lbs

**INTERPRETED BY**

Eric Lindquist, DMV,  
DABVP, Cert. IVUSS,  
CEO of SonoPath.com

**IMAGING PERFORMED BY**

Dr. Anderson

**HOSPITAL NAME**

Elizabeth AH

**REFERRING VET**

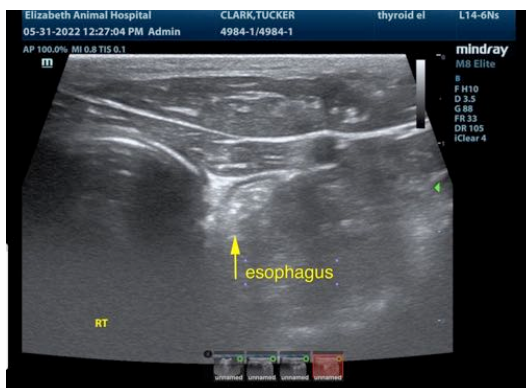
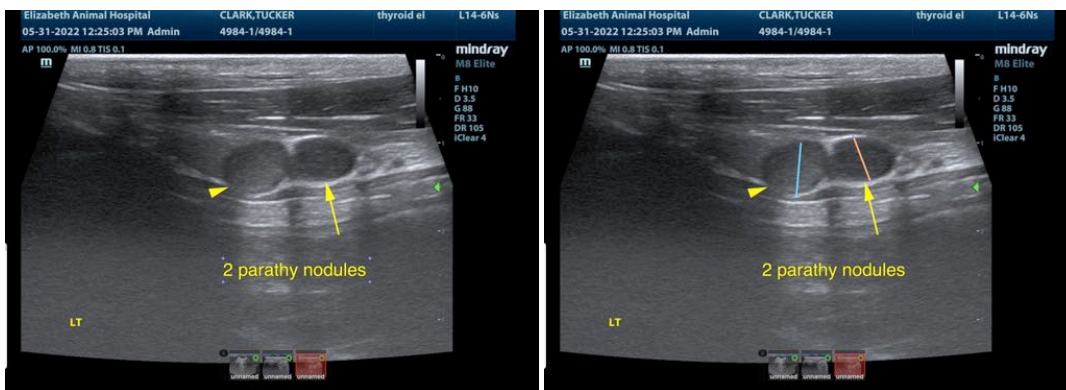
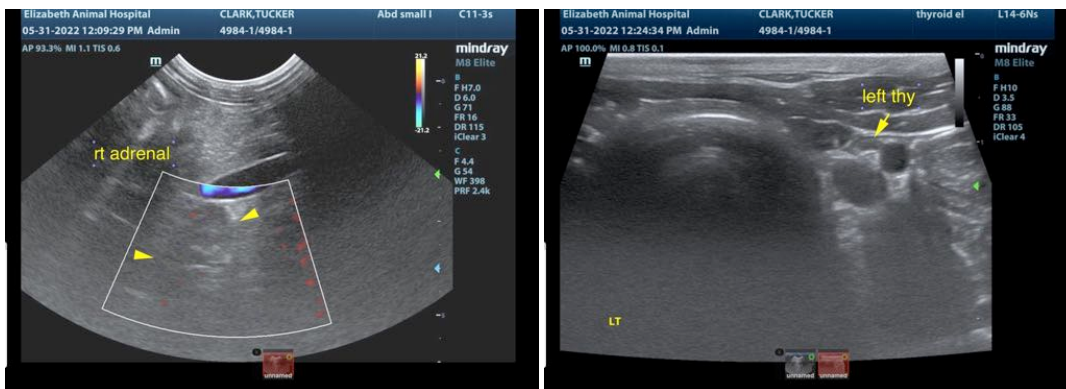
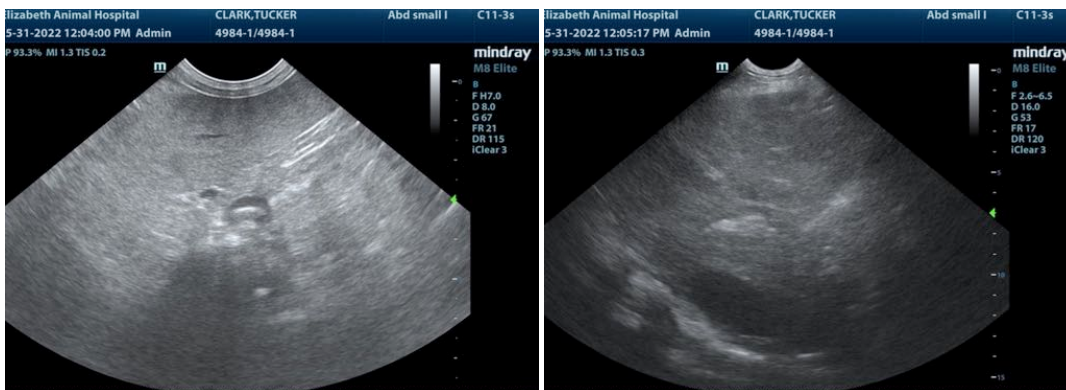
Dr. Anderson

**INVOICE**

30818

**DATE**

5/31/22





**PATIENT**

Tucker Clark

**SPECIES**

Canine

The information and recommendations provided are based on the images presented by the referring veterinarian/sonographer. No evaluation can be communicated regarding pathology that was not visible in the image/video clips provided.

**BREED**

German Shorthair  
Pointer

Thank you for this referral. If the clinical or image interpretation does not parallel your findings or if I can be of any further assistance please contact me.

Eric Lindquist, DMV, DABVP, Cert. IVUSS, CEO of SonoPath.com


**SEX**

Info@SonoPath.com

Neutered male

**AGE**

12 years



The following is an applicable excerpt from the *Curbside Guide to Diagnosis & Treatment of Sonographic Disease* offered by [SonoPath.com](http://sonopath.com) Lindquist, Frank, Lobetti, and Modler.

An essential quick guide for every general practitioner and sonographer.

<https://sonopath.com/products/curbside-guide-editing-due-release-12012015>

**WEIGHT**

56 lbs

**CANINE HYPERCALCEMIA**

<http://www.sonopath.com/CanineHypercalcemia>

**INTERPRETED BY**

Eric Lindquist, DMV,  
DABVP, Cert. IVUSS,  
CEO of SonoPath.com

**IMAGING PERFORMED BY**

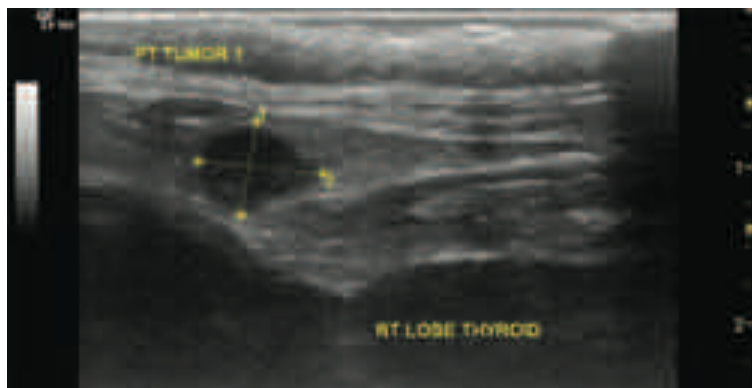
Dr. Anderson

**HOSPITAL NAME**

Elizabeth AH

**REFERRING VET**

Dr. Anderson



Long axis of the right thyroid lobe in a dog with a parathyroid adenoma. The right internal parathyroid gland (between calipers) shows severe uniform enlargement of more than 7mm.

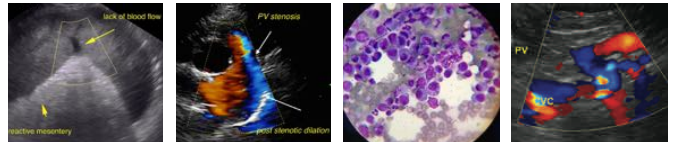
**INVOICE**

30818

**DATE**

5/31/22

**Description:** Hypercalcemia is defined as either a persistently elevated total calcium serum (> 12 mg/dl) or ionized calcium (> 1.45 mmol/l) concentration. Clinical signs are often absent with mild hypercalcemia (< 13 mg/dl). In fact, hypercalcemia is often only discovered when serum biochemistry is done for unrelated reasons. Clinical signs are usually mild when the serum calcium concentration is less than 14 mg/dl; however, signs become more readily apparent when the concentration exceeds 15



**PATIENT**

mg/dl. Life-threatening cardiac arrhythmias can develop when the serum calcium exceeds 18 mg/dl.

Tucker Clark

**SPECIES**

Common etiologies of hypercalcemia include humoral hypercalcemia of malignancy (HHM), hypoadrenocorticism, chronic kidney disease (CKD), hypervitaminosis D, and primary hyperparathyroidism. Less common etiologies include bone neoplasia, osteomyelitis, hypertrophic osteodystrophy, granulomatous disease, calcium supplementation, and oral phosphate binders.

Canine

**BREED**

**Clinical Signs:** Common clinical signs include polyuria, polydipsia, lethargy, inappetence, and weakness. With chronic hypercalcemia, calcium oxalate and calcium phosphate uroliths can form, resulting in clinical signs suggestive of lower urinary tract disease. Systemic signs of illness are suggestive of HHM.

German Shorthair  
Pointer

**SEX**

**Diagnostics:** One important etiology of hypercalcemia is laboratory error; therefore, hypercalcemia should always be confirmed before embarking on any further diagnostic evaluation. Results of a CBC, serum biochemistry panel, and urinalysis, in conjunction with a patient history and findings from a physical examination, can often provide enough information to arrive at a diagnosis. The appendicular skeleton, peripheral lymph nodes, abdominal cavity, and rectum should all be carefully palpated for masses, lymphadenopathy, hepatomegaly, splenomegaly, and/or pain in the long bones. The following diagnostic tests are helpful for identifying an underlying malignancy: thoracic and abdominal radiographs; abdominal ultrasound; cytological evaluation of aspirates of the liver, spleen, lymph nodes, and bone marrow; determination of serum ionized calcium, parathyroid hormone (PTH), and parathyroid hormone-related protein concentration (PTHrP); and ultrasound of the neck. Ascertaining the concentrations of serum ionized calcium, PTH, and PTHrP helps differentiate primary hyperparathyroidism from HHM. The finding of one or more enlarged parathyroid glands upon conducting an ultrasound of the neck supports a diagnosis of primary hyperparathyroidism.

Neutered male

**AGE**

Hypoadrenocorticism-induced hypercalcemia usually occurs in conjunction with hyponatremia, hyperkalemia, and prerenal azotemia. With HHM and primary hyperparathyroidism, serum phosphorus concentration is often in the low to low-normal reference range. If the serum phosphorus concentration is high but kidney function is normal, hypervitaminosis D or osteolysis should be suspected.

12 years

**WEIGHT**

56 lbs

**INTERPRETED BY**

Eric Lindquist, DMV,  
DABVP, Cert. IVUSS,  
CEO of SonoPath.com

**IMAGING PERFORMED BY**

Dr. Anderson

**HOSPITAL NAME**

Elizabeth AH

**REFERRING VET**

Dr. Anderson

It can be difficult to determine whether kidney failure is primary or secondary to hypercalcemia when hyperphosphatemia and hypercalcemia coexist with azotemia. Serum ionized calcium concentrations are typically normal or decreased in cases of renal failure and increased in cases of hypercalcemia caused by other disorders.

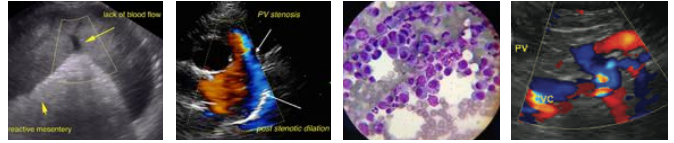
**INVOICE**

30818

Sternal and hilar lymphadenopathy is common with lymphoma-induced hypercalcemia and can be readily identified on thoracic radiographs. In cases of multiple myeloma, discrete lytic lesions in the vertebrae or long bones, hyperproteinemia, proteinuria, and plasma cell infiltration in the bone marrow may be present. Cytological evaluation of the peripheral lymph nodes, bone marrow, and spleen can be helpful in identifying lymphoma.

**DATE**

5/31/22



**PATIENT**

Tucker Clark

Increased serum ionized calcium concentrations, detectable serum PTHrP concentrations, and non-detectable serum PTH concentrations are all diagnostic for HHM. Lymphoma is the most common etiology of HHM, but other tumors, such as apocrine gland adenocarcinoma and various carcinomas (e.g. mammary gland, squamous cell, bronchogenic), can all give rise to hypercalcemia. Increased serum ionized calcium, normal to increased serum PTH, and non-detectable PTHrP concentrations are diagnostic of primary hyperparathyroidism.

**SPECIES**

Canine

**BREED**

German Shorthair  
Pointer

**Differentials for Hypercalcemia: "HARD IONS"**

Hyperparathyroid

**SEX**

Neutered male

Addison's

Renal

**AGE**

12 years

D-toxicity

Idiopathic

Osteolytic

**WEIGHT**

56 lbs

Neoplastic

Spurious

**INTERPRETED BY**

Eric Lindquist, DMV,  
DABVP, Cert. IVUSS,  
CEO of SonoPath.com

**PTH tumor:** Elevated total and ionized Ca, low PTHrP, and normal/high PTH. Keeshonds, German Shepherds, and Golden Retrievers are all predisposed.

**Addison's disease:** Elevated total and normal ionized Ca, elevated BUN, hypoalbuminemia and hyperkalemia.

**IMAGING PERFORMED BY**

Dr. Anderson

**Renal failure:** Elevated to normal total Ca, low ionized Ca, low PTHrP, elevated PTH, azotemia, and low urine specific gravity.

**Vitamin D toxicity:** Elevated total and ionized Ca, low PTHrP, and normal/low PTH.

**HOSPITAL NAME**

Elizabeth AH

**Hypercalcemia of malignancy (HHM):** Elevated total and ionized Ca, high PTHrP, and low PTH.

**Granulomatous disease:** Elevated total and ionized Ca, low PTHrP, and low PTH.

**REFERRING VET**

Dr. Anderson

**Renal failure:** Elevated to normal total Ca, low ionized Ca, low PTHrP, elevated PTH, azotemia, and low urine specific gravity.

**INVOICE**

30818

**Treatment:** Therapies for hypercalcemia are aimed at correcting the underlying etiology; however, because prolonged hypercalcemia can result in kidney damage, the use of fluid therapy, furosemide, and possibly prednisone is indicated in all cases to reduce serum calcium levels. Suggested dosages include saline (0.9% 120-180 ml/kg day IV), furosemide (1-4 mg/kg PO TID), and prednisone (0.25 mg/kg PO Q24hr).

**DATE**

5/31/22



**PATIENT**

Tucker Clark

**SPECIES**

Canine

**BREED**

German Shorthair  
Pointer

**SEX**

Neutered male

**AGE**

12 years

**WEIGHT**

56 lbs

**INTERPRETED BY**

Eric Lindquist, DMV,  
DABVP, Cert. IVUSS,  
CEO of SonoPath.com

**IMAGING  
PERFORMED BY**

Dr. Anderson

**HOSPITAL NAME**

Elizabeth AH

**REFERRING VET**

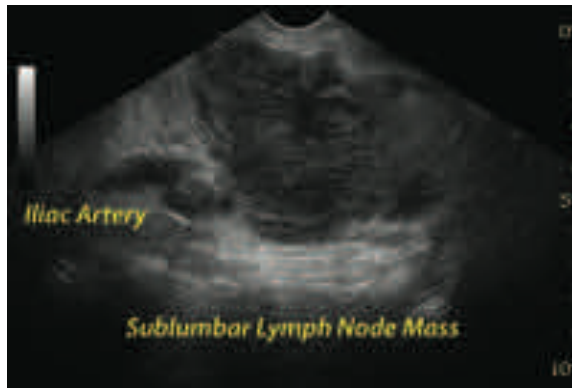
Dr. Anderson

**INVOICE**

30818

**DATE**

5/31/22



Long axis of the left hypogastric lymph node in a hypercalcemic dog with lymphoma and hypercalcemia of malignancy. The lymph node is severely enlarged and rounded with a short-to-long-axis ratio > 0.5 indicating malignant infiltration. The regular echoarchitecture is lost, the hilus is not recognized, lymph node parenchyma is hypoechoic and heterogenous. Also note the mass effect on the external iliac artery. In light of hypercalcemia, lymphadenopathy in this region could also be owing to anal gland adenocarcinoma which can also be imaged sonographically.

**References:**

Chew DJ, Schenck PA, Jaeger JQ. Clinical disorders of hypercalcemia and hypocalcemia in dogs and cats. Proceedings from the American College of Veterinary Internal Medicine, Charlotte, NC, June 4-7, 2003.

Feldman EC. Disorders of the parathyroid glands. In: Ettinger SJ, Feldman EC, ed. *Textbook of Veterinary Internal Medicine, 7th ed.* St. Louis, MO: Saunders Elsevier; 2010:1722-50.

Peterson ME. Hypercalcemia in dogs & cats: differential diagnosis & treatment. Proceedings from the Western Veterinary Conference, Las Vegas, NV, February 19-23, 2012.