


PATIENT

Scrapy Gomez

PRESENTING CLINICAL SIGNS

History: Chest X-ray (L. R) show the trachea pushed dorsally Evaluate chest for mass (lung vs mediastinal). Radiographs attached.

SPECIES

Canine

ULTRASONOGRAPHIC EXAMINATION OF THE HEART

The cardiac presentation in this patient presented thickened mitral valve. The contractility and volume were normal. A 4.3 cm mixed echogenic lymph node or thymus based mass was noted in the cranial mediastinum and impinged upon the aorta. The visible lung fields are unremarkable.

BREED

Mix

SEX

Neutered male

AGE

2014

WEIGHT

14 lbs

INTERPRETED BY

 Eric Lindquist, DMV
 DABVP, Cert. IVUSS

CANINE CARDIAC PARAMETERS	MR VMAX (m/s)	TR VMAX (m/s)	LA/AO (Boon method)	LA/AO (Heart Base; Swe)	FS (%)	EF (%)	EPSS (cm)
NORMAL PARAMETER	4.5-5.5	<2.7	1.3	<1.3	28-40	40-100	<0.6
PATIENT			NM		45	78	0.1
CANINE CARDIAC PARAMETERS	HR (BPM)	AV VMAX (m/s)	PV MAX (m/s)	BODY WEIGHT	LA 2D short axis Base view (cm)	LVIDd Avg; 2D and m- mode short axis (cm)	LVIDs Avg; 2D and m-mode short axis (cm)
NORMAL PARAMETER	50-100	0.7-1.7	0.7-1.6				
PATIENT				14 lbs	2.5 max	2.43	

**IMAGING
PERFORMED BY**

 Denise Bruno, LVT,
 RDMS

ULTRASONOGRAPHIC FINDINGS

No primary cardiac disease is noted.

Cranial mediastinal mass, likely lymph node in origin.

HOSPITAL NAME

Kenilworth AH

INTERPRETATION OF THE FINDINGS & FURTHER RECOMMENDATIONS

Treatment is recommended based on FNA results. No cardiac medications are recommended. An abdominal sonogram is recommended to assess for primary mass that may be metastatic to the chest.

REFERRING VET

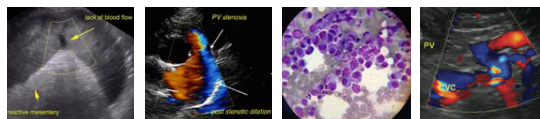
Dr. Mansour

INVOICE

30826

DATE

5/31/22



PATIENT

Scrappy Gomez

SPECIES

Canine

BREED

Mix

SEX

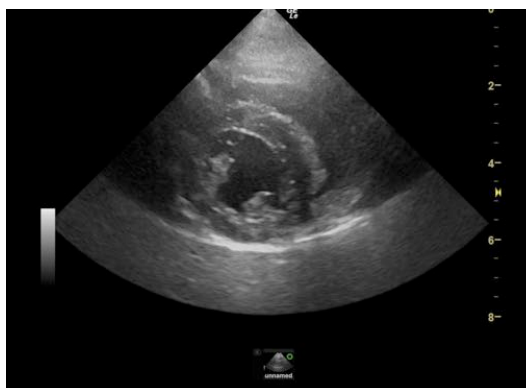
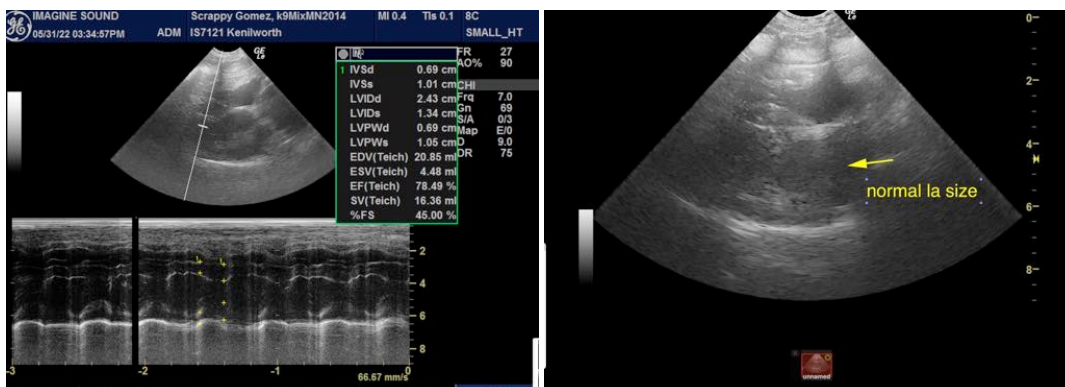
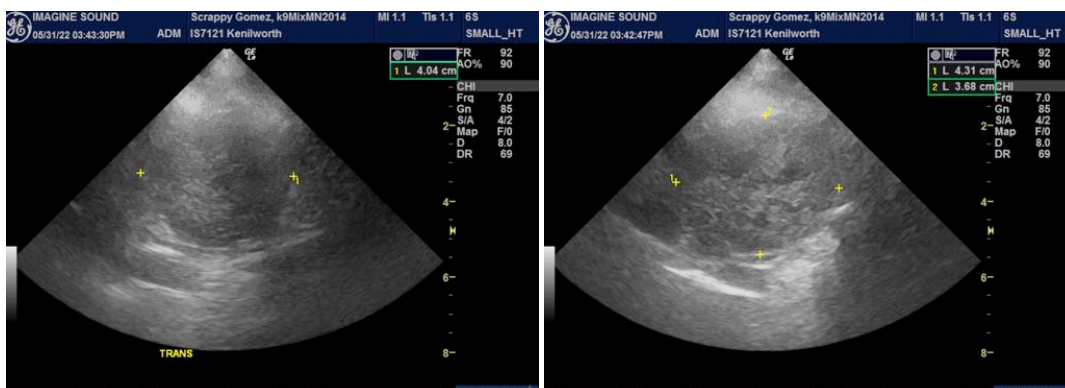
Neutered male

AGE

2014

WEIGHT

14 lbs



INTERPRETED BY

Eric Lindquist, DMV
 DABVP, Cert. IVUSS

IMAGING PERFORMED BY

Denise Bruno, LVT,
 RDMS

HOSPITAL NAME

Kenilworth AH

REFERRING VET

Dr. Mansour

INVOICE

30826

DATE

5/31/22

The information and recommendations provided are based on the images presented by the referring veterinarian/sonographer. No evaluation can be communicated regarding pathology that was not visible in the image/video clips provided.

Thank you for this referral. If the clinical or image interpretation does not parallel your findings or if I can be of any further assistance please contact me.

Eric Lindquist, DMV, DABVP, Cert. IVUSS, CEO of SonoPath.com
 Eric.Lindquist@SonoPath.com