



**PATIENT PRESENTING CLINICAL SIGNS**

Dolly Cahill History: History of bladder stones, surgery 2/11/21. Ultrasound to check for reoccurrence of stones.  
Abnormal PE/Chem/CBC/UA Results: UA Struvite crystals. Asymptomatic

**SPECIES ULTRASONOGRAPHIC EXAMINATION OF THE ABDOMEN**

Canine

**Urinary System**

**BREED**

Shih Tzu

The **urinary bladder**, trigone, and pelvic urethra presented normal thicknesses and normal tone. The ureters were not visible which is normal. No uroliths or sediment were visualized and anechoic urine was present. No evidence of inflammatory or neoplastic changes was noted. Ureteral papillae were normal.

**SEX**

Spayed Female

**AGE**

4 years

The **kidneys** revealed normal size and structure, corticomedullary definition and ratio for this age. The cortices presented largely uniform texture with normal echogenic relationship to liver and spleen. Medullary structure differed distinctly from the cortex and no evidence of pelvic dilation was present. The capsules were acceptably uniform without significant irregularities. The left kidney measured 3.46 cm. The right kidney measured 3.63 cm.

**WEIGHT**

12.5 lbs

**Adrenal Glands**

Both **adrenal glands** were visualized and recognized as having normal shape, size, position and echogenicity for this breed. The phrenic vasculature, glandular echogenicity and detail were unremarkable. Capsule, cortex, and medullary definition were normal for this age patient. The left adrenal gland measured 1.18 x 0.39 cm.

**INTERPRETED BY**

Eric Lindquist, DMV  
DABVP, Cert. IVUSS

**Spleen**

**IMAGING PERFORMED BY**

JK

The **spleen** presented a smooth homogeneous parenchyma hyperechoic to liver and renal cortical parenchyma. The capsule was smooth without noticeable expansion or deviation from within the spleen or adjacent pathology. The splenic vasculature demonstrated normal volume without signs of congestion or thrombosis. No sonographic evidence of acute or chronic inflammatory, neoplastic, or infarctual changes was noted.

**HOSPITAL NAME**

Hamburg VC

**Liver**

**REFERRING VET**

Dr. Martens

The **liver** was structurally unremarkable with mild microhepatica. The gallbladder presented acceptably thin walls with primarily anechoic content. The cystic and common bile ducts were normal. No pathological hepatic lymphadenopathy was evident. No overt structural evidence of inflammatory, infiltrative or regenerative pathology was evident.

**INVOICE**

30813

**Gastrointestinal**

**DATE**

5/31/22

The gastric lumen was fluid filled. The small intestine and colon were unremarkable.



**PATIENT**

Dolly Cahill

**Pancreas**

**SPECIES**

Canine

The base and limbs of the **pancreas** were observed to be largely isoechoic to surrounding omental fat. Pancreatic duct and capsular contour were acceptably normal and parenchyma respected normal curvilinear patterns. No overt evidence of active inflammatory or neoplastic disease was noted.

**BREED**

Shih Tzu

**ULTRASONOGRAPHIC FINDINGS**

Mild microhepatica.

Mild gastric fluid.

**SEX**

Unremarkable urinary tract.

Spayed Female

**AGE**

4 years

**INTERPRETATION OF THE FINDINGS & FURTHER RECOMMENDATIONS**

Bile acid profile is warranted to assess for any elevation that would be consistent with portal hypoplasia/microvascular dysplasia. Assessment for any history of GI issues is warranted given the gastric fluid accumulation.

**WEIGHT**

12.5 lbs

**INTERPRETED BY**

Eric Lindquist, DMV  
DABVP, Cert. IVUSS

**IMAGING PERFORMED BY**

JK

**HOSPITAL NAME**

Hamburg VC

**REFERRING VET**

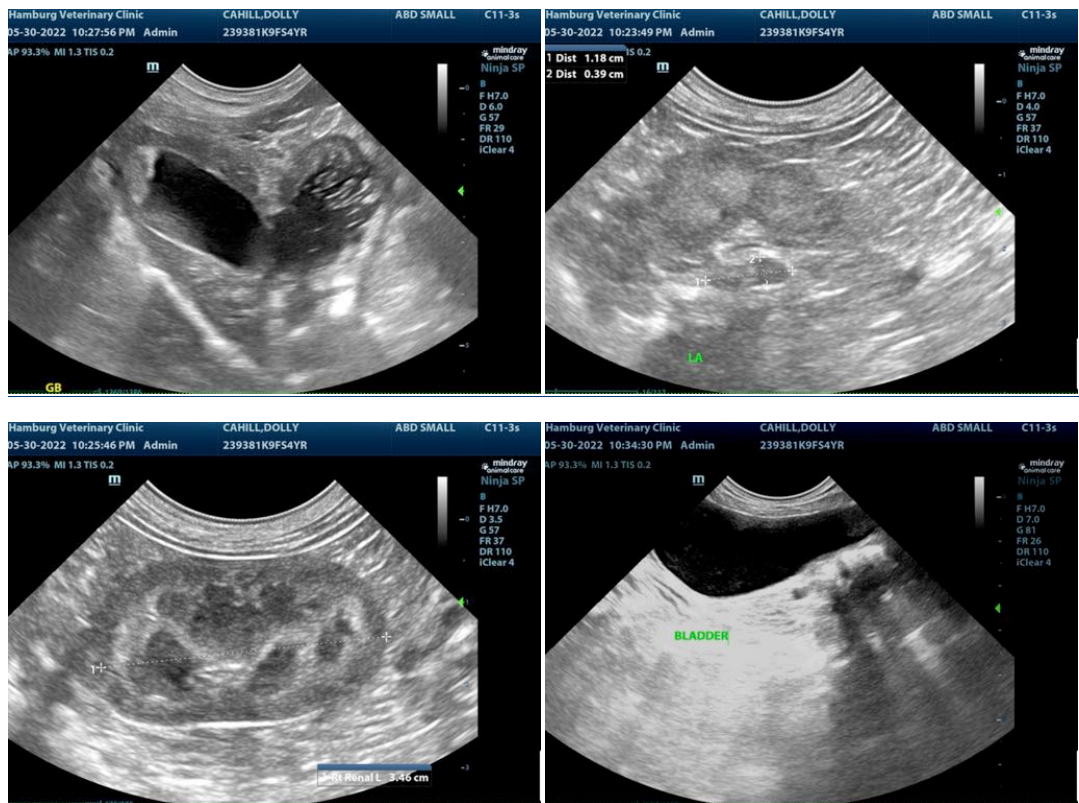
Dr. Martens

**INVOICE**

30813

**DATE**

5/31/22





**PATIENT**

Dolly Cahill

**SPECIES**

Canine

**BREED**

Shih Tzu

**SEX**

Spayed Female

**AGE**

4 years

**WEIGHT**

12.5 lbs

**INTERPRETED BY**

Eric Lindquist, DMV  
DABVP, Cert. IVUSS

**IMAGING PERFORMED BY**

JK

**HOSPITAL NAME**

Hamburg VC

**REFERRING VET**

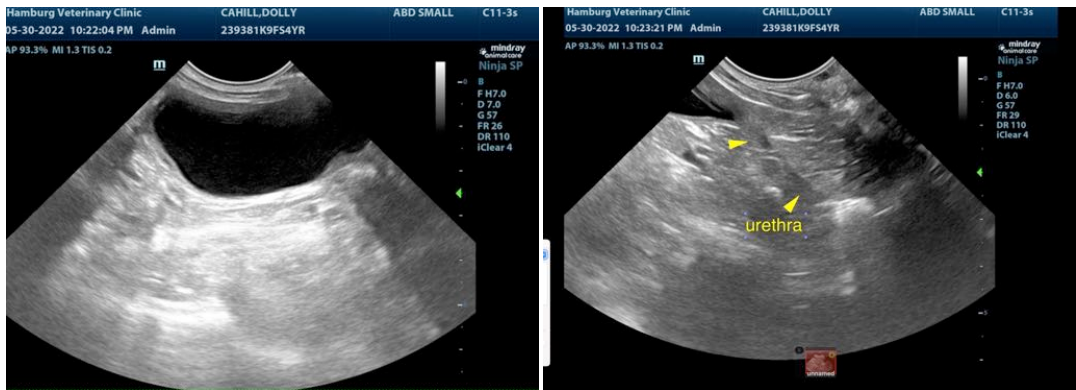
Dr. Martens

**INVOICE**

30813

**DATE**

5/31/22



The information and recommendations provided are based on the images presented by the referring veterinarian/sonographer. No evaluation can be communicated regarding pathology that was not visible in the image/video clips provided.

Thank you for this referral. If the clinical or image interpretation does not parallel your findings or if I can be of any further assistance please contact me.

Eric Lindquist, DMV, DABVP, Cert. IVUSS, CEO of SonoPath.com  
info@SonoPath.com