



PATIENT

Delilah Potteiger

SPECIES

Canine

BREED

Mix

SEX

Spayed Female

AGE

9 years

WEIGHT

27 lbs

INTERPRETED BY

Eric Lindquist, DMV
DABVP, Cert. IVUSS

IMAGING PERFORMED BY

Dr. Todd

HOSPITAL NAME

Lambs Gap AH

REFERRING VET

Dr. Campbell

INVOICE

30816

DATE

5/31/22

PRESENTING CLINICAL SIGNS

History: Delilah is a nine year old, FS, mixed breed who was presented today for dental prophylaxis. She has had chronic intermittent hematuria. No calculi were visible on radiographs today at dental, US bladder was performed while here.

ULTRASONOGRAPHIC EXAMINATION OF THE ABDOMEN

Urinary System

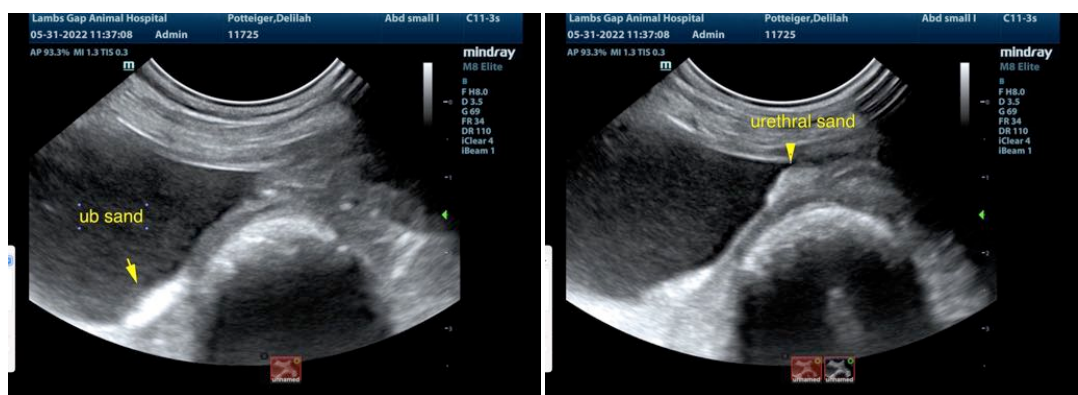
The **urinary bladder** revealed sand accumulation. Grouping of sand measured approximately 1.0 cm. The pelvic urethra also presented a minor amount of urethral sand. Mineralized urethral tissue was also noted in this patient and extended at least 3.0 cm caudal from the cystourethral junction. This expanded into an overt urethral mass with regional inflammation. The urethral mass measured 1.8 cm. in maximum width.

ULTRASONOGRAPHIC FINDINGS

Urethral mass with concurrent bladder sand and inflammation.

INTERPRETATION OF THE FINDINGS & FURTHER RECOMMENDATIONS

Referral for urethral stent placement and eventual chemotherapy is indicated. Full sonogram would be ideal to assess for metastatic disease. Transitional cell carcinoma is suspected.





PATIENT

Delilah Potteiger

SPECIES

Canine

BREED

Mix

SEX

Spayed Female

AGE

9 years

WEIGHT

27 lbs

INTERPRETED BY

Eric Lindquist, DMV
DABVP, Cert. IVUSS

IMAGING PERFORMED BY

Dr. Todd

HOSPITAL NAME

Lambs Gap AH

REFERRING VET

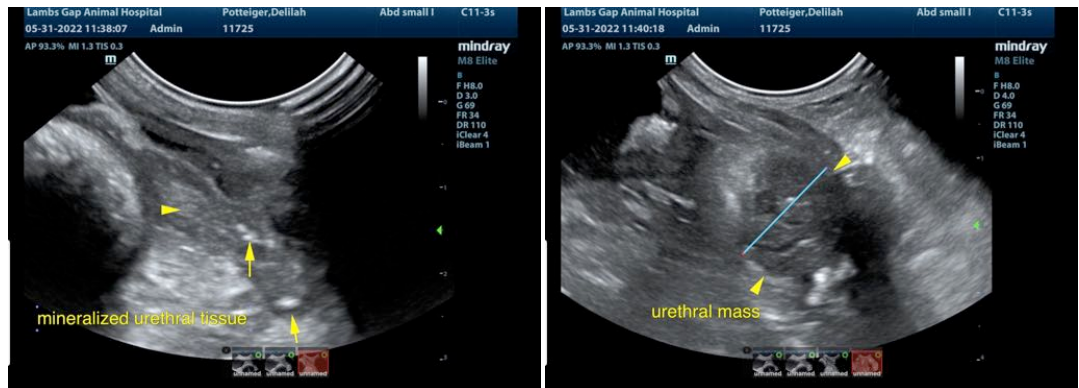
Dr. Campbell

INVOICE

30816

DATE

5/31/22



The information and recommendations provided are based on the images presented by the referring veterinarian/sonographer. No evaluation can be communicated regarding pathology that was not visible in the image/video clips provided.

Thank you for this referral. If the clinical or image interpretation does not parallel your findings or if I can be of any further assistance please contact me.

Eric Lindquist, DMV, DABVP, Cert. IVUSS, CEO of SonoPath.com
info@SonoPath.com