



PATIENT

Tati Beach

PRESENTING CLINICAL SIGNS

History: Chronic intermittent vomiting . Suspect IND Food intolerance
Abnormal PE/Chem/CBC/UA Results: Non diagnostic

SPECIES

Feline

ULTRASONOGRAPHIC EXAMINATION OF THE ABDOMEN

BREED

DMH

Urinary System

The urinary bladder, trigone, and pelvic urethra presented normal thicknesses and normal tone. The ureters were not visible which is normal. No uroliths or sediment were visualized and anechoic urine was present. No evidence of inflammatory or neoplastic changes were noted. Ureteral papillae were normal.

SEX

FS

The kidneys revealed normal size and structure, corticomedullary definition and ratio for this age. The cortices presented largely uniform texture with normal echogenic relationship to liver and spleen. Medullary structure differed distinctly from the cortex and no evidence of pelvic dilation was present. The capsules were acceptably uniform without significant irregularities. The left kidney measured 3.3 cm in length. The right kidney measured 3.28 cm in length.

AGE

9 yr

Adrenal Glands

Both adrenal glands were visualized and recognized as having normal shape, size, position and echogenicity for this breed. The phrenic vasculature, glandular echogenicity and detail were unremarkable. Capsule, cortex, and medullary definition were normal for this age patient. The right adrenal gland measured 0.26 cm.

WEIGHT

4.3 kg

INTERPRETED BY

Eric Lindquist, DMV
DABVP, Cert. IVUSS

Spleen

The spleen presented a smooth homogeneous parenchyma hyperechoic to liver and renal cortical parenchyma. The capsule was smooth without noticeable expansion or deviation from within the spleen or adjacent pathology. The splenic vasculature demonstrated normal volume without signs of congestion or thrombosis. No sonographic evidence of acute or chronic inflammatory, neoplastic, or infarctual changes were noted.

IMAGING PERFORMED BY

Dr. Belan

Liver

The liver images submitted revealed subjectively normal liver size, contour, and structure. Parenchymal echogenicity was naturally coarse and hypoechoic to the spleen. Vascular and biliary tracts were of normal volume with no evidence of congestion. The gallbladder presented acceptably thin walls with primarily anechoic content. The cystic and common bile ducts were normal. No pathological hepatic lymphadenopathy was evident. No overt structural evidence of inflammatory, infiltrative or regenerative pathology was evident.

HOSPITAL NAME

Properties Animal
Clinic

REFERRING VET

Dr. Costa

Gastrointestinal

The gastrointestinal tract revealed minor variable thickening and echogenic submucosal changes most consistent with low grade end result of chronic GI disease such as IBD and may be related to malassimilation of nutrients if any weight loss is present. The colonic wall was slightly thickened. Wall thickness up to 0.26 cm in width was present. No obvious neoplastic patterns were noted and luminal content as unremarkable.

INVOICE

10694ag

DATE

Pancreas

05/30/2022



PATIENT

Tati Beach

SPECIES

Feline

BREED

DMH

SEX

FS

AGE

9 yr

WEIGHT

4.3 kg

INTERPRETED BY

Eric Lindquist, DMV
DABVP, Cert. IVUSS

IMAGING PERFORMED BY

Dr. Belan

HOSPITAL NAME

Properties Animal
Clinic

REFERRING VET

Dr. Costa

INVOICE

10694ag

DATE

05/30/2022

The base and limbs of the pancreas were observed to be largely isoechoic to surrounding omental fat. Some parenchymal remodeling, however, with mild deviation from curvilinear normalcy was observed. Pancreatic duct and capsular irregularities were present consistent with age related changes. If pain upon imaging (+ Murphy sign) was present or if the patient is focally painful in subxiphoid palpation then low-grade smoldering chronic pancreatitis should be suspected.

Free Abdomen

A cystic mesenteric lymph node was noted measuring 0.64 cm in width. This is likely owing to chronic lymphadenitis. Mildly enlarged mesenteric lymph nodes were noted measuring up to 1.0 cm x 0.8 cm.

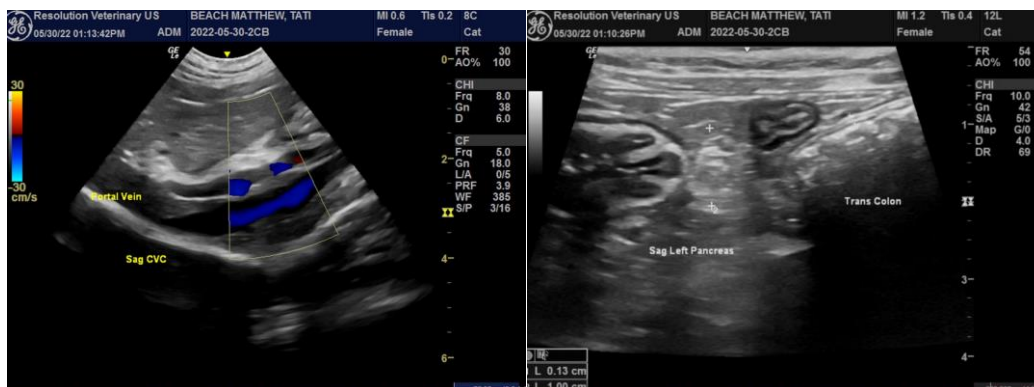ULTRASONOGRAPHIC FINDINGS

- Diffuse intestinal thickening with regional mesenteric and intestinal lymphadenopathy-inflammatory bowel with lymphadenitis likely, round cell neoplasia is possible. An ultrasound guided FNA of the most prominent mesenteric lymph node is recommended.

INTERPRETATION OF THE FINDINGS & FURTHER RECOMMENDATIONS

Full thickness intestinal and lymph node biopsies would be ideal. And FNA of the most prominent node would be the least invasive approach. A clinical trial of the following could be considered:

Recommend pain management when anorexic with **Buprenorphine** (0.01-0.02 mg/kg IM or SC), clinical trial of **Zithromax** (50 mg sid/cat x 10 days, 3 weeks if bartonella +), **Prednisolone** (0.5-2 mg/kg tapering over 1 week to minimal effective dose), and **B12 injections** if weight loss (Cyanobalaminine 250 mcg sub-q once-weekly x six weeks, then every other week for six weeks and then once-monthly, long-term if necessary), **novel-protein or hydrolyzed diet** (*Hydrolyzed diets have been shown to be more effective in dietary intolerance case management compared to hypoallergenic diets*) or the **magical Purina DM** (changing protein source is crucial and may need rotation every 6 months if clinical signs recur) Diet trials is a whatever works phenomenon. If vomiting becomes a persistent issue then endoscopy would be warranted and/or recheck sonogram to assess more emerging disease. One diet does not work for all patients so different trials may be necessary or protein source rotation every 6 months as new sensitivities develop.





PATIENT

Tati Beach

SPECIES

Feline

BREED

DMH

SEX

FS

AGE

9 yr

WEIGHT

4.3 kg

INTERPRETED BY

Eric Lindquist, DMV
DABVP, Cert. IVUSS

IMAGING PERFORMED BY

Dr. Belan

HOSPITAL NAME

Properties Animal
Clinic

REFERRING VET

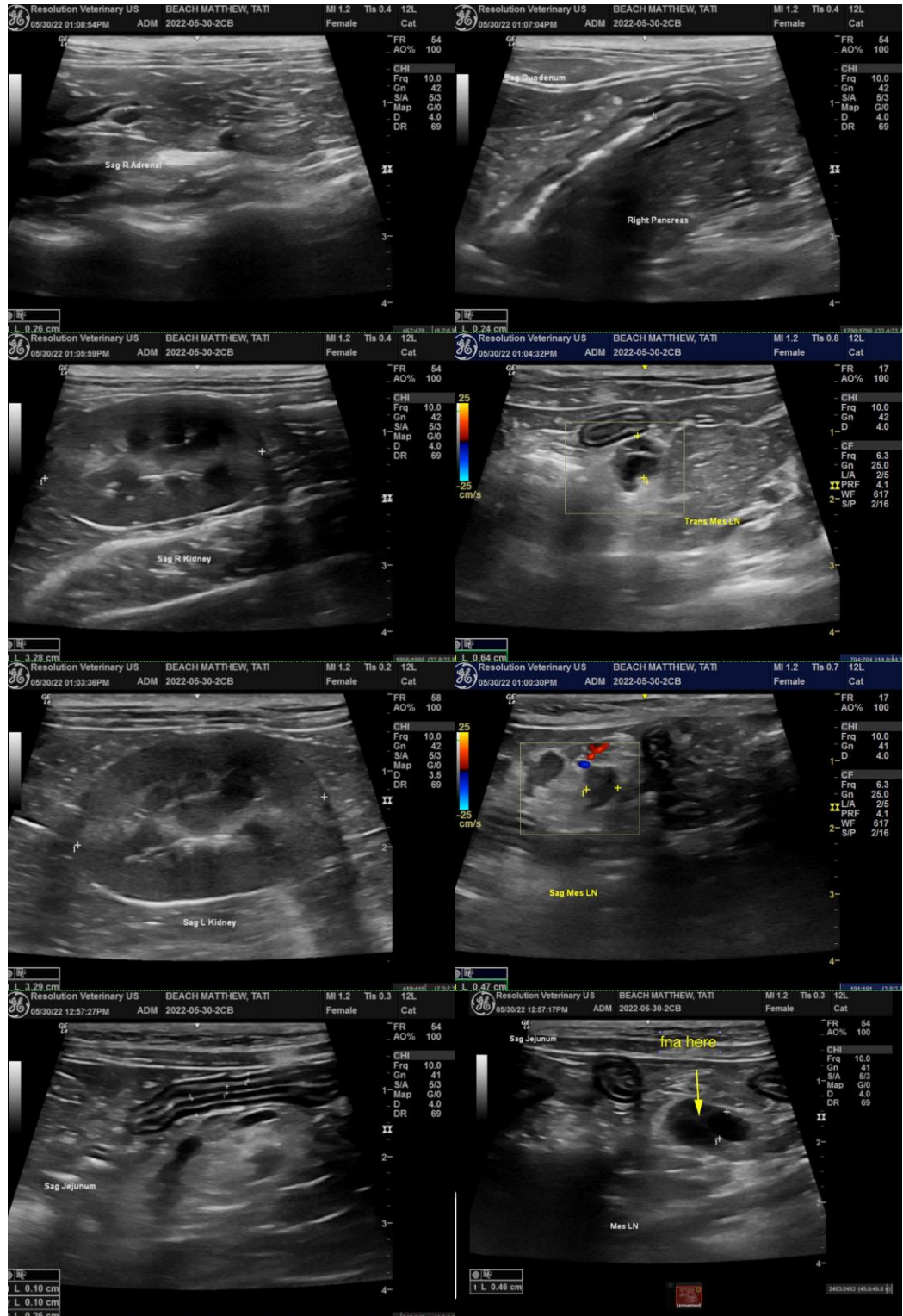
Dr. Costa

INVOICE

10694ag

DATE

05/30/2022





PATIENT

Tati Beach

SPECIES

Feline

BREED

DMH

SEX

FS

AGE

9 yr

WEIGHT

4.3 kg

INTERPRETED BY

Eric Lindquist, DMV
DABVP, Cert. IVUSS

**IMAGING
PERFORMED BY**

Dr. Belan

HOSPITAL NAME

Properties Animal
Clinic

REFERRING VET

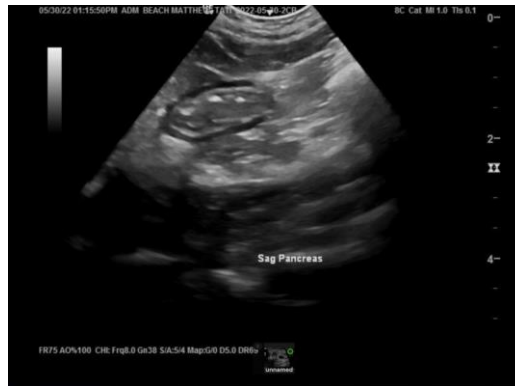Dr. Costa

INVOICE

10694ag

DATE

05/30/2022



The information and recommendations provided are based on the images presented by the referring veterinarian. No evaluation can be communicated regarding pathology that was not visible in the image/video clips provided.

Thank you for this referral. If the clinical or image interpretation does not parallel your findings or if I can be of any further assistance please contact me.

Eric Lindquist, DMV, DABVP, Cert. IVUSS, CEO of SonoPath.com
Eric.Lindquist@SonoPath.com