



**PATIENT**

Charlie Slania

**SPECIES**

Canine

**BREED**

Beagle X

**SEX**

Spayed Female

**AGE**

1

**WEIGHT**

37

**INTERPRETED BY**

Eric Lindquist, DMV

DABVP, Cert. IVUSS

**IMAGING PERFORMED BY**

Jenn

**HOSPITAL NAME**

Rockway AH

**REFERRING VET**

Dr. Maniar

**INVOICE**

47067

**DATE**

5/3/23

**PRESENTING CLINICAL SIGNS**

Recheck from yesterday had full stomach and grass density, dog had dinner but has been NPO since.

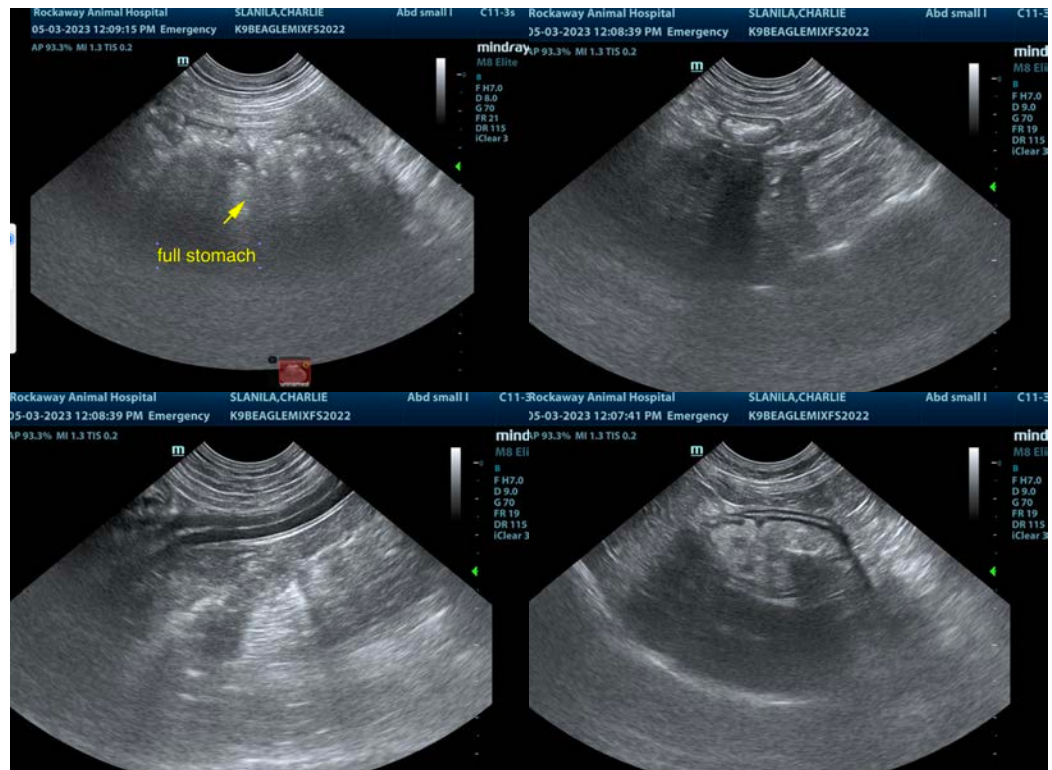
**LIMITED ULTRASONOGRAPHIC EXAMINATION**

**Gastrointestinal**

The stomach was overdistended with progressively shadowing material measuring up to 7.0 mm. Possible foreign matter mixed with chyme, carpeting, or similar material. The pylorus appeared patent. The small intestine was empty. The colon was essentially empty with only a minor amount of soft stool noted.

**INTERPRETATION OF THE FINDINGS & FURTHER RECOMMENDATIONS**

If the patient was completely NPO for 12-24 hours, then gastrotomy and gastric evacuation indicated. However, no overt cause of obstruction could be fine, as the pyloric outflow appeared to have soft chyme type material present. Given that the patient was fed, recommend full 24-hour NPO and recheck sonogram.



The information and recommendations provided are based on the images presented by the referring veterinarian/sonographer. No evaluation can be communicated regarding pathology that was not visible in the image/video clips provided.

Thank you for this referral. If the clinical or image interpretation does not parallel your findings or if I can be of any further assistance please contact me.

Eric Lindquist, DMV, DABVP, Cert. IVUSS, CEO of SonoPath.com

[info@SonoPath.com](mailto:info@SonoPath.com)