



PATIENT PRESENTING CLINICAL SIGNS

Bella Mainenti Globoid heart dorsal evaluation of tracheal at heart base collapsing trachea coughing more frequently
Current meds Clav Gaba Tramadol

SPECIES

Canine

Abnormal PE/Chem/CBC/UA Results: Increased BUN 35 Creat 0.4

BREED

Yorkie

ULTRASONOGRAPHIC EXAMINATION OF THE HEART

SEX

Spayed Female

CANINE CARDIAC PARAMETERS	MR VMAX (m/s)	TR VMAX (m/s)	LA/AO (Boon method)	LA/AO (Heart Base; Swe)	FS (%)	EF (%)	EPSS (cm)
NORMAL PARAMETER	4.5-5.5	<2.7	1.3	<1.6	28-40	40-100	<0.6
PATIENT			1.0	1.07			NM
CANINE CARDIAC PARAMETERS	HR (BPM)	AV VMAX (m/s)	PV MAX (m/s)	BODY WEIGHT (kg)	LA 2D short axis Base view (cm)	LVIDd Avg; 2D and m-mode short axis (cm)	LVIDs Avg; 2D and m-mode short axis (cm)
NORMAL PARAMETER	50-100	0.7-1.7	0.7-1.6	BELOW	BELOW	BELOW	BELOW
PATIENT			0.7		1.7	1.67	

AGE

16

WEIGHT

4

INTERPRETED BY

Eric Lindquist, DMV

DABVP, Cert. IVUSS

Cardiac Presentation

IMAGING PERFORMED BY

Jenn

HOSPITAL NAME

Rockaway AH

REFERRING VET

Dr. Maniar

INVOICE

47074

DATE

5/3/23

ULTRASONOGRAPHIC FINDINGS

- Mild cor pulmonale
- Trivial tricuspid insufficiency

INTERPRETATION OF THE FINDINGS & FURTHER RECOMMENDATIONS

No evidence of primary cardiac disease to be responsible for the clinical signs. All left sided chambers are normal. Changes were minor. Recommend primary respiratory protocol.



PATIENT

Bella Mainenti

SPECIES

Canine

BREED

Yorkie

SEX

Spayed Female

AGE

16

WEIGHT

4

INTERPRETED BY

Eric Lindquist, DMV

DABVP, Cert. IVUSS

IMAGING PERFORMED BY

Jenn

HOSPITAL NAME

Rockaway AH

REFERRING VET

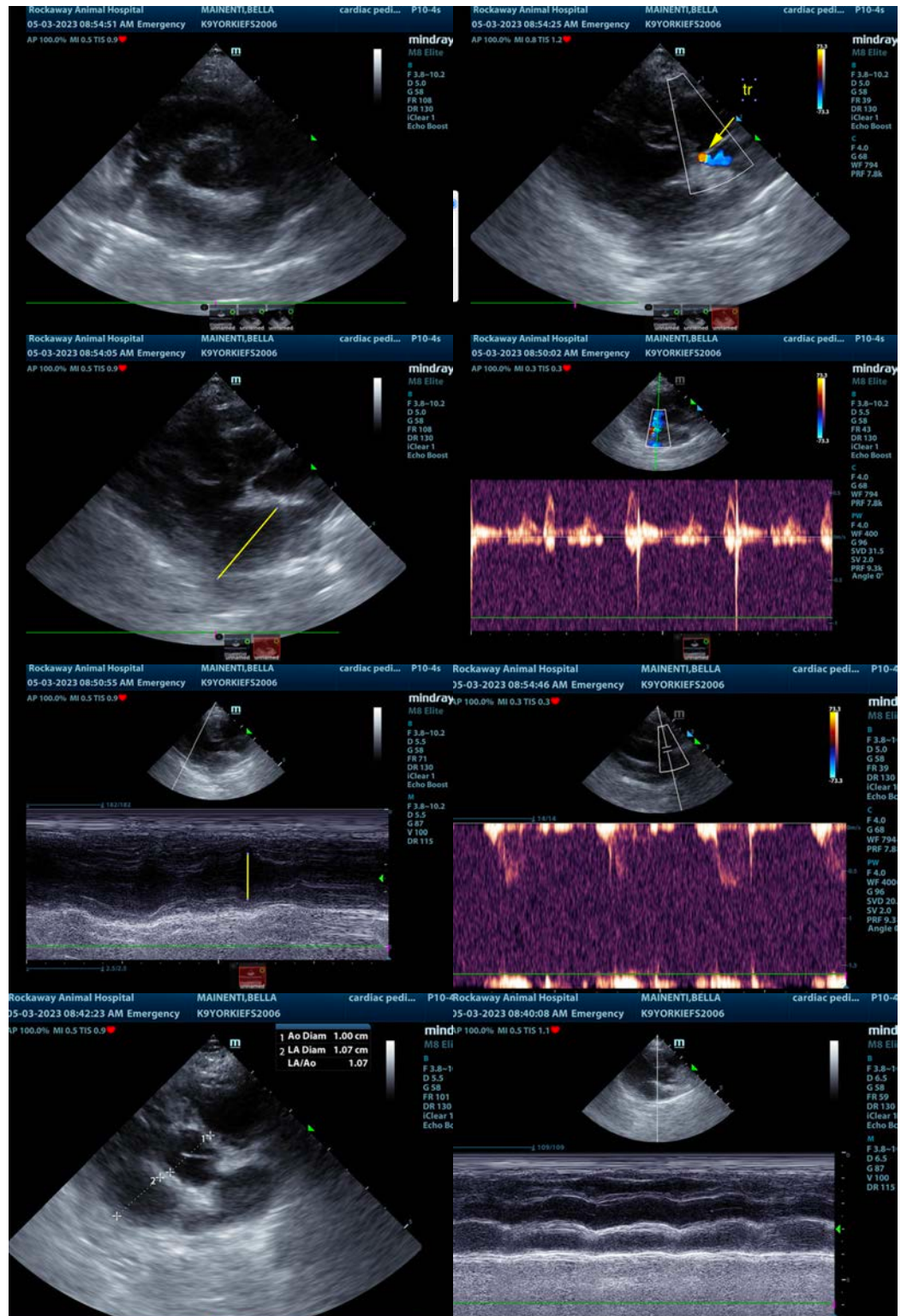
Dr. Maniar

INVOICE

47074

DATE

5/3/23





PATIENT

Bella Mainenti

The information and recommendations provided are based on the images presented by the referring veterinarian/sonographer. No evaluation can be communicated regarding pathology that was not visible in the image/video clips provided.

SPECIES

Canine

Thank you for this referral. If the clinical or image interpretation does not parallel your findings or if I can be of any further assistance please contact me.

BREED

Yorkie

Eric Lindquist, DMV, DABVP, Cert. IVUSS, CEO of SonoPath.com

info@SonoPath.com

SEX

Spayed Female

AGE

16

WEIGHT

4

INTERPRETED BY

Eric Lindquist, DMV

DABVP, Cert. IVUSS

IMAGING PERFORMED BY

Jenn

HOSPITAL NAME

Rockaway AH

REFERRING VET

Dr. Maniar

INVOICE

47074

DATE

5/3/23