

**DATE**

5/3/22

PATIENT

Tux Dasczynski

SPECIES

Feline

BREED

DSH

SEX

Neutered Male

AGE

4/1/05

WEIGHT

14.1 Pounds

INTERPRETED BYEric Lindquist, DMV
DABVP, Cert. IVUSS**IMAGING PERFORMED BY**

Rachel Brillhart RDMS

HOSPITAL NAMEAnimal Emergency
Hospital**REFERRING VET**

Dr. Thompson

INVOICE

37337

PRESENTING CLINICAL SIGNS

Tux is a 17 y/o MN DSH who was referred for continued care - 3-4-day history of anorexia, possible vomiting, hematuria - history of urinary issues, on prescription diet - 2.75 lb weight loss since 06/21 - RDVM Exam/dx summary: Dull, subdued. Partial retinal detachments, hemorrhage OU. Large, soft bladder--difficult to express. HCT17%, fleas and flea dirt, azotemia (73/2.9) hypocalcemia (6.9); hyperphosphatemia (8.6) - Xrays--R lat abdomen, thorax, V/D abdomen, thorax--Spondylosis L2-L3, Large bladder. No stones or mineral densities noted in kidneys, ureters or bladder. Poss increase density /"wispy" around kidneys Stomach and SI empty, gastric axis pushed cranially, stool throughout colon. - Thorax--heart appears small on both lateral and V/D, increased density L caudal lung fields noted on V/D, but not lateral - CBC pending at RDVM

Current Medications: Gabapentin, Buprenorphine.

Lab Results: Azotemia, pyuria, white cells 28/hpf, red cells >50/hpf, USG 1.015, SDMA 31

Date of Previous IntraPet Ultrasound: No previous.

Sedation: Not required to complete full diagnostic ultrasound.

Stat Report: Not requested.

ULTRASONOGRAPHIC EXAMINATION OF THE ABDOMEN**Urinary System**

The **urinary bladder**, trigone, and pelvic urethra presented normal thicknesses and normal tone. The ureters were not visible which is normal. No uroliths or sediment were visualized and anechoic urine was present. No evidence of inflammatory or neoplastic changes were noted. Ureteral papillae were normal.

The **kidneys** were bilaterally swollen and enlarged. The left kidney measured 5.12 cm with minor pelvic mineralization of 0.38 cm. Slight early subcapsular halo noted on the left kidney. The right kidney measured 5.05 cm.

Adrenal Glands

The regions of the **adrenal glands** were unremarkable.

Spleen

The **spleen** presented a smooth homogeneous parenchyma hyperechoic to liver and renal cortical parenchyma. The capsule was smooth without noticeable expansion or deviation from within the spleen or adjacent pathology. The splenic vasculature demonstrated normal volume without signs of congestion or thrombosis. No sonographic evidence of acute or chronic inflammatory, neoplastic, or infarctual changes were noted.

Liver

The **liver** revealed minor hyperechoic cystadenoma on the right cranial liver, adjacent to the diaphragm, measuring 1.74 cm x 1.3 cm. Anechoic cyst also noted in the liver measuring 1.96, adjacent to the cystadenoma type lesion. The remainder of the liver was unremarkable with minor increased portal markings and minor remodeling. The gallbladder was unremarkable.

Gastrointestinal

Examination of the **gastrointestinal tract** revealed a stomach and intestine free of stasis, of normal wall thickness, acceptable curvilinear mural detail, and peristaltic activity. Small and large intestine demonstrated normal luminal chyme and stool consistency respectively. No obstructive or overt infiltrative disease was noted. No associated abnormal lymphatic activity was noted.

Pancreas

The base and limbs of the **pancreas** were observed to be largely isoechoic to surrounding omental fat. Pancreatic duct and capsular contour were acceptably normal and parenchyma respected normal curvilinear patterns. No overt evidence of active inflammatory or neoplastic disease was noted.

Other

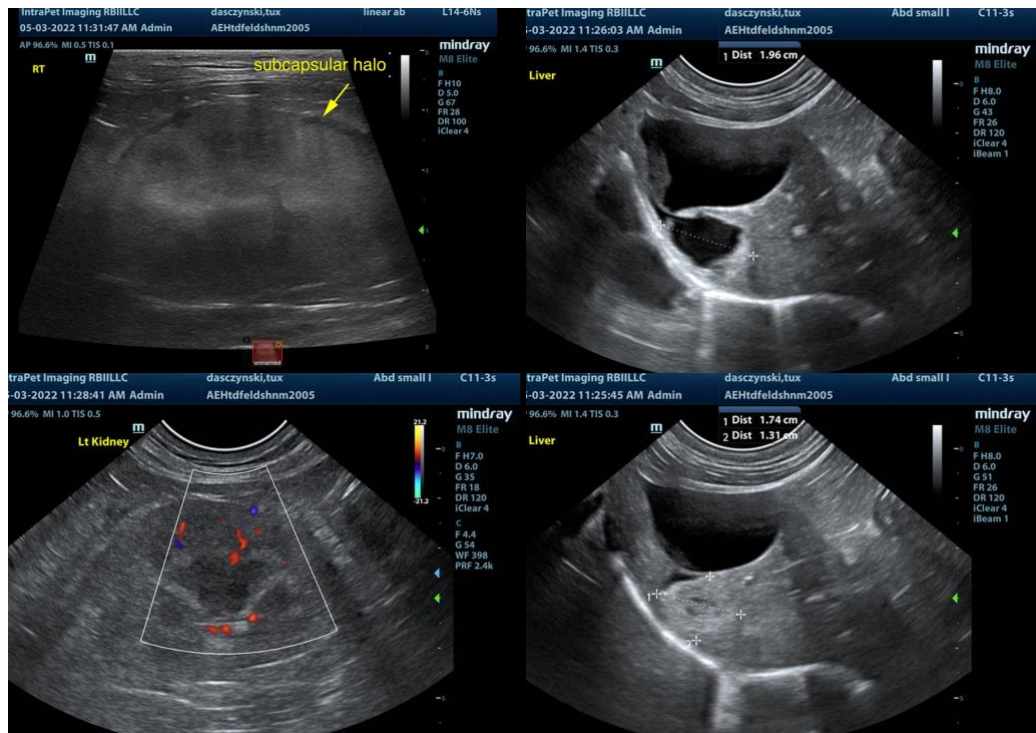
Ringdown artifacts noted in the lung field.

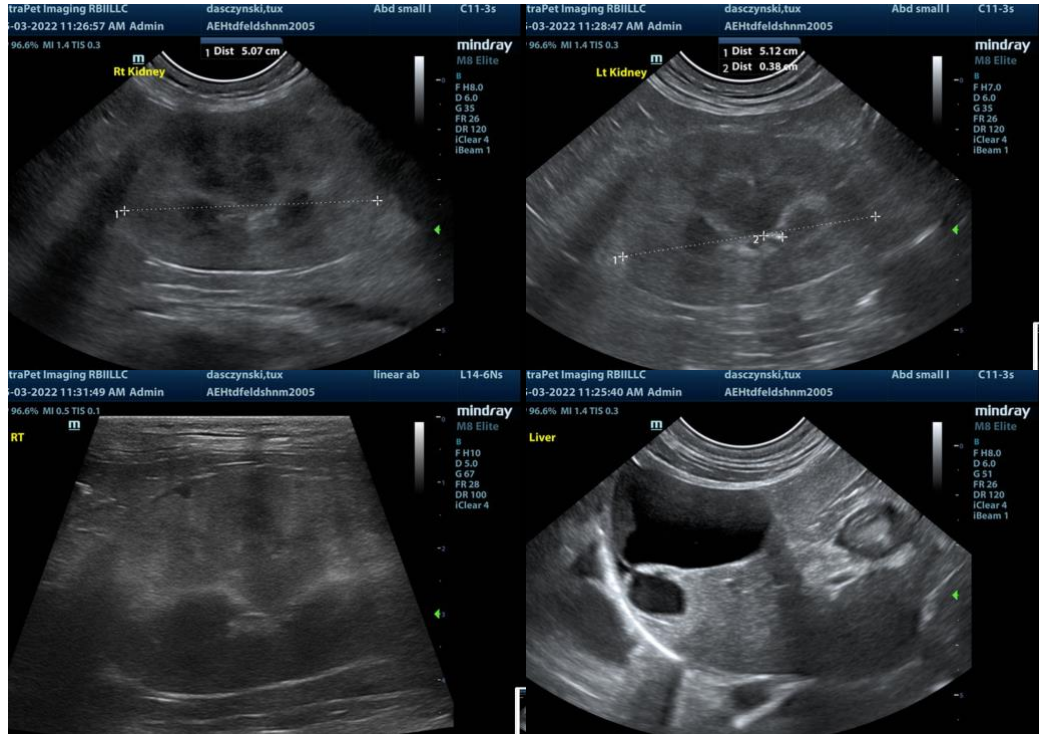
ULTRASONOGRAPHIC FINDINGS

- Bilateral renomegaly with ill-defined changes
- Early subcapsular halo – concern for emerging renal lymphoma
- Cystadenoma and hepatic cyst, not pathological
- Ringdown artifacts in lung field

INTERPRETATION OF THE FINDINGS & FURTHER RECOMMENDATIONS

Coagulation panel, ultrasound guided FNA of the kidneys recommended. Lymphoma, FIP, severe nephritis all possible, yet less likely. Chest radiographs recommended to assess for alveolar disease.





The information and recommendations provided are based on the images presented by the referring veterinarian/sonographer. No evaluation can be communicated regarding pathology that was not visible in the image/video clips provided.

Thank you for this referral. If the clinical or image interpretation does not parallel your findings or if I can be of any further assistance please contact me.

Eric Lindquist, DMV, DABVP, Cert. IVUSS, CEO of SonoPath.com
info@SonoPath.com