



PATIENT

Sammy CAH Diana

PRESENTING CLINICAL SIGNS

Patient is on pimobendan. Grade 3 left sided systolic murmur. Owner wants to pursue dental. CXR previously performed no record of previous echo.

SPECIES

Canine

ULTRASONOGRAPHIC EXAMINATION OF THE HEART

BREED

Lhasa Apso Mix

The **left atrial** size was mildly excessive, yet fairly well contained at 3.6 cm. **Mitral** valve insufficiency was noted at 6.2 m/sec. Prolapse of the anterior mitral valve leaflet with vegetative changes was noted. There was moderate filling of the left atrium noted. The **left ventricle** presented thicknesses with linear contour and was not dilated nor restricted. The **myocardium** presented normal echogenicity without subjective evidence of significant fibrotic or ischemic disease. **Contractility** of the ventricular walls was adequate and in normal range for this patient evidenced by the fractional shortening measurement and subjective evaluation of the different regions of the myocardium. The **left ventricular outflow** tract demonstrated normal laminar flow and subjective structural integrity. The **right atrium** and auricle revealed normal size, structure and content. No evidence of masses was noted. Minor **tricuspid** insufficiency was noted and measured 2.3 m/sec. The **right ventricle** was of normal size (1/3 diameter of LV), chordae structure, myocardial echogenicity and thickness. **Pulmonary outflow** tract assessment revealed normal valve structure, laminar flow, and diameter (approx.1:1 pa/ao ratio). No visible **pericardial** or free pleura fluid was noted. The cranial **mediastinum and pericardial and extra-cardiac** regions were free of masses in the visible window.

SEX

Neutered male

AGE

14 years

WEIGHT

22 lbs

INTERPRETED BY

Eric Lindquist, DMV
DABVP, Cert. IVUSS

CANINE CARDIAC PARAMETERS	MR VMAX (m/s)	TR VMAX (m/s)	LA/AO (Boon method)	LA/AO (Heart Base; Swe)	FS (%)	EF (%)	EPSS (cm)
NORMAL PARAMETER	4.5-5.5	<2.7	1.3	<1.3	28-40	40-100	<0.6
PATIENT	6.2		1.3	1.3	50	80	NM
CANINE CARDIAC PARAMETERS	HR (BPM)	AV VMAX (m/s)	PV MAX (m/s)	BODY WEIGHT	LA 2D short axis Base view (cm)	LVIDd Avg; 2D and m- mode short axis (cm)	LVIDs Avg; 2D and m-mode short axis (cm)
NORMAL PARAMETER	50-100	0.7-1.7	0.7-1.6				
PATIENT				22 lbs	3.6	2.9	

REFERRING VET

Dr. Petrone

ULTRASONOGRAPHIC FINDINGS

Compensated mitral insufficiency.

INVOICE

30120

Minimal left atrial enlargement, primarily in the LA max position, yet this is likely owing to chronic dilation. Other LA sizes were normal.

Contractility was adequate.

DATE

5/3/22



PATIENT

Sammy CAH Diana

SPECIES

Canine

BREED

Lhasa Apso Mix

SEX

Neutered male

AGE

14 years

WEIGHT

22 lbs

INTERPRETED BY

Eric Lindquist, DMV
DABVP, Cert. IVUS

IMAGING PERFORMED BY

Dr. Petrone

HOSPITAL NAME

Long Branch AH

REFERRING VET

Dr. Petrone

INVOICE

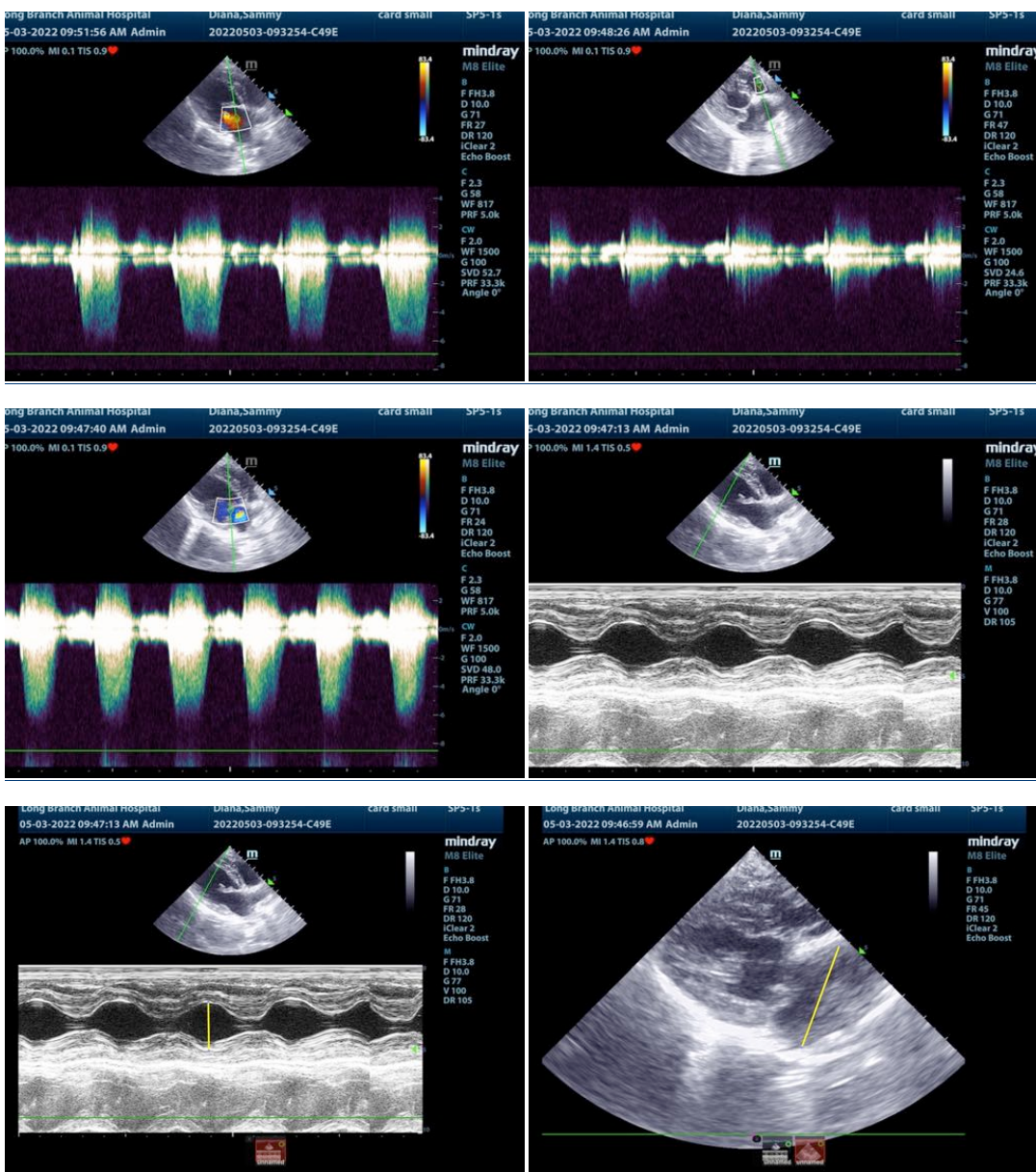
30120

DATE

5/3/22

INTERPRETATION OF THE FINDINGS & FURTHER RECOMMENDATIONS

There is minor anesthetic risk in this patient. I recommend minimal anesthetic time necessary to complete the procedure. Protocol such as the following would be recommended. Torbutrol premed, Propofol induction, and Isoflurane maintenance is recommended. Recheck echocardiogram is recommended in 6 months or earlier if murmur grade increases or clinical signs initiate.





PATIENT

Sammy CAH Diana

SPECIES

Canine

BREED

Lhasa Apso Mix

SEX

Neutered male

AGE

14 years

WEIGHT

22 lbs

INTERPRETED BY

Eric Lindquist, DMV
DABVP, Cert. IVUSS

IMAGING PERFORMED BY

Dr. Petrone

HOSPITAL NAME

Long Branch AH

REFERRING VET

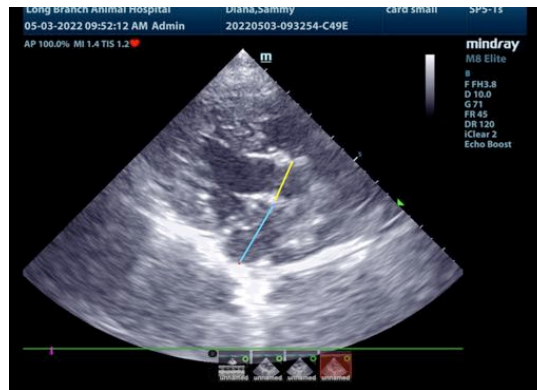
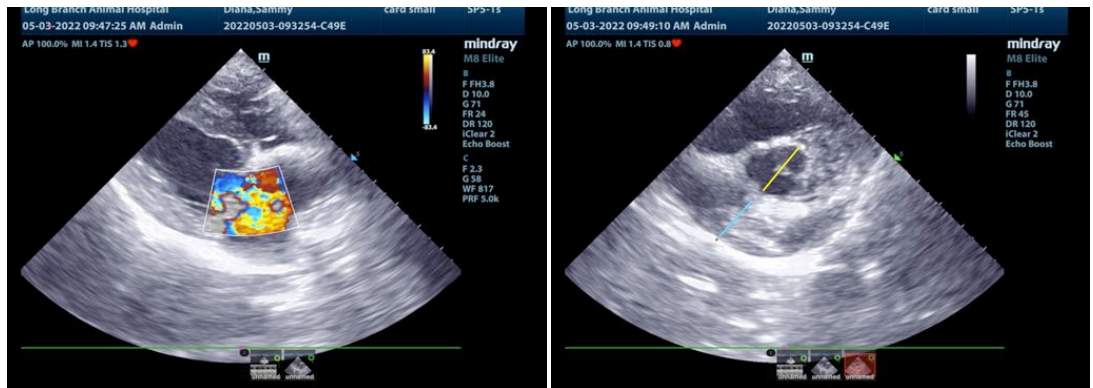
Dr. Petrone

INVOICE

30120

DATE

5/3/22



The information and recommendations provided are based on the images presented by the referring veterinarian/sonographer. No evaluation can be communicated regarding pathology that was not visible in the image/video clips provided.

Thank you for this referral. If the clinical or image interpretation does not parallel your findings or if I can be of any further assistance please contact me.

Eric Lindquist, DMV, DABVP, Cert. IVUSS, CEO of SonoPath.com
info@SonoPath.com