

**DATE**

5/3/22

PATIENT

Bruno Bui

SPECIES

Canine

BREED

Cockapoo

SEX

Neutered Male

AGE

4/23/19

WEIGHT

40.1 Pounds

INTERPRETED BYEric Lindquist, DMV
DABVP, Cert. IVUSS**IMAGING PERFORMED BY**

Rachel Brillhart RDMS

HOSPITAL NAMEAnimal Emergency
Hospital**REFERRING VET**

Dr. Martinoli

INVOICE

37342

PRESENTING CLINICAL SIGNS

Diagnosed with pancreatitis last October. Improved with treatment but owner thinks amylase and lipase levels sometimes hover around high end of normal or just above normal. Has been on RC Low Fat GI diet since last fall. PE: Very painful on abdominal palpation.

Current Medications: 05-01-2022 Buprenorphine 0.6mg/mL 0.6, Enrofloxacin, 180 mg IV BID, Cerenia SID, Hospitalized on IV fluids

Lab Results: Amylase - 1637, Lipase - 4643, SNAP cPL Abnormal.

Date of Previous IntraPet Ultrasound: No previous.

Sedation: IV Ace.

Stat Report: Not requested.

ULTRASONOGRAPHIC EXAMINATION OF THE ABDOMEN**Urinary System**

The **urinary bladder**, trigone, and pelvic urethra presented normal thicknesses and normal tone. The ureters were not visible which is normal. No uroliths or sediment were visualized and anechoic urine was present. No evidence of inflammatory or neoplastic changes were noted. Ureteral papillae were normal.

The **right kidney** revealed normal size and structure, corticomedullary definition and ratio for this age. The cortices presented largely uniform texture with normal echogenic relationship to liver and spleen. Medullary structure differed distinctly from the cortex. The capsules were acceptably uniform without significant irregularities. The right kidney measured 6.4 cm with slight pyelectasia noted at 0.41 cm.

The **left kidney** was slightly subnormal in size at 4.04 cm.

Adrenal Glands

Both **adrenal glands** were visualized and recognized as having normal shape, size, position and echogenicity for this breed. The phrenic vasculature, glandular echogenicity and detail were unremarkable. Capsule, cortex, and medullary definition were normal for this age patient. The left adrenal gland measured 2.42 cm x 0.63 cm at the caudal pole and 0.57 cm at the cranial pole. The right adrenal gland measured 2.33 cm x 0.71 cm at the caudal pole and 0.54 cm at the cranial pole.

Spleen

The **spleen** presented a smooth homogeneous parenchyma hyperechoic to liver and renal cortical parenchyma. The capsule was smooth without noticeable expansion or deviation from within the spleen or adjacent pathology. The splenic vasculature demonstrated normal volume without signs of congestion or thrombosis. No sonographic evidence of acute or chronic inflammatory, neoplastic, or infarctual changes were noted.

Liver

The **liver** images submitted revealed subjectively normal liver size, contour, and structure. Parenchymal echogenicity was naturally coarse and hypoechoic to the spleen. Vascular and biliary tracts were of normal volume with no evidence of congestion. The gallbladder presented acceptably thin walls with primarily anechoic content. The cystic and common bile ducts were normal. No pathological hepatic lymphadenopathy was evident. No overt structural evidence of inflammatory, infiltrative or regenerative pathology was evident.

Gastrointestinal

Examination of the **gastrointestinal tract** revealed a stomach and intestine free of stasis, of normal wall thickness, acceptable curvilinear mural detail, and peristaltic activity. Small and large intestine demonstrated normal luminal chyme and stool consistency respectively. No obstructive or overt infiltrative disease was noted. No associated abnormal lymphatic activity was noted.

Pancreas

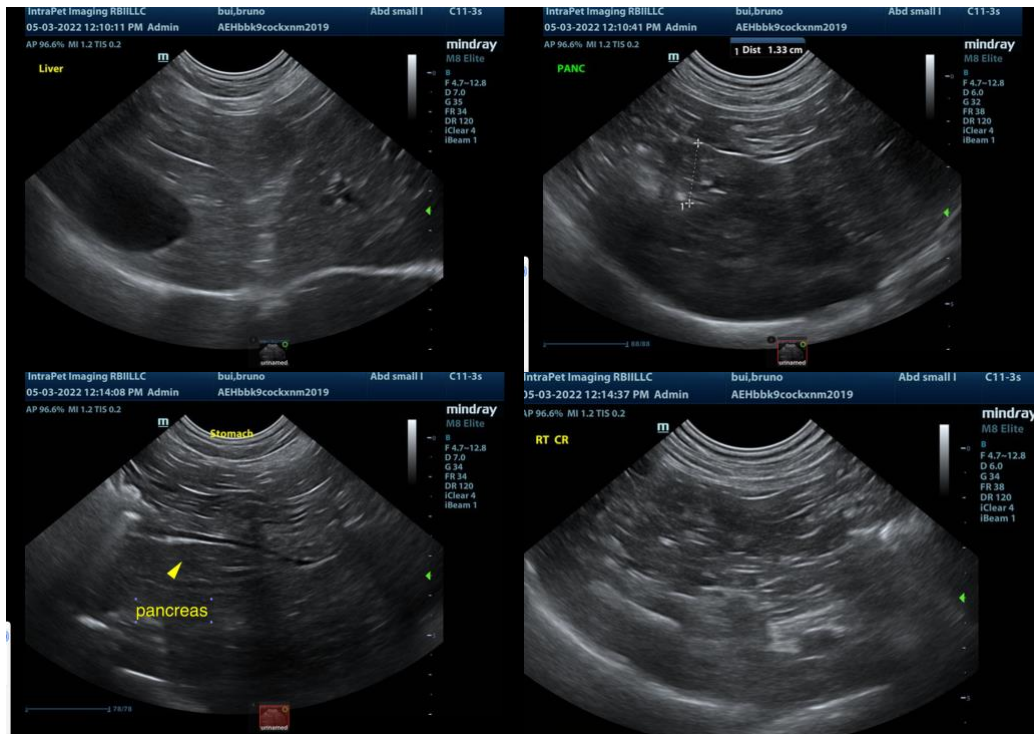
The base and limbs of the **pancreas** were observed to be largely isoechoic to surrounding omental fat. Pancreatic duct and capsular contour were acceptably normal and parenchyma respected normal curvilinear patterns. No overt evidence of active inflammatory or neoplastic disease was noted. The right pancreatic limb measured 1.33 cm.

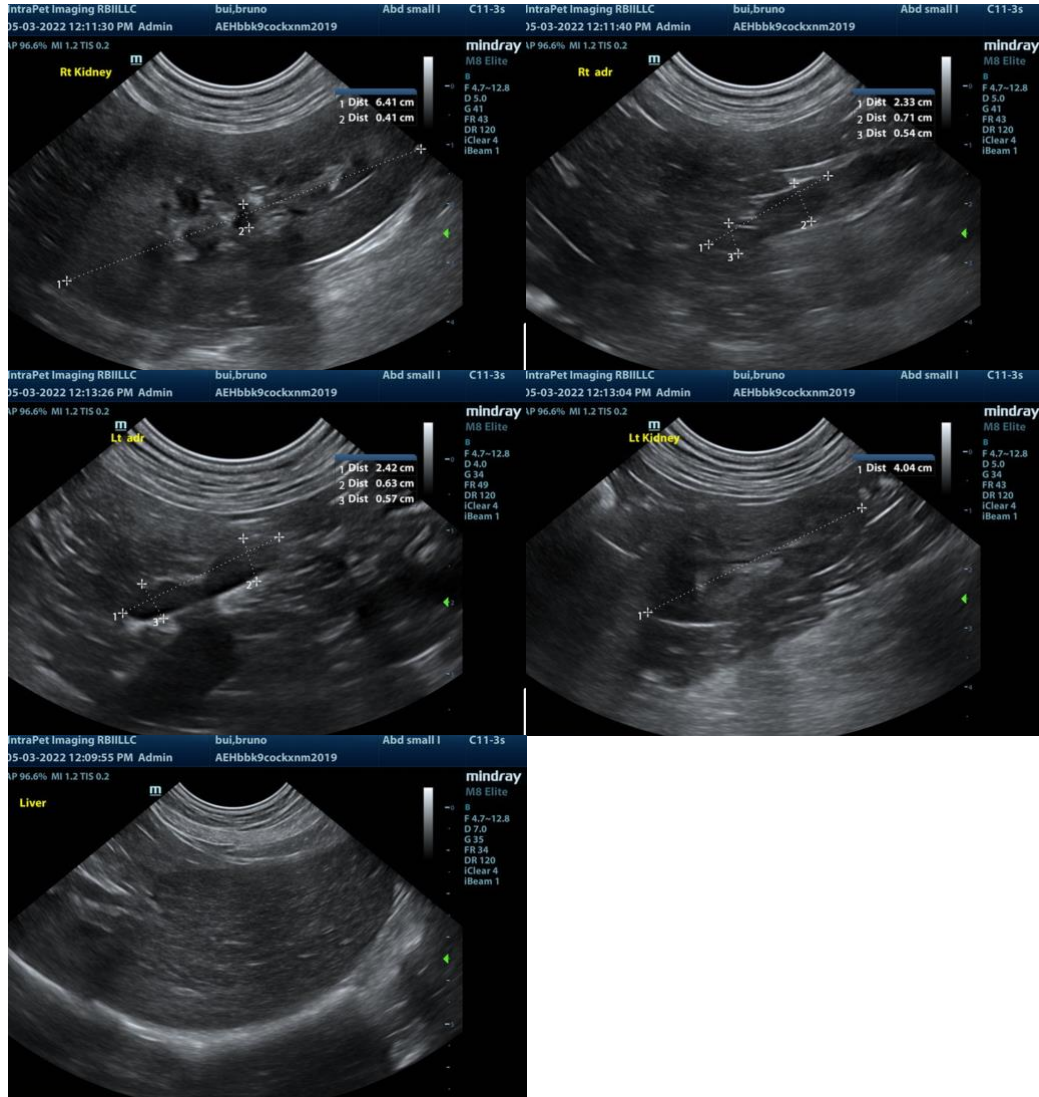
ULTRASONOGRAPHIC FINDINGS

- Structurally insignificant pancreatitis

INTERPRETATION OF THE FINDINGS & FURTHER RECOMMENDATIONS

Given the amylase/lipase elevation, either cross reactivity with GI enzymes or low-grade pancreatitis possible, yet structurally the pancreas appears unremarkable. Supportive care for the GI tract should prove effective in this patient. Resolving pancreatitis likely. Switch to hydrolyzed diet may be appropriate in this patient, given the history. Anti-parasitic protocol also indicated. No evidence of significant visceral disease.





The information and recommendations provided are based on the images presented by the referring veterinarian/sonographer. No evaluation can be communicated regarding pathology that was not visible in the image/video clips provided.

Thank you for this referral. If the clinical or image interpretation does not parallel your findings or if I can be of any further assistance please contact me.

Eric Lindquist, DMV, DABVP, Cert. IVUSS, CEO of SonoPath.com
info@SonoPath.com