



## PATIENT

Olive Rein

## SPECIES

Feline

## BREED

Domestic Shorthair

## SEX

Spayed female

## AGE

4 years

## WEIGHT

11.5 lbs

## INTERPRETED BY

Eric Lindquist, DMV  
DABVP, Cert. IVUSS

## IMAGING PERFORMED BY

Kathleen Laux

## HOSPITAL NAME

Rondout Valley VA

## REFERRING VET

Dr. Laux

## INVOICE

78128

## DATE

5/29/26

## PRESENTING CLINICAL SIGNS

History: -recheck GB/liver US after course of baytril and clindamycin.

## ULTRASONOGRAPHIC EXAMINATION

### Liver

The **liver** revealed slight coarse architecture. The gallbladder wall was slightly echogenic, yet the edema has resolved.

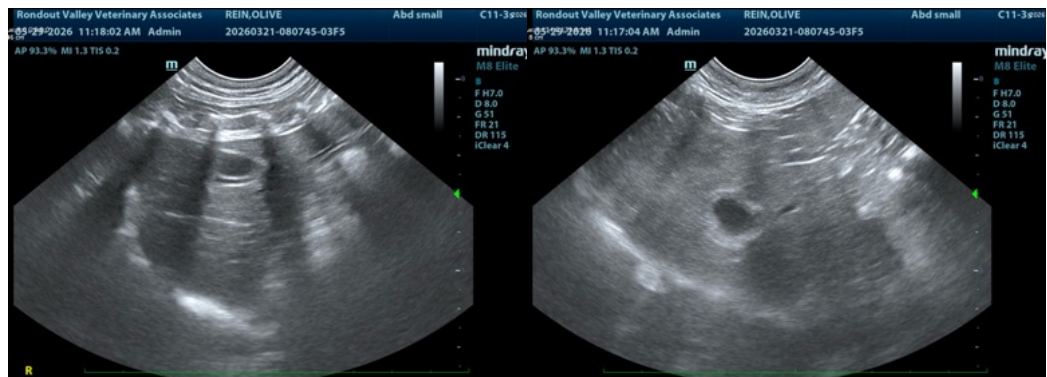
## ULTRASONOGRAPHIC FINDINGS

Slight residual echogenic gallbladder wall thickening.

Slight hepatic remodeling.

## INTERPRETATION OF THE FINDINGS & FURTHER RECOMMENDATIONS

Management should be based on any liver enzyme elevations. There was no evidence of significant disease. The liver appears to be stable. Management is recommended to be based on liver enzyme elevations.



The information and recommendations provided are based on the images presented by the referring veterinarian/sonographer. No evaluation can be communicated regarding pathology that was not visible in the image/video clips provided.

Thank you for this referral. If the clinical or image interpretation does not parallel your findings or if I can be of any further assistance please contact me.

Eric Lindquist, DMV, DABVP (CFM), Cert. IVUSS, CEO of SonoPath.com

[info@SonoPath.com](mailto:info@SonoPath.com)