



PATIENT

Daisy Carmelo

SPECIES

Canine

BREED

German Shepherd

SEX

Spayed Female

AGE

1 Year

WEIGHT

30 kg

INTERPRETED BY

Eric Lindquist, DMV,
DABVP(CFM), Cert.
IVUSS

IMAGING PERFORMED BY

Dr. Michael Schacher

HOSPITAL NAME

Emergency
Veterinarians of Idaho
LLC

REFERRING VET

Dr. Juli Sorenson

INVOICE

16586

DATE

05/29/26

PRESENTING CLINICAL SIGNS

HCT 80% on intake, no GI signs, neurologically abnormal on intake

Abnormal PE/Chem/CBC/UA Results: HCT 80% only abnormality.

ULTRASONOGRAPHIC EXAMINATION OF THE ABDOMEN

Urinary System

The **urinary bladder**, trigone, and pelvic urethra to a depth of 2.0 cm presented normal thicknesses and normal tone. The ureters were not visible which is normal. No uroliths or sediment were visualized, and anechoic urine was present. No evidence of inflammatory or neoplastic changes were noted. Ureteral papillae were normal.

The **kidneys** revealed normal size and structure, corticomedullary definition and ratio for this age. The cortices presented largely uniform texture with normal echogenic relationship to liver and spleen. Medullary structure differed distinctly from the cortex and no evidence of pelvic dilation was present. The capsules were acceptably uniform without significant irregularities. The left kidney measured 6.6 cm in length. The right kidney measured 8.3 cm in length.

Adrenal Glands

The **left adrenal gland** was visualized and recognized as having normal shape, size, position and echogenicity for this breed. The phrenic vasculature, glandular echogenicity and detail were unremarkable. Capsule, cortex, and medullary definition were normal for this age patient. The left adrenal gland measured 0.8 cm width.

The region of the **right adrenal gland** was imaged without evident pathology.

Spleen

The **spleen** presented mildly enlarged with swollen contour. Splenic width reached 4.0 cm. No evidence of thrombosis. The spleen was folded upon itself cranially.

Liver

The **liver** images submitted revealed subjectively normal liver size, contour, and structure. Parenchymal echogenicity was naturally coarse and hypoechoic to the spleen. Vascular and biliary tracts were of normal volume with no evidence of congestion. The gallbladder presented acceptably thin walls with primarily anechoic content. The cystic and common bile ducts were normal. No pathological hepatic lymphadenopathy was evident. No overt structural evidence of inflammatory, infiltrative or regenerative pathology was evident.

Gastrointestinal

Examination of the **gastrointestinal tract** revealed a stomach and intestine free of stasis, of normal wall thickness, acceptable curvilinear mural detail, and peristaltic activity. Small and large intestine demonstrated normal luminal chyme and stool consistency respectively. No obstructive or overt infiltrative disease was noted. No associated abnormal lymphatic activity was noted.

Pancreas



PATIENT

Daisy Carmelo

SPECIES

Canine

BREED

German Shepherd

SEX

Spayed Female

AGE

1 Year

WEIGHT

30 kg

INTERPRETED BY

Eric Lindquist, DMV,
DABVP(CFM), Cert.
IVUSS

IMAGING PERFORMED BY

Dr. Michael Schacher

HOSPITAL NAME

Emergency Veterinarians of Idaho LLC

REFERRING VET

Dr. Juli Sorenson

INVOICE

16586

DATE

05/29/26

The base and limbs of the **pancreas** were observed to be largely isoechoic to surrounding omental fat. Pancreatic duct and capsular contour were acceptably normal and parenchyma respected normal curvilinear patterns. No overt evidence of active inflammatory or neoplastic disease was noted.

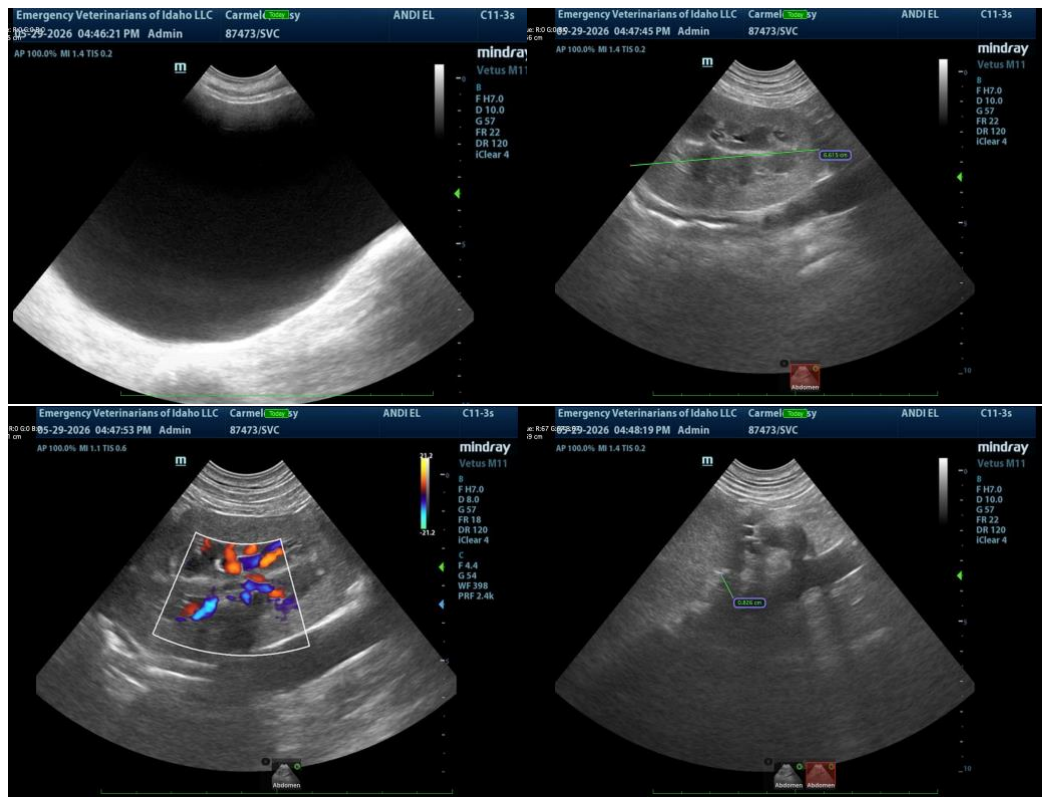
ULTRASONOGRAPHIC FINDINGS

- Splenomegaly- nonspecific hyperplasia versus round cell neoplasia or hematopoietic neoplasia are all possible.

INTERPRETATION OF THE FINDINGS & FURTHER RECOMMENDATIONS

FNA of the spleen is indicated. CBC path review +/- bone marrow aspirate is warranted to assess for hemato-proliferative disease. Sampling is recommended to rule out underlying neoplasia versus hyperplasia. Prognosis is guarded.

German Shepherds typically as a breed have enlarged spleens, however, this subjectively appears to be exaggeratedly enlarged. The splenic presentation is the only morphological abnormality in this patient at this time.





PATIENT

Daisy Carmelo

SPECIES

Canine

BREED

German Shepherd

SEX

Spayed Female

AGE

1 Year

WEIGHT

30 kg

INTERPRETED BY

Eric Lindquist, DMV,
DABVP(CFM), Cert.
IVUSS

**IMAGING
PERFORMED BY**

Dr. Michael Schacher

HOSPITAL NAME

Emergency
Veterinarians of Idaho
LLC

REFERRING VET

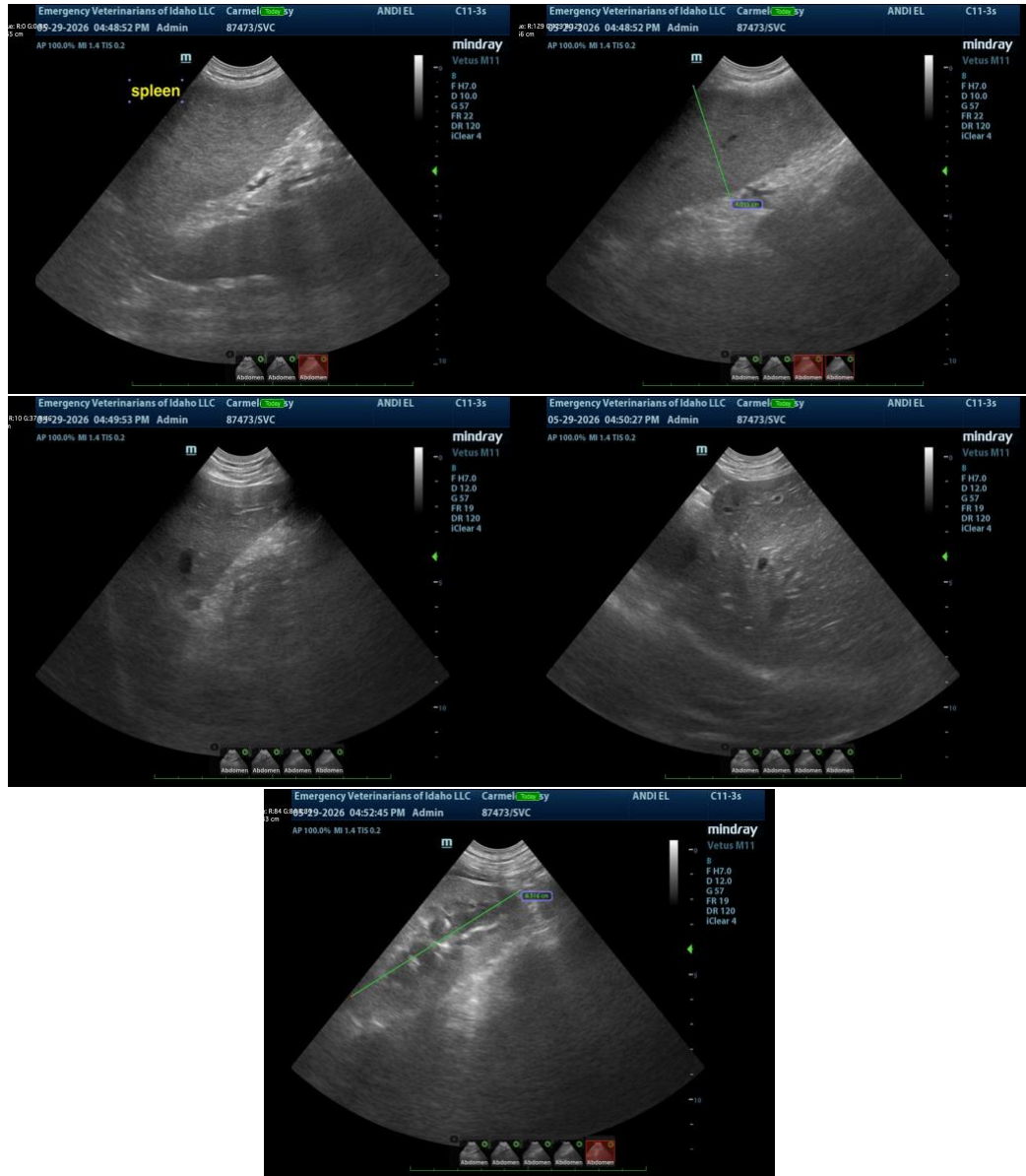
Dr. Juli Sorenson

INVOICE

16586

DATE

05/29/26



The information and recommendations provided are based on the images presented by the referring veterinarian/sonographer. No evaluation can be communicated regarding pathology that was not visible in the image/video clips provided.

Thank you for this referral. If the clinical or image interpretation does not parallel your findings or if I can be of any further assistance, please contact me.

Eric Lindquist, DMV, DABVP(CFM), Cert. IVUSS,

CEO, Owner, Founder -- SonoPath.com

info@SonoPath.com



PATIENT

Daisy Carmelo

SPECIES

Canine

BREED

German Shepherd

SEX

Spayed Female

AGE

1 Year

WEIGHT

30 kg

INTERPRETED BY

Eric Lindquist, DMV,
DABVP(CFM), Cert.
IVUSS

IMAGING PERFORMED BY

Dr. Michael Schacher

HOSPITAL NAME

Emergency
Veterinarians of Idaho
LLC

REFERRING VET

Dr. Juli Sorenson

INVOICE

16586

DATE

05/29/26