



PATIENT

Chisum Sensenbrenner

SPECIES

Canine

BREED

Labrador Retriever

SEX

Male

AGE

5 years

WEIGHT

65 lbs

INTERPRETED BY

Eric Lindquist, DMV
DABVP, Cert. IVUSS

IMAGING PERFORMED BY

MEW

HOSPITAL NAME

Weddington AH

REFERRING VET

Dr. Walker

INVOICE

78132

DATE

5/29/26

PRESENTING CLINICAL SIGNS

History: 5.5 year old MI lab presented a few days ago for 2 weeks of decreased appetite and history of running off and possibly eating something. P has had 10 lbs of weight loss since Nov. P is an outdoor working dog and is kenneled. No v/d/c/s, just not as interested in dry food. Concerned for cranial abdominal mass. P is vaccinated for leptospirosis and current on HW/flea/tick. Concerned for neoplasia vs chronic FB/toxin.

5/27/26: CBC: no remarkable abnormalities Chemistry: mildly elevated AST (132), markedly elevated ALT (1,210), markedly elevated ALP (3702), markedly elevated GGT (47), mild hyperbilirubinemia (0.7), mild hypercholesterolemia (409) T4: 0.5 - euthyroid sick U/A: 1.053 USG, 2+ protein, 3+ bilirubin, 11-20 wbc, 11-20 squamous

ULTRASONOGRAPHIC EXAMINATION OF THE ABDOMEN

Urinary System

The **bladder** in this patient was mildly thickened with slight echogenic mural changes. No calculi or masses were noted. Slight micropolypoid changes were noted. This is a frequent finding in older animals and may be linked to a history of chronic urinary tract infection or active urinary tract infection.

Urinalysis would be recommended with culture if any evidence of inflammatory sediment is present. The region of the trigone and visible pelvic urethra were normal.

The **kidneys** revealed normal size and structure, corticomedullary definition and ratio for this age. The cortices presented largely uniform texture with normal echogenic relationship to liver and spleen. Medullary structure differed distinctly from the cortex and no evidence of pelvic dilation was present. The capsules were acceptably uniform without significant irregularities. The left kidney measured 6.8 cm. The right kidney measured 6.0 cm.

The **prostate** was uniformly enlarged with lobar swelling appeared to impinge upon the urethra and mildly deviate the descending colon. The prostatic tissue was hyperechoic containing focal areas of decreased echogenicity. These changes are suggestive of either chronic inflammatory episodes, benign cystic pathology or both. Underlying neoplasia cannot be completely ruled-out but is lower on the differential list. This presentation is most consistent with benign prostatic hyperplasia with possible active prostatitis. Neutering or off-label Finasteride (Propecia) (0.1-0.5 mg/kg Sid) treatment is indicated +/- FNA or prostatic wash cytology and culture. The prostate measured 3.0 cm.

The iliac lymph nodes are enlarged, hypoechoic and irregular. The largest lymph node measured 4.5 x 2.2 cm.

Adrenal Glands

Both **adrenal glands** were visualized and recognized as having normal shape, size, position and echogenicity for this breed. The phrenic vasculature, glandular echogenicity and detail were unremarkable. Capsule, cortex, and medullary definition were normal for this age patient. The left adrenal gland measured 0.5 cm. The right adrenal gland measured 0.95 cm at the cranial pole and 0.85 cm at the caudal pole.



PATIENT

Spleen

The **spleen** was enlarged with subtle micronodular changes.

Liver

The **liver** was enlarged with swollen irregular contour with slightly increased portal markings. There was no evidence of post hepatic obstruction. The hepatic lymph nodes were enlarged, rounded and hypoechoic. The gallbladder and common bile duct were unremarkable.

Gastrointestinal

Examination of the **gastrointestinal tract** revealed a stomach and intestine free of stasis, of normal wall thickness, acceptable curvilinear mural detail, and peristaltic activity. Small and large intestine demonstrated normal luminal chyme and stool consistency respectively. No obstructive or overt infiltrative disease was noted. No associated abnormal lymphatic activity was noted.

Pancreas

The base and limbs of the **pancreas** were observed to be largely isoechoic to surrounding omental fat. Pancreatic duct and capsular contour were acceptably normal and parenchyma respected normal curvilinear patterns. No overt evidence of active inflammatory or neoplastic disease was noted.

Free Abdomen

A moderate amount of ascites was noted.

ULTRASONOGRAPHIC FINDINGS

Multi-centric infiltrative pattern involving the lymph nodes, spleen and liver with secondary ascites.

INTERPRETATION OF THE FINDINGS & FURTHER RECOMMENDATIONS

FNA of the spleen, liver and lymph nodes should prove effective on a definitive diagnosis.

Round cell neoplasia is suspected.

Chisum Sensenbrenner

SPECIES

Canine

BREED

Labrador Retriever

SEX

Male

AGE

5 years

WEIGHT

65 lbs

INTERPRETED BY

Eric Lindquist, DMV
DABVP, Cert. IVUSS

IMAGING PERFORMED BY

MEW

HOSPITAL NAME

Weddington AH

REFERRING VET

Dr. Walker

INVOICE

78132

DATE

5/29/26



PATIENT

Chisum Sensenbrenner

SPECIES

Canine

BREED

Labrador Retriever

SEX

Male

AGE

5 years

WEIGHT

65 lbs

INTERPRETED BY

Eric Lindquist, DMV
DABVP, Cert. IVUSS

IMAGING PERFORMED BY

MEW

HOSPITAL NAME

Weddington AH

REFERRING VET

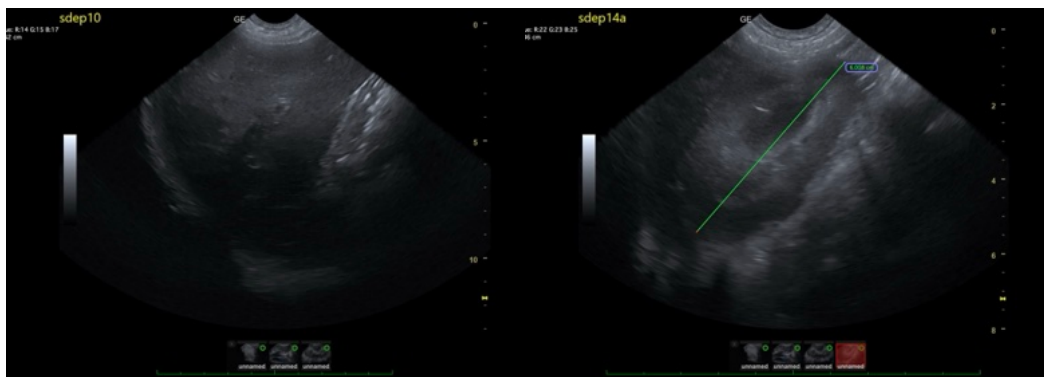
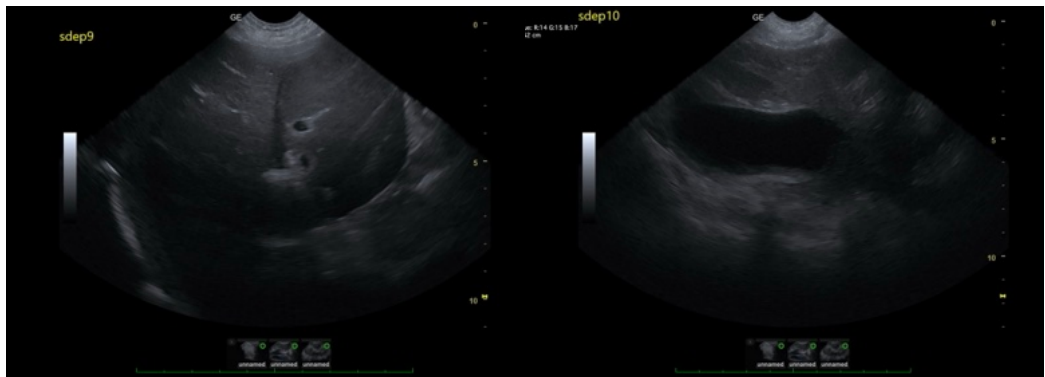
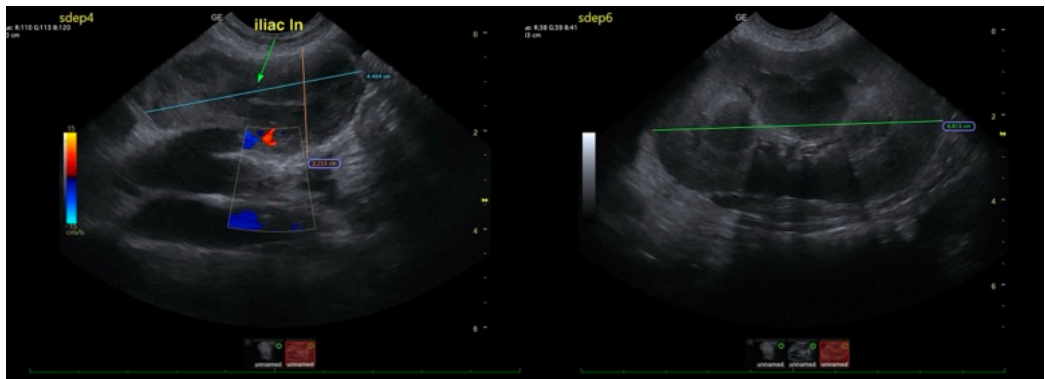
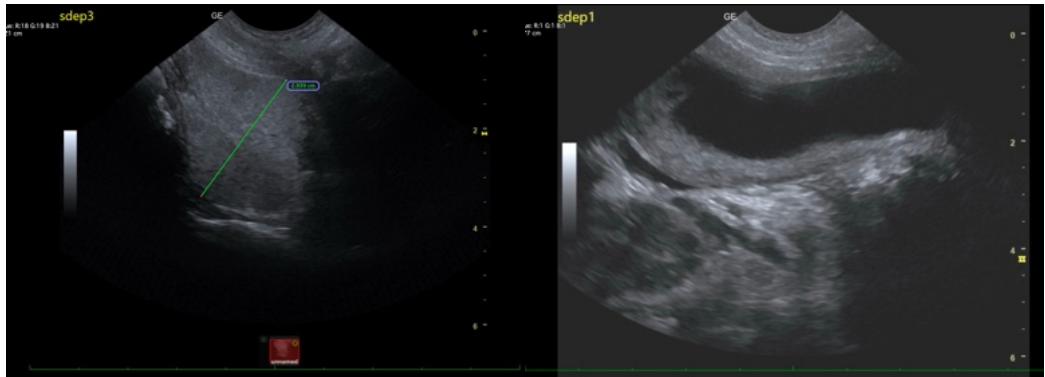
Dr. Walker

INVOICE

78132

DATE

5/29/26





PATIENT

Chisum Sensenbrenner

SPECIES

Canine

BREED

Labrador Retriever

SEX

Male

AGE

5 years

WEIGHT

65 lbs

INTERPRETED BY

Eric Lindquist, DMV
DABVP, Cert. IVUSS

IMAGING PERFORMED BY

MEW

HOSPITAL NAME

Weddington AH

REFERRING VET

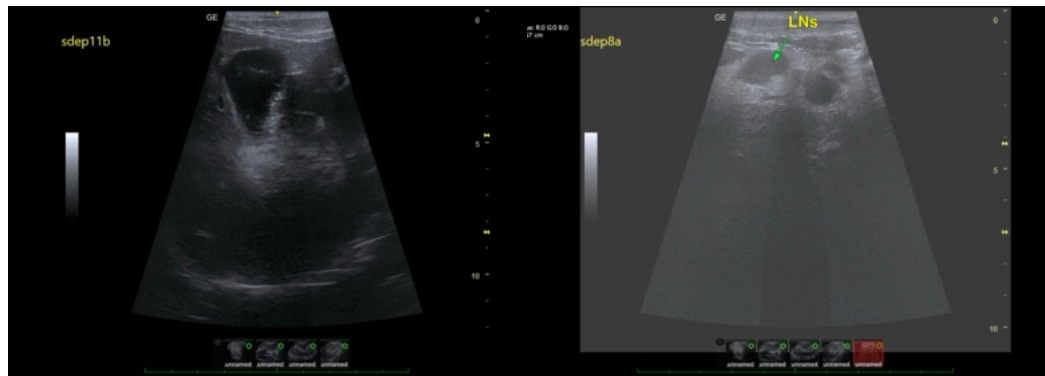
Dr. Walker

INVOICE

78132

DATE

5/29/26



The information and recommendations provided are based on the images presented by the referring veterinarian/sonographer. No evaluation can be communicated regarding pathology that was not visible in the image/video clips provided.

Thank you for this referral. If the clinical or image interpretation does not parallel your findings or if I can be of any further assistance please contact me.

Eric Lindquist, DMV, DABVP (CFM), Cert. IVUSS, CEO of SonoPath.com

info@SonoPath.com