



**PATIENT**

Teddy Moran

**SPECIES**

Canine

**BREED**

Golden Retriever x

**SEX**

Neutered Male

**AGE**

13 Years 5 Months

**WEIGHT**

31.1 lbs

**INTERPRETED BY**

Eric Lindquist, DMV,  
DABVP (CFM), Cert.  
IUUSS

**IMAGING PERFORMED BY**

Shari Reffi, CVT

**HOSPITAL NAME**

Hanover View Animal  
Hospital

**REFERRING VET**

Dr. Ervin

**INVOICE**

75527

**DATE**

5/28/26

**PRESENTING CLINICAL SIGNS**

Recheck post sx "to ensure all pathology was removed that had been previously seen on U/S" (prev report attached). Current Medications: Gabapentin 100mg (2 cap 6:20a); Trazodone 100mg (1/2 tab 6:20a); Amantadine 100mg (1/2 tab q12); Carprofen 75mg (1/2 tab q12)

Abnormal PE/Chem/CBC/UA Results: Previously elevated Ca

**ULTRASONOGRAPHIC EXAMINATION OF THE THYROID**

The right thyroid lobe measured approximately 5.0 mm in width. Normal parathyroid noted at 2.0 mm. No evidence of pathology. The salivary gland, trachea, and carotid were all normal. Regional vasculature was normal.

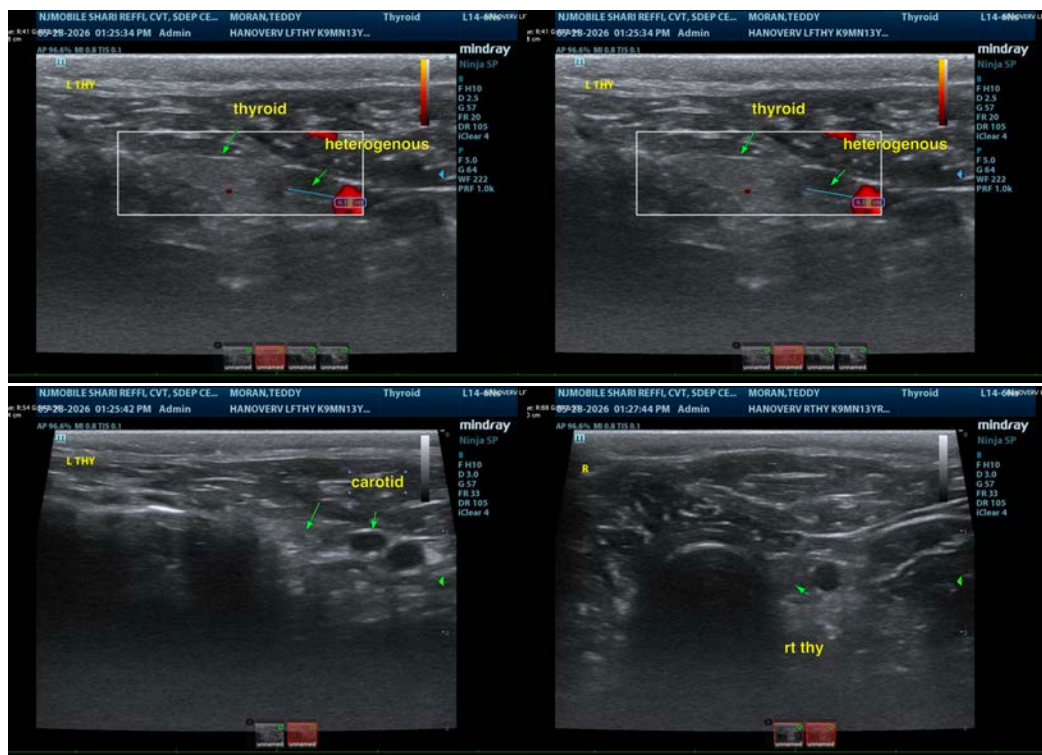
The caudal aspect of the left thyroid lobe revealed a slight heterogeneous, non-disruptive change measuring 3.7 cm, yet this is non-expansive and non-disruptive and likely a simple age related change.

**ULTRASONOGRAPHIC FINDINGS**

- Minor heterogeneous changes to the caudal aspect of the left thyroid lobe, otherwise unremarkable. thyroid and visible parathyroids.

**INTERPRETATION OF THE FINDINGS & FURTHER RECOMMENDATIONS**

No residual pathology. If primary hypercalcemia is persistently an issue, then recheck sonogram in one month.





**PATIENT**

Teddy Moran

**SPECIES**

Canine

**BREED**

Golden Retriever x

**SEX**

Neutered Male

**AGE**

13 Years 5 Months

**WEIGHT**

31.1 lbs

**INTERPRETED BY**

Eric Lindquist, DMV,  
 DABVP (CFM), Cert.  
 IVUSS

**IMAGING PERFORMED BY**

Shari Reffi, CVT

**HOSPITAL NAME**

Hanover View Animal  
 Hospital

**REFERRING VET**

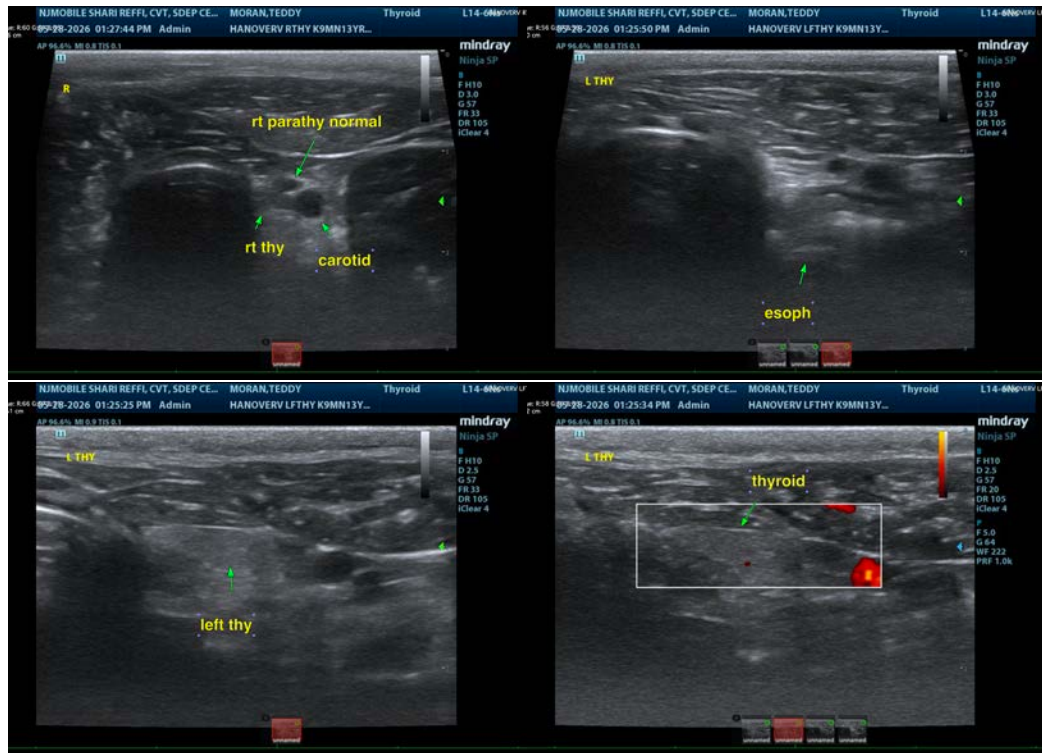
Dr. Ervin

**INVOICE**

75527

**DATE**

5/28/26



The information and recommendations provided are based on the images presented by the referring veterinarian/sonographer. No evaluation can be communicated regarding pathology that was not visible in the image/video clips provided.

Thank you for this referral. If the clinical or image interpretation does not parallel your findings or if I can be of any further assistance please contact me.

**Eric Lindquist**, DMV, DABVP(CFM), Cert. IVUSS,  
 CEO, Owner, Founder -- SonoPath.com  
[info@SonoPath.com](mailto:info@SonoPath.com)