

**PATIENT**

Reggie Lysiak

**SPECIES**

Canine

**BREED**

Maltese Mix

**SEX**

Neutered Male

**AGE**

13

**WEIGHT**

14.5

**INTERPRETED BY**

Eric Lindquist, DMV,  
DABVP(CFM), Cert.  
IVUSS

**IMAGING PERFORMED BY**

Jenn

**HOSPITAL NAME**

Rockaway Animal  
Hospital

**REFERRING VET**

Dr. Brooks

**INVOICE**

16547

**DATE**

05/28/26

**PRESENTING CLINICAL SIGNS**

Presented for dental found Grade 2/6 HM

Abnormal PE/Chem/CBC/UA Results: BUN 32

**ULTRASONOGRAPHIC EXAMINATION OF THE HEART**

CANINE CARDIAC PARAMETERS	MR VMAX (m/s)	TR VMAX (m/s)	LA/AO (M-Mode)	LA/AO (Heart Base; Swe)	FS (%)	EF (%)	EPSS (cm)
NORMAL PARAMETER	4.5-5.5	<2.7	1.3	Up to 1.6	28-40	40-100	<0.6
PATIENT	NM	NM	1.2	1.1	40	80	0.1
CANINE CARDIAC PARAMETERS	HR (BPM)	AV VMAX (m/s)	PV MAX (m/s)	BODY WEIGHT	LAD LA MAX 4 Chamber	LVIDd Avg; 2D and m-mode short axis (cm)	LVIDs Avg; 2D and m-mode short axis (cm)
NORMAL PARAMETER	50-100	0.7-1.7	0.7-1.6				
PATIENT	110	--	0.73	14.5	2.2	2.5	--

**Cardiac Presentation**

The echocardiogram in this patient demonstrated normal **left atrial** size based on 3 different LA measurement methods. Chamber volumes and echogenicity were normal. The cranial and caudal **mitral** valve leaflets presented vegetative thickening consistent with endocardiosis. Doppler indicated measurable insufficiency. The **left ventricle** presented normal thicknesses with linear contour and was not dilated nor restricted. The **myocardium** presented normal echogenicity without subjective evidence of significant fibrotic or ischemic disease. **Contractility** of the ventricular walls was adequate and in normal range for this patient evidenced by the fractional shortening measurement and subjective evaluation of the different regions of the myocardium. The **left ventricular outflow** tract demonstrated normal laminar flow and subjective structural integrity. The **right atrium** and auricle revealed normal size, structure and content. No evidence of masses was noted or chamber overload. **Tricuspid** valvular assessment demonstrated adequate linear morphology. The **right ventricle** was of normal size (1/3 diameter of LV), chordae structure, myocardial echogenicity and thickness. **Pulmonic** tract assessment revealed normal valve structure, laminar flow, and diameter (approx.1:1 pa/ao ratio). No visible **pericardial** or free pleura fluid was noted. No echographically detectable evidence of infiltrative disease was visible. The cranial **mediastinum and pericardial regions** were free of masses in the visible window. The hepatic veins were not dilated.

**ULTRASONOGRAPHIC FINDINGS**

- Stage B1 valvular disease with trivial tricuspid insufficiency.



**PATIENT**

Reggie Lysiak

**SPECIES**

Canine

**BREED**

Maltese Mix

**SEX**

Neutered Male

**AGE**

13

**WEIGHT**

14.5

**INTERPRETED BY**

Eric Lindquist, DMV,  
DABVP(CFM), Cert.  
IUUSS

**IMAGING PERFORMED BY**

Jenn

**HOSPITAL NAME**

Rockaway Animal  
Hospital

**REFERRING VET**

Dr. Brooks

**INVOICE**

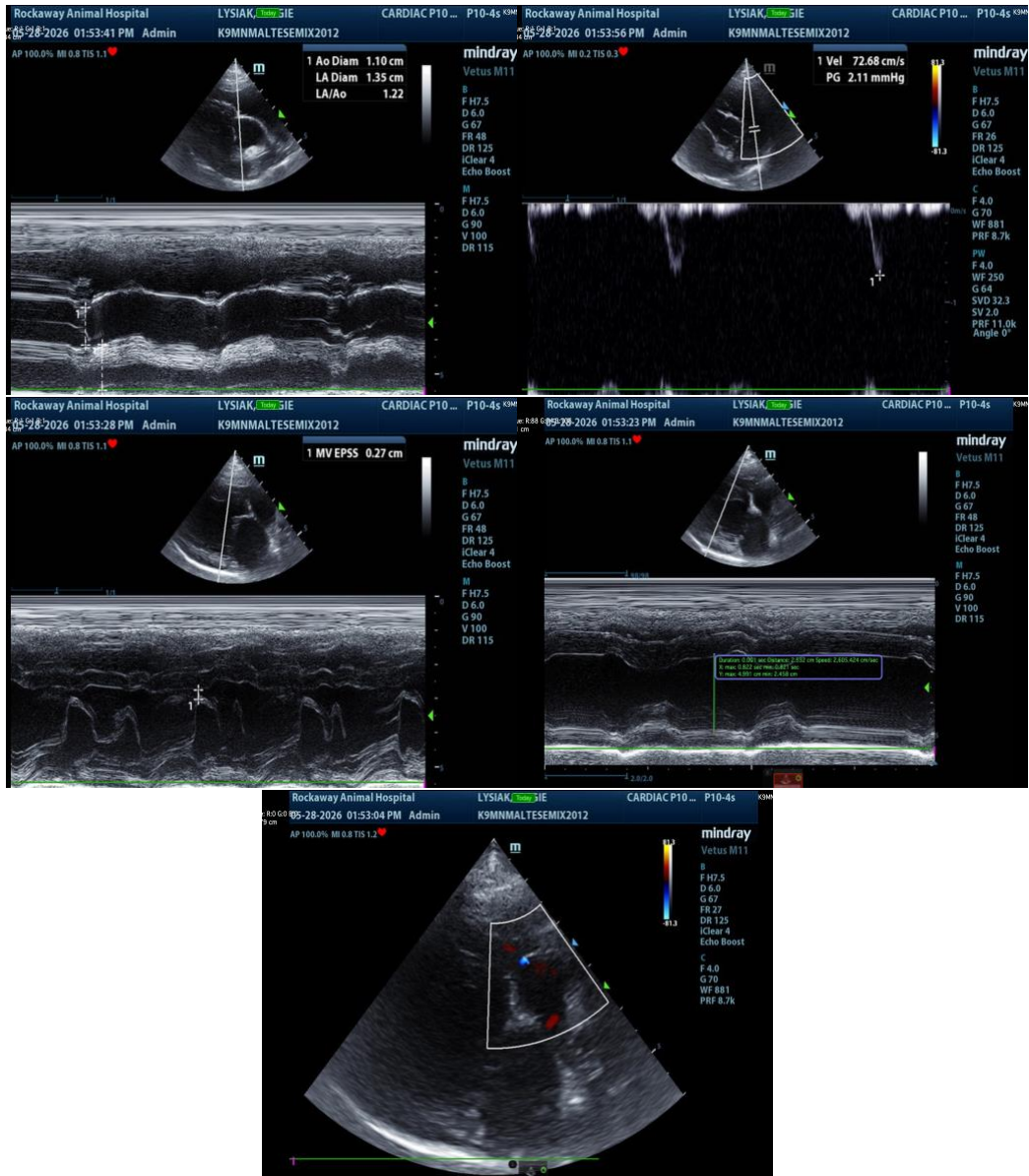
16547

**DATE**

05/28/26

**INTERPRETATION OF THE FINDINGS & FURTHER RECOMMENDATIONS**

No overt contraindication to anesthetic procedure.



The information and recommendations provided are based on the images presented by the referring veterinarian/sonographer. No evaluation can be communicated regarding pathology that was not visible in the image/video clips provided.

Thank you for this referral. If the clinical or image interpretation does not parallel your findings or if I can be of any further assistance, please contact me.



## PATIENT

Reggie Lysiak

## SPECIES

Canine

## BREED

Maltese Mix

## SEX

Neutered Male

## AGE

13

## WEIGHT

14.5

## INTERPRETED BY

Eric Lindquist, DMV,  
DABVP(CFM), Cert.  
IVUSS

## IMAGING PERFORMED BY

Jenn

## HOSPITAL NAME

Rockaway Animal  
Hospital

## REFERRING VET

Dr. Brooks

## INVOICE

16547

## DATE

05/28/26

Eric Lindquist, DMV, DABVP(CFM), Cert. IVUSS,

CEO, Owner, Founder -- SonoPath.com

[info@SonoPath.com](mailto:info@SonoPath.com)