



**PATIENT**

Muffin DeSantis

**SPECIES**

Canine

**BREED**

Havanese

**SEX**

Spayed Female

**AGE**

16

**WEIGHT**

8.9

**INTERPRETED BY**

Eric Lindquist, DMV,  
DABVP (Canine &  
Feline), Cert. IVUSS

**IMAGING PERFORMED BY**

Dr. Striano-Kaplan

**HOSPITAL NAME**

Ramsey VH

**REFERRING VET**

Dr. Striano-Kaplan

**INVOICE**

37253

**DATE**

5/28/26

**PRESENTING CLINICAL SIGNS**

History: Clinical signs (Coughing, Historical heart murmur/cardiac follow up), History (P is here for recheck x-rays, P is coughing and vomiting, decreased eating and O sometimes unable to give meds P is currently on: Pimobendan 5mg/ml 0.25ml PO BID Spironolactone 25mg/ml 0.25ml PO BID. Enalapril 2.5mg SID. Lasix 12.5mg - 1/2 BID

Abnormal PE/Chem/CBC/UA Results: 4/6 HM ULTRASONOGRAPHIC FINDINGS Volume overload in the left atrium and left ventricle. Ruptured chordae tendinea was noted in this patient. Stage B2+ valvular disease.

**ULTRASONOGRAPHIC EXAMINATION OF THE HEART**

CANINE CARDIAC PARAMETERS	MR VMAX (m/s)	TR VMAX (m/s)	LA/AO (M-Mode)	LA/AO (Heart Base; Swe)	FS (%)	EF (%)	EPSS (cm)
NORMAL PARAMETER	4.5-5.5	<2.7	1.3	Up to 1.6	28-40	40-100	<0.6
PATIENT	>5.0	--	1.7	--	42	76	0.1
CANINE CARDIAC PARAMETERS	HR (BPM)	AV VMAX (m/s)	PV MAX (m/s)	BODY WEIGHT	LAD LA MAX 4 Chamber	LVIDd Avg; 2D and m-mode short axis (cm)	LVIDs Avg; 2D and m-mode short axis (cm)
NORMAL PARAMETER	50-100	0.7-1.7	0.7-1.6				
PATIENT	130	1.20	--	8.9	2.9	2.08	--

**Cardiac Presentation**

The cardiac presentation in this patient demonstrated significant improvement in the left atrial and left ventricular volumes. Contractility has also improved. Mitral and tricuspid insufficiency were present. Prolapse of the anterior mitral valve leaflet was present and persistent. No pericardial or pleural effusion were noted.

**ULTRASONOGRAPHIC FINDINGS**

- Stabilized stage B2+ valvular disease on current protocol

**INTERPRETATION OF THE FINDINGS & FURTHER RECOMMENDATIONS**

Recommend maintaining pimobendan, spironolactone, enalapril, and if necessary, Lasix may be able to be reduced. The cause of the coughing and vomiting is not cardiogenic at this time, as left atrial



**PATIENT**

Muffin DeSantis

**SPECIES**

Canine

**BREED**

Havanese

**SEX**

Spayed Female

**AGE**

16

**WEIGHT**

8.9

**INTERPRETED BY**

Eric Lindquist, DMV,  
DABVP (Canine &  
Feline), Cert. IVUSS

**IMAGING  
PERFORMED BY**

Dr. Striano-Kaplan

**HOSPITAL NAME**

Ramsey VH

**REFERRING VET**

Dr. Striano-Kaplan

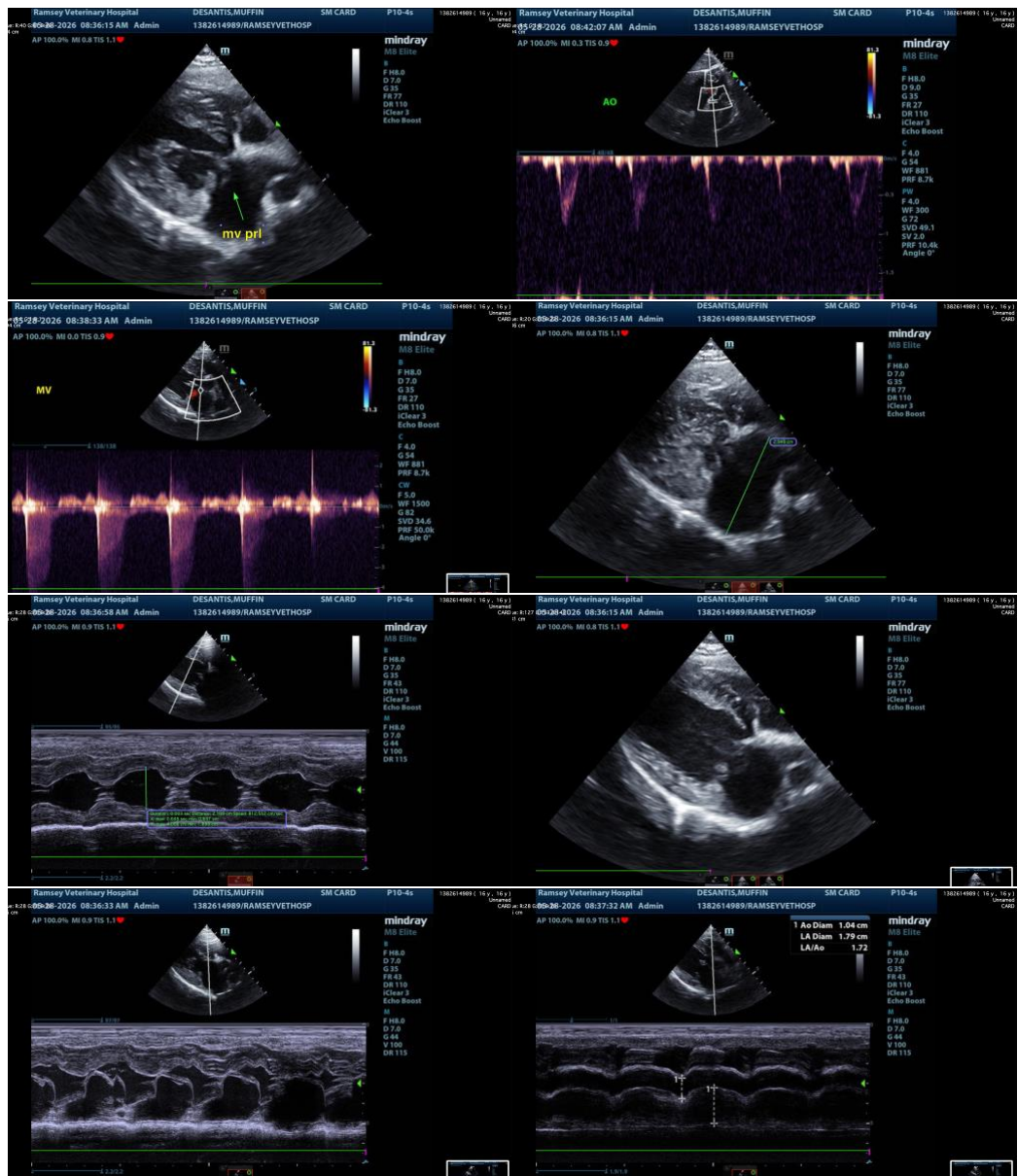
**INVOICE**

37253

**DATE**

5/28/26

volume is largely normalized, unless mainstem bronchus impingement is still present upon radiographic findings. Otherwise, concurrent bronchial disease is likely an issue. Regarding the vomiting and anorexia, abdominal sonogram is recommended to assess for concurrent disease, however, the heart appears significantly stabilized and ideally responsive to the medication protocol prescribed after the prior echocardiogram. CBC, chem, and U/A are warranted to assess if any abnormalities are present that may be influencing the vomiting and lethargy. Blood pressure measurements are also indicated.





## PATIENT

Muffin DeSantis

## SPECIES

Canine

## BREED

Havanese

## SEX

Spayed Female

## AGE

16

## WEIGHT

8.9

## INTERPRETED BY

Eric Lindquist, DMV,  
DABVP (Canine &  
Feline), Cert. IVUSS

## IMAGING PERFORMED BY

Dr. Striano-Kaplan

## HOSPITAL NAME

Ramsey VH

## REFERRING VET

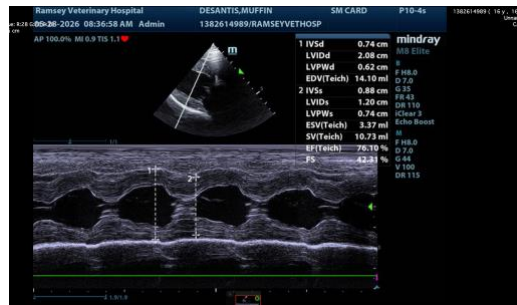
Dr. Striano-Kaplan

## INVOICE

37253

## DATE

5/28/26



The information and recommendations provided are based on the images presented by the referring veterinarian/sonographer. No evaluation can be communicated regarding pathology that was not visible in the image/video clips provided.

Thank you for this referral. If the clinical or image interpretation does not parallel your findings or if I can be of any further assistance please contact me.

**Eric Lindquist**, DMV, DABVP(CFM), Cert. IVUSS,  
CEO, Owner, Founder -- SonoPath.com  
[info@SonoPath.com](mailto:info@SonoPath.com)