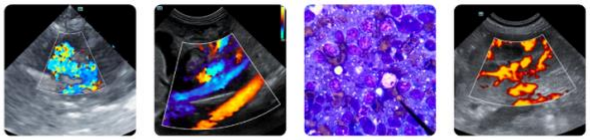

PATIENT
Lucy Beavers

SPECIES
Feline

BREED
DSH

SEX
Spayed Female

AGE
4.5 Years

WEIGHT
10.43 Pounds

INTERPRETED BY
Eric Lindquist, DMV, DABVP (Canine & Feline), Cert. IVUSS

IMAGING PERFORMED BY
Jack Reese

HOSPITAL NAME
Willow Run VC

REFERRING VET
Phoebe Miller, DVM

INVOICE

DATE

PRESENTING CLINICAL SIGNS

History: New patient presenting for exam in October 2025. Grade II/VI systolic heart murmur noted at that time - P asymptomatic at home, rest of exam unremarkable. Recheck exam on 5/1/26 revealed persistent murmur (Grade II/VI systolic) with no noted symptoms at home. Echocardiogram recommended as next step.

Abnormal PE/Chem/CBC/UA Results: Dental tartar, gingivitis No other physical abnormalities No recent labwork.

ULTRASONOGRAPHIC EXAMINATION OF THE HEART

FELINE CARDIAC PARAMETERS	**BODY WEIGHT** (kg)	**HR** (BPM)	**IVSd** (cm)	**LVIDd** (cm)	**LVWd** (cm)	**FS** (%)	**EF** (%)
NORMAL PARAMETER	------	150-240	0.3-0.6	1.0-2.1	0.25-0.6	35-67	80-100
PATIENT	--	NM	0.35	0.8	0.4	45	90
FELINE CARDIAC PARAMETERS	**LA/AO** (M-mode)	**LA/AO HEART BASE** (Sisson)	**LAD** LA MAX 4 Chamber		**LVOT VEL.** (m/s)	**RVOT VEL.** (m/s)	**IVRT** (m/)
NORMAL PARAMETER	<1.5	1.6	0.7-1.7		<1.6	<1.3	40-60
PATIENT	1.3	1.3			1.00	.80	NM
Adapted from June Boon, Veterinary Echocardiography,1998 Sisson D et al. JVIM 1991; 5: 232, Jacobs et al. Am J Vet Res 1985; 46:1705							

***Aortic velocity is likely underestimated.*

Cardiac Presentation

The echocardiogram in this patient demonstrated normal **left atrial** size based on 3 separate LA measurements. Trivial mitral insufficiency was noted in this patient, not clinically significant. The **left ventricle** presented normal thicknesses with linear contour and was not dilated nor restricted. The **myocardium** presented normal echogenicity without subjective evidence of significant fibrotic or ischemic disease. **Contractility** of the ventricular walls was adequate and in normal range for this patient evidenced by the fractional shortening measurement and subjective evaluation of the different regions and angles of the myocardium. The **left ventricular outflow** tract demonstrated normal laminar flow and subjective structural integrity. The **right atrium** and auricle revealed normal size, structure and content. No evidence of masses was noted or chamber overload. **Tricuspid** valvular assessment demonstrated adequate linear morphology and kinetics. The **right ventricle** was of normal size (1/3 diameter of LV), chordae structure, myocardial echogenicity and thickness. **Pulmonic** tract assessment revealed normal valve structure, laminar flow, and diameter (approx.1:1 pa/ao ratio).

PATIENT

Lucy Beavers

SPECIES

Feline

BREED

DSH

SEX

Spayed Female

AGE

4.5 Years

WEIGHT

10.43 Pounds

INTERPRETED BY

Eric Lindquist, DMV, DABVP (Canine & Feline), Cert. IVUSS

IMAGING PERFORMED BY

Jack Reese

HOSPITAL NAME

Willow Run VC

REFERRING VET

Phoebe Miller, DVM

INVOICE

DATE

No visible **pericardial** or free pleura fluid was noted or extra cardiac pathology in the visible planes. The cranial **mediastinum and pericardial regions** were free of masses in the visible window.

ULTRASONOGRAPHIC FINDINGS

- Normal echocardiogram with trivial mitral insufficiency- not clinically significant

INTERPRETATION OF THE FINDINGS & FURTHER RECOMMENDATIONS

No evidence of clinical disease. Recheck echo in one year.

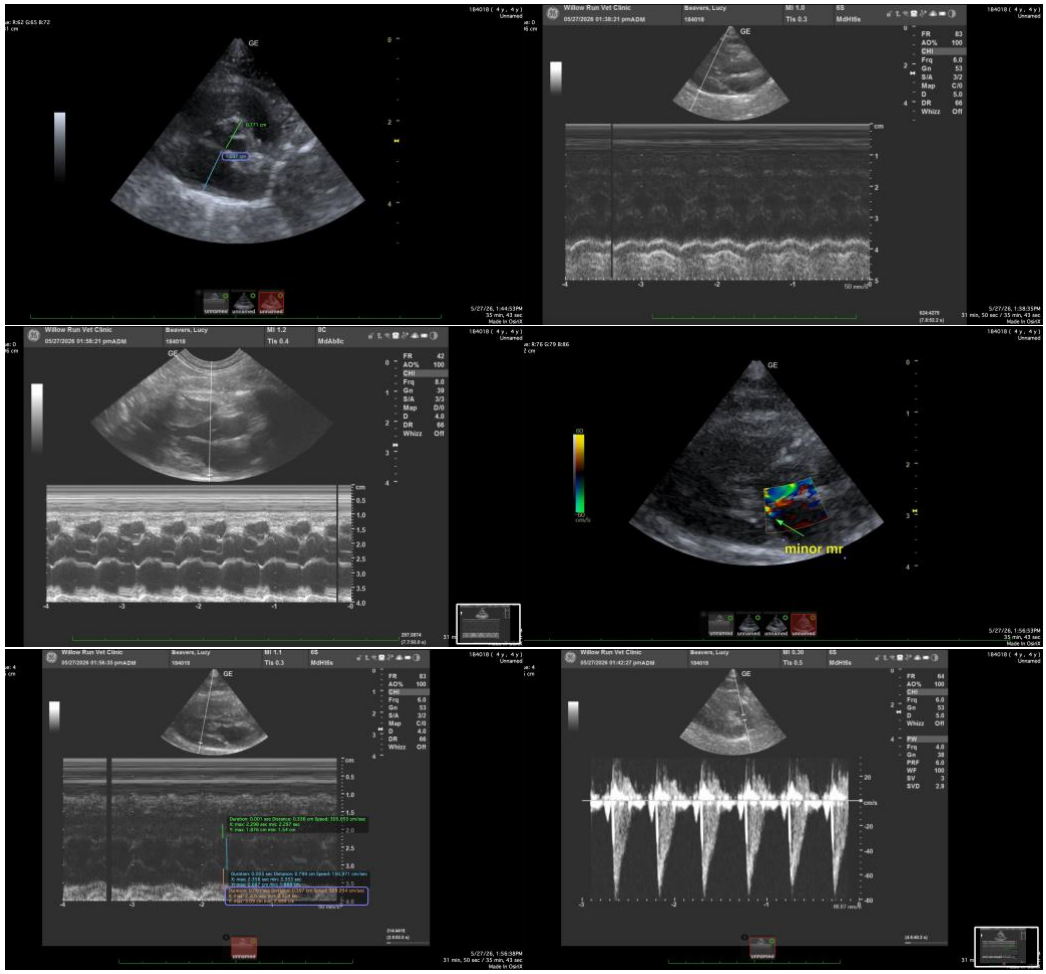

PATIENT

Lucy Beavers

SPECIES

Feline

BREED

DSH

SEX

Spayed Female

AGE

4.5 Years

WEIGHT

10.43 Pounds

INTERPRETED BY

Eric Lindquist, DMV, DABVP (Canine & Feline), Cert. IVUSS

IMAGING PERFORMED BY

Jack Reese

HOSPITAL NAME

Willow Run VC

REFERRING VET

Phoebe Miller, DVM

INVOICE

DATE

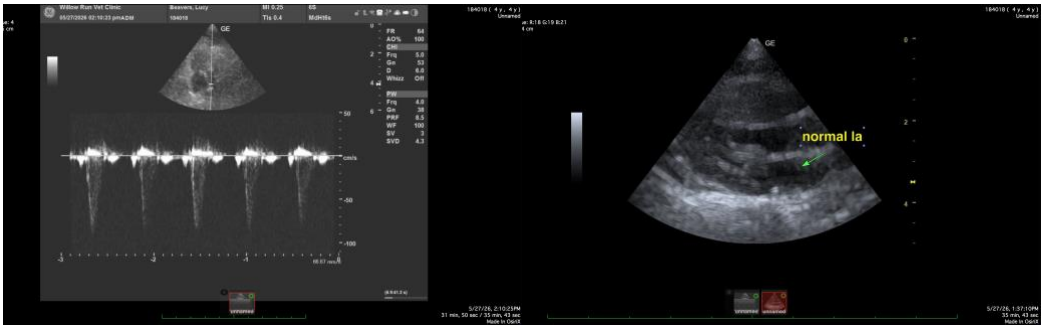

The information and recommendations provided are based on the images presented by the referring veterinarian/sonographer. No evaluation can be communicated regarding pathology that was not visible in the image/video clips provided.

Thank you for this referral. If the clinical or image interpretation does not parallel your findings or if I can be of any further assistance please contact me.

Eric Lindquist, DMV, DABVP(CFM), Cert. IVUSS,
CEO, Owner, Founder -- SonoPath.com
info@SonoPath.com