



PATIENT

Jasper Craig

SPECIES

Canine

BREED

Bernse Mountain Dog

SEX

Neutered Male

AGE

5 Years

WEIGHT

101 lbs

INTERPRETED BY

Eric Lindquist, DMV,
DABVP (CFM), Cert.
IVUSS

IMAGING PERFORMED BY

Shari Reffi, CVT

HOSPITAL NAME

Easton Animal Hospital

REFERRING VET

Dr. Craig

INVOICE

75524

DATE

5/28/26

PRESENTING CLINICAL SIGNS

Progressively increasing ALP level. Outwardly healthy (congenital orthopedic issues since a pup). Current Medications: Dasuquin, Turkey Tail Mushrooms (Dexdomitor/Torb sedation) BCS 4/9.

Abnormal PE/Chem/CBC/UA Results: Most recent ALP-1544; mild increased lipase-268

ULTRASONOGRAPHIC EXAMINATION OF THE ABDOMEN

Urinary System

The **urinary bladder**, trigone, and pelvic urethra presented normal thicknesses and normal tone. The ureters were not visible which is normal. No uroliths or sediment were visualized and anechoic urine was present. No evidence of inflammatory or neoplastic changes were noted. Ureteral papillae were normal.

The prostate was uniform at 1.04 cm.

The **kidneys** revealed normal size and structure, corticomedullary definition and ratio for this age. The cortices presented largely uniform texture with normal echogenic relationship to liver and spleen. Medullary structure differed distinctly from the cortex and no evidence of pelvic dilation was present. The capsules were acceptably uniform without significant irregularities. Right kidney measured 6.6 cm. Left kidney measured 6.6 cm.

Adrenal Glands

Both **adrenal glands** were visualized and recognized as having normal shape, size, position and echogenicity for this breed. The phrenic vasculature, glandular echogenicity and detail were unremarkable. Capsule, cortex, and medullary definition were normal for this age patient. Right measured 3.5 cm x 0.77 cm at the cranial pole and 0.67 cm at the caudal pole. Left measured 2.87 cm x 0.49 cm at the cranial pole and 0.56 cm at the caudal pole.

Spleen

The **spleen** was folded upon itself cranially and was slightly heterogeneous. No evidence of thrombosis.

Liver

The **liver** images submitted revealed subjectively normal liver size, contour, and structure. Parenchymal echogenicity was naturally coarse and hypoechoic to the spleen. Vascular and biliary tracts were of normal volume with no evidence of congestion. The gallbladder presented acceptably thin walls with primarily anechoic content. The cystic and common bile ducts were normal. No pathological hepatic lymphadenopathy was evident. No overt structural evidence of inflammatory, infiltrative or regenerative pathology was evident.

Gastrointestinal

Examination of the **gastrointestinal tract** revealed a stomach and intestine free of stasis, of normal wall thickness, acceptable curvilinear mural detail, and peristaltic activity. Small and large intestine demonstrated normal luminal chyme and stool consistency respectively. No obstructive or overt infiltrative disease was noted. No associated abnormal lymphatic activity was noted.



PATIENT

Jasper Craig

SPECIES

Canine

BREED

Bernse Mountain Dog

SEX

Neutered Male

AGE

5 Years

WEIGHT

101 lbs

INTERPRETED BY

Eric Lindquist, DMV,
 DABVP (CFM), Cert.
 IVUSS

IMAGING PERFORMED BY

Shari Reffi, CVT

HOSPITAL NAME

Easton Animal Hospital

REFERRING VET

Dr. Craig

INVOICE

75524

DATE

5/28/26

Pancreas

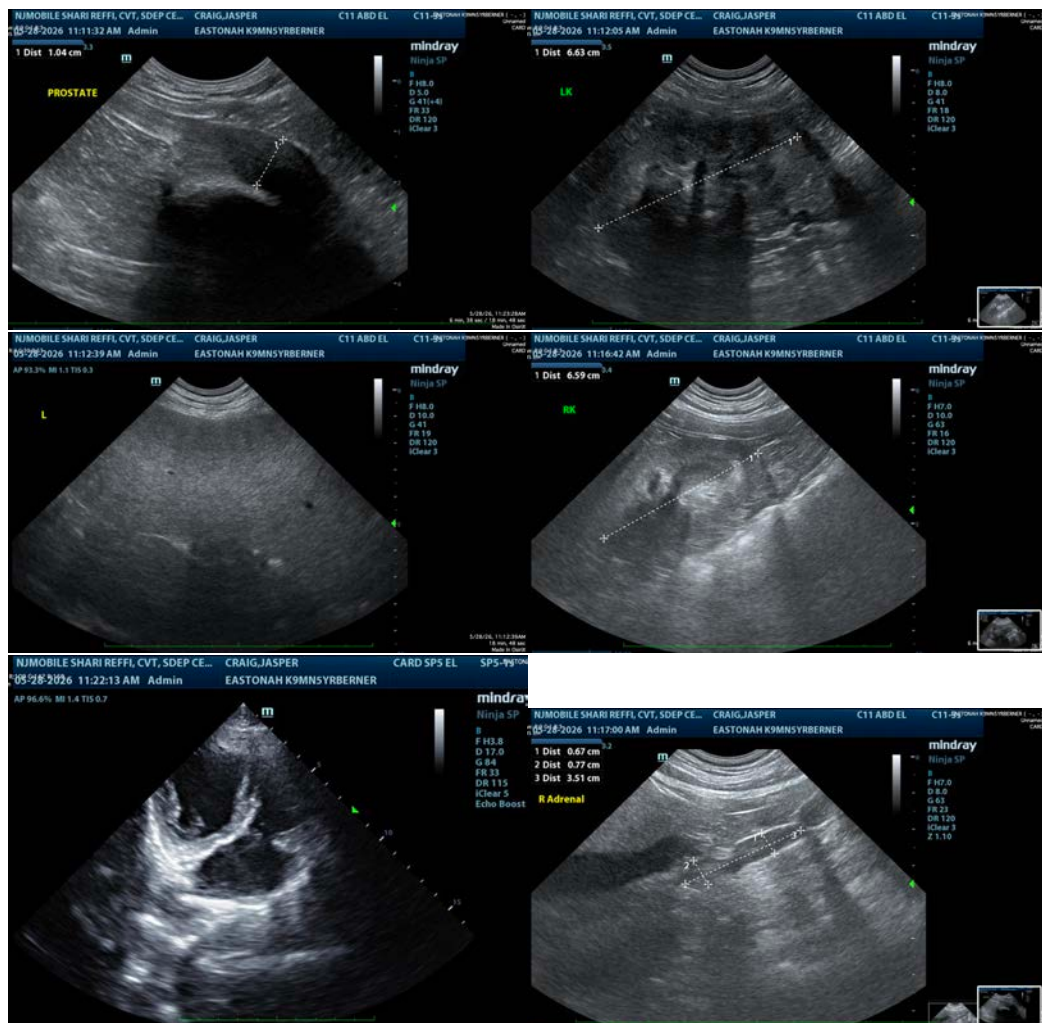The base and limbs of the **pancreas** were observed to be largely isoechoic to surrounding omental fat. Pancreatic duct and capsular contour were acceptably normal and parenchyma respected normal curvilinear patterns. No overt evidence of active inflammatory or neoplastic disease was noted.

ULTRASONOGRAPHIC FINDINGS

- Folded, slightly heterogeneous spleen, unremarkable abdomen otherwise.

INTERPRETATION OF THE FINDINGS & FURTHER RECOMMENDATIONS

Benign abdomen. Idiopathic ALP elevation. No evidence of visceral pathology.





PATIENT

Jasper Craig

SPECIES

Canine

BREED

Bernse Mountain Dog

SEX

Neutered Male

AGE

5 Years

WEIGHT

101 lbs

INTERPRETED BY

Eric Lindquist, DMV,
 DABVP (CFM), Cert.
 IVUSS

IMAGING PERFORMED BY

Shari Reffi, CVT

HOSPITAL NAME

Easton Animal Hospital

REFERRING VET

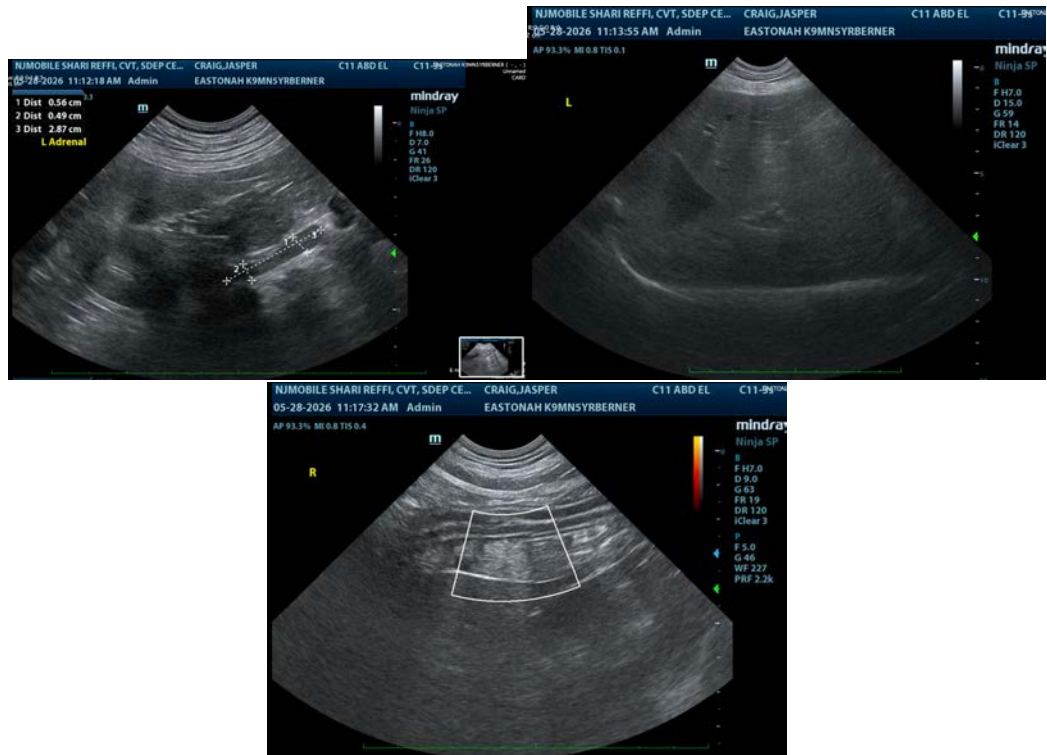
Dr. Craig

INVOICE

75524

DATE

5/28/26



The information and recommendations provided are based on the images presented by the referring veterinarian/sonographer. No evaluation can be communicated regarding pathology that was not visible in the image/video clips provided.

Thank you for this referral. If the clinical or image interpretation does not parallel your findings or if I can be of any further assistance please contact me.

Eric Lindquist, DMV, DABVP(CFM), Cert. IVUSS,
 CEO, Owner, Founder -- SonoPath.com
info@SonoPath.com