



PATIENT

Hab Scherzer

SPECIES

Canine

BREED

Aussie Doodle

SEX

Neutered Male

AGE

13 Years 1 Month

WEIGHT

69 lbs

INTERPRETED BY

Eric Lindquist, DMV,
DABVP(CFM), Cert.
IVUSS

IMAGING PERFORMED BY

Vincent Ravancho,
CVT

HOSPITAL NAME

Marsh Hospital for
Animals

REFERRING VET

Dr. Andrew Armani

INVOICE

16555

DATE

05/28/26

PRESENTING CLINICAL SIGNS

Recent radiographs note rounded region of the spleen. Current medications - Galliprant, Librela, Cytoint.

ULTRASONOGRAPHIC EXAMINATION OF THE HEART & ABDOMEN

CANINE CARDIAC PARAMETERS	MR VMAX (m/s)	TR VMAX (m/s)	LA/AO (M-Mode)	LA/AO (Heart Base; Swe)	FS (%)	EF (%)	EPSS (cm)
NORMAL PARAMETER	4.5-5.5	<2.7	1.3	Up to 1.6	28-40	40-100	<0.6
PATIENT	5.93	--	0.9	1.3	31	58	NM
CANINE CARDIAC PARAMETERS	HR (BPM)	AV VMAX (m/s)	PV MAX (m/s)	BODY WEIGHT (lbs)	LAD LA MAX 4 Chamber	LVIDd Avg; 2D and m-mode short axis (cm)	LVIDs Avg; 2D and m-mode short axis (cm)
NORMAL PARAMETER	50-100	0.7-1.7	0.7-1.6				
PATIENT	80-130	1.1	1.0	69	--	4.2	--

Cardiac Presentation

The echocardiogram in this patient demonstrated normal **left atrial** size based on 3 different LA measurement methods. Chamber volumes and echogenicity were normal. The cranial and caudal **mitral** valve leaflets presented vegetative thickening consistent with endocardiosis. Doppler indicated moderate centralized insufficiency. The **left ventricle** presented normal thicknesses with linear contour and was not dilated nor restricted. The **myocardium** presented normal echogenicity without subjective evidence of significant fibrotic or ischemic disease. **Contractility** of the ventricular walls was adequate and in normal range for this patient evidenced by the fractional shortening measurement and subjective evaluation of the different regions of the myocardium. The **left ventricular outflow** tract demonstrated normal laminar flow and subjective structural integrity. The **right atrium** and auricle revealed normal size, structure and content. No evidence of masses was noted or chamber overload. **Tricuspid** valvular assessment demonstrated adequate linear morphology. The **right ventricle** was of normal size (1/3 diameter of LV), chordae structure, myocardial echogenicity and thickness. **Pulmonic** tract assessment revealed normal valve structure, laminar flow, and diameter (approx.1:1 pa/ao ratio). No visible **pericardial** or free pleura fluid was noted. No echographically detectable evidence of infiltrative disease was visible. The cranial **mediastinum and pericardial regions** were free of masses in the visible window.

Urinary System

The **urinary bladder**, trigone, and pelvic urethra to a depth of 2.0 cm presented normal thicknesses and normal tone. The ureters were not visible which is normal. No uroliths or sediment were visualized,



PATIENT

Hab Scherzer

SPECIES

Canine

BREED

Aussie Doodle

SEX

Neutered Male

AGE

13 Years 1 Month

WEIGHT

69 lbs

INTERPRETED BY

Eric Lindquist, DMV,
DABVP(CFM), Cert.
IVUSS

IMAGING PERFORMED BY

Vincent Ravancho,
CVT

HOSPITAL NAME

Marsh Hospital for
Animals

REFERRING VET

Dr. Andrew Armani

INVOICE

16555

DATE

05/28/26

and anechoic urine was present. No evidence of inflammatory or neoplastic changes were noted. Ureteral papillae were normal.

The **kidneys** revealed normal size and structure, corticomedullary definition and ratio for this age. The cortices presented largely uniform texture with normal echogenic relationship to liver and spleen. Medullary structure differed distinctly from the cortex and no evidence of pelvic dilation was present. The capsules were acceptably uniform without significant irregularities. The left kidney measured 6.5 cm in length. The right kidney measured 6.5 cm in length. The left kidney revealed an anechoic cyst in the caudal pole measuring 3.5 cm x 2.7 cm.

Adrenal Glands

Both **adrenal glands** were visualized and recognized as having normal shape, size, position and echogenicity for this breed. The phrenic vasculature, glandular echogenicity and detail were unremarkable. Capsule, cortex, and medullary definition were normal for this age patient. The left adrenal gland measured 1.7 cm x 0.65 cm width at the cranial pole and 0.6 cm width at the caudal pole. The right adrenal gland measured 2.56 cm x 1.05 cm width.

Spleen

The **spleen** presented folded upon itself caudally with slight uniform swelling measuring 4.0 cm prior to the fold (likely a positional variant). Subtle micronodular changes were present elsewhere in the spleen. No overt masses were visualized.

Liver

The **liver** images from right and left intercostal as well as subcostal views revealed subjectively normal liver size, contour, and structure. Some mild age-related parenchymal remodeling was noted but likely not clinically significant at this time. Vascular and biliary tracts were of normal volume and no evidence of congestion was noted. The gallbladder presented some dependent debris with essentially normal contour. The cystic and common bile ducts were normal. No overt evidence of active inflammatory, infiltrative or regenerative pathology was noted but should be paired with current or past LE elevations regarding any clinical significance to this presentation. The hepatic lymph nodes were unremarkable.

Gastrointestinal

Examination of the **gastrointestinal tract** revealed a stomach and intestine free of stasis, of normal wall thickness, acceptable curvilinear mural detail, and peristaltic activity. Small and large intestine demonstrated normal luminal chyme and stool consistency respectively. No obstructive or overt infiltrative disease was noted. No associated abnormal lymphatic activity was noted.

Pancreas

The base and limbs of the **pancreas** were observed to be largely isoechoic to surrounding omental fat. Pancreatic duct and capsular contour were acceptably normal and parenchyma respected normal curvilinear patterns. No overt evidence of active inflammatory or neoplastic disease was noted.

ULTRASONOGRAPHIC FINDINGS

- Stage B1 valvular disease.
- Mild splenic enlargement with slight irregular swelling and is likely a positional variant- splenic hyperplasia is likely, emerging round cell neoplasia is possible yet thought less likely.



PATIENT

Hab Scherzer

- Left renal cyst- subjectively benign.
- Age-related hepatic remodeling.

SPECIES

Canine

BREED

Aussie Doodle

SEX

Neutered Male

AGE

13 Years 1 Month

WEIGHT

69 lbs

INTERPRETED BY

Eric Lindquist, DMV,
 DABVP(CFM), Cert.
 IUUSS

IMAGING PERFORMED BY

Vincent Ravancho,
 CVT

HOSPITAL NAME

Marsh Hospital for
 Animals

REFERRING VET

Dr. Andrew Armani

INVOICE

16555

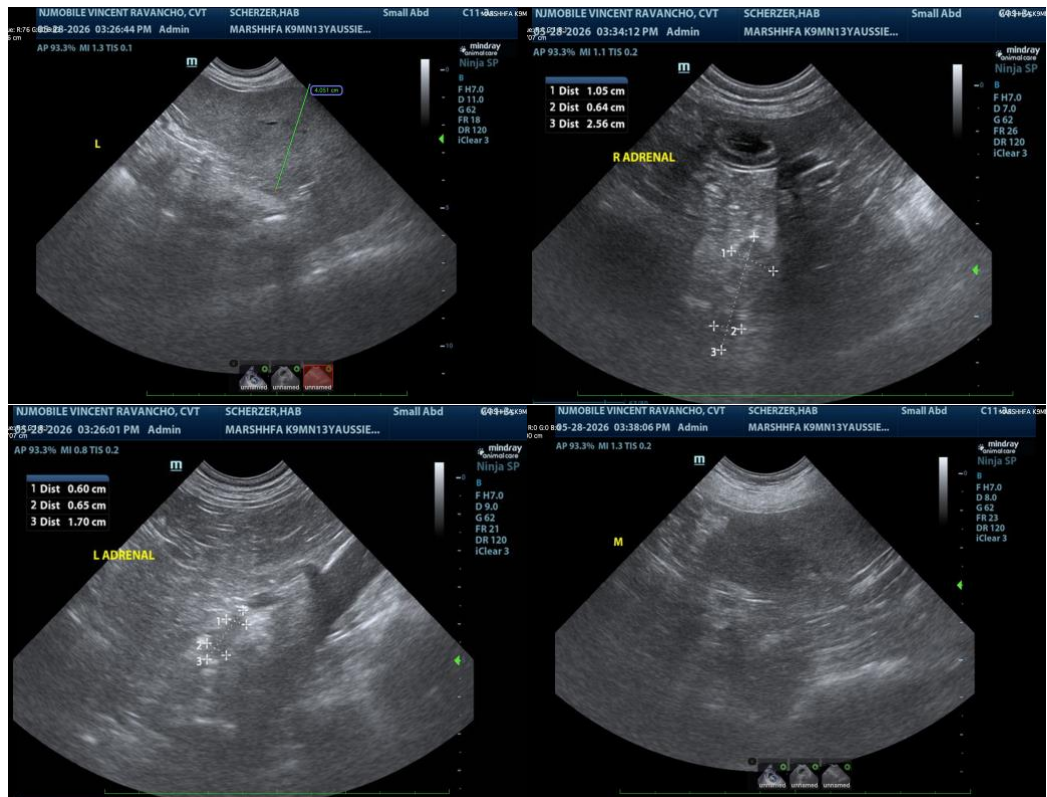
DATE

05/28/26

INTERPRETATION OF THE FINDINGS & FURTHER RECOMMENDATIONS

If any weight loss is an issue, 25-gauge screening FNA of the spleen is indicated.

The heart is stable without clinical disease. No overt contraindication for anesthesia of brief to moderate duration. I suggest Torbutrol premed, Propofol induction, Isoflor maintenance or similar protocol if anesthesia is desired. Blood pressure, EKG and chest radiographs are recommended if not already performed. Target white coat negative systolic pressure of < 160 mmHg. If higher than this ACE-inhibitor is suggested to reach this level. Recheck echocardiogram is recommended in 6-12 months, earlier if murmur grade increases or clinical signs initiate.





PATIENT

Hab Scherzer

SPECIES

Canine

BREED

Aussie Doodle

SEX

Neutered Male

AGE

13 Years 1 Month

WEIGHT

69 lbs

INTERPRETED BY

Eric Lindquist, DMV,
 DABVP(CFM), Cert.
 IVUSS

IMAGING PERFORMED BY

Vincent Ravancho,
 CVT

HOSPITAL NAME

Marsh Hospital for
 Animals

REFERRING VET

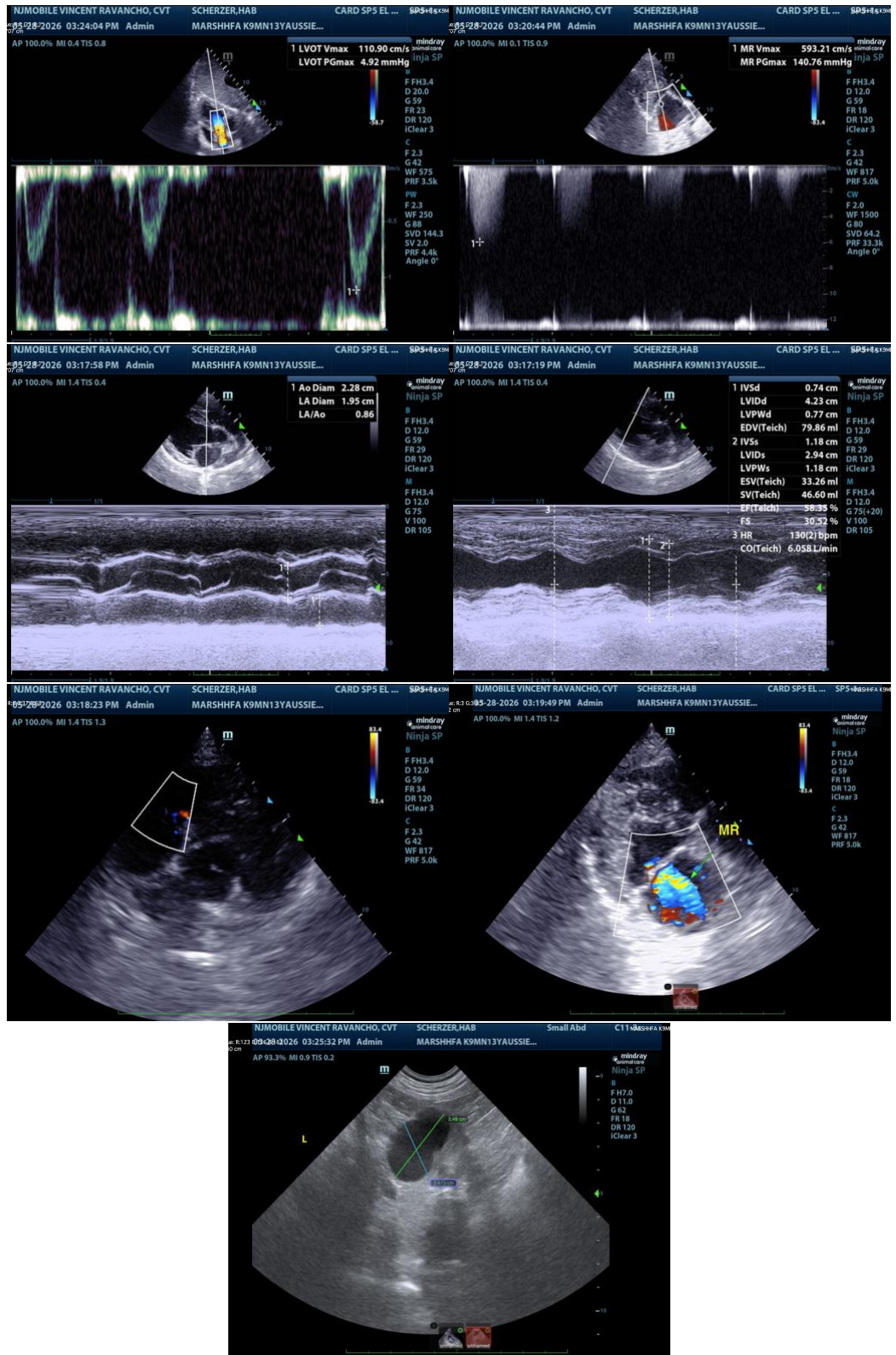
Dr. Andrew Armani

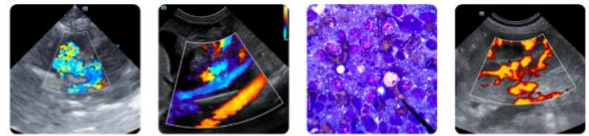
INVOICE

16555

DATE

05/28/26





PATIENT

Hab Scherzer

SPECIES

Canine

BREED

Aussie Doodle

SEX

Neutered Male

AGE

13 Years 1 Month

WEIGHT

69 lbs

INTERPRETED BY

Eric Lindquist, DMV,
DABVP(CFM), Cert.
IVUSS

**IMAGING
PERFORMED BY**

Vincent Ravancho,
CVT

HOSPITAL NAME

Marsh Hospital for
Animals

REFERRING VET

Dr. Andrew Armani

INVOICE

16555

DATE

05/28/26

The information and recommendations provided are based on the images presented by the referring veterinarian/sonographer. No evaluation can be communicated regarding pathology that was not visible in the image/video clips provided.

Thank you for this referral. If the clinical or image interpretation does not parallel your findings or if I can be of any further assistance, please contact me.

Eric Lindquist, DMV, DABVP(CFM), Cert. IVUSS,

CEO, Owner, Founder -- SonoPath.com

info@SonoPath.com