



## PATIENT

Bella Walsh

## SPECIES

Canine

## BREED

Chihuahua Mix

## SEX

Spayed Female

## AGE

12 Years

## WEIGHT

10.8 Pounds

## INTERPRETED BY

Eric Lindquist, DMV,  
DABVP (Canine &  
Feline), Cert. IVUSS

## IMAGING PERFORMED BY

Dr. Megan Bray

## HOSPITAL NAME

Taylorsville VC

## REFERRING VET

Dr. Megan Bray

## INVOICE

37276

## DATE

5/28/26

## PRESENTING CLINICAL SIGNS

History: Patient presented on 5/20/26 for a toenail injury. Upon exam a new GRADE 2/6 LEFT-SIDED SYSTOLIC HEART MURMUR was found. The owner reports that Bella has been experiencing episodes of coughing at night, which they had previously attributed to tracheal issues. She had a particularly severe coughing fit about 5 days ago. Owner kept log of resting respiratory rate which averaged at 24.

Abnormal PE/Chem/CBC/UA Results: Grade 2/6 HM, Lab work revealed a SIGNIFICANTLY ELEVATED CARDIAC BIOMARKER. proBNP: ELEVATED at 2,660.

## ULTRASONOGRAPHIC EXAMINATION OF THE HEART

CANINE CARDIAC PARAMETERS	MR VMAX (m/s)	TR VMAX (m/s)	LA/AO (M-Mode)	LA/AO (Heart Base; Swe)	FS (%)	EF (%)	EPSS (cm)
NORMAL PARAMETER	4.5-5.5	<2.7	1.3	Up to 1.6	28-40	40-100	<0.6
PATIENT	--	--	1.1	1.3	35	--	0.1
CANINE CARDIAC PARAMETERS	HR (BPM)	AV VMAX (m/s)	PV MAX (m/s)	BODY WEIGHT (lbs)	LAD LA MAX 4 Chamber	LVIDd Avg; 2D and m-mode short axis (cm)	LVIDs Avg; 2D and m-mode short axis (cm)
NORMAL PARAMETER	50-100	0.7-1.7	0.7-1.6				
PATIENT	60	1.90	.50	10.8	2.3	1.8	--

## Cardiac Presentation

The echocardiogram in this patient demonstrated normal **left atrial** size based on 3 different LA measurement methods. Chamber volumes and echogenicity were normal. The cranial and caudal **mitral** valve leaflets presented vegetative thickening consistent with endocardiosis. Doppler indicated minor and centralized insufficiency. The **left ventricle** presented thicknesses with linear contour and was not dilated nor restricted. The **myocardium** presented normal echogenicity without subjective evidence of significant fibrotic or ischemic disease. **Contractility** of the ventricular walls was adequate and in normal range for this patient evidenced by the fractional shortening measurement and subjective evaluation of the different regions of the myocardium. The **left ventricular outflow** tract demonstrated normal laminar flow and subjective structural integrity. The **right atrium** and auricle revealed normal size, structure and content. No evidence of masses was noted or chamber overload. **Tricuspid** valvular assessment demonstrated adequate linear morphology. The **right ventricle** was of normal size (1/3 diameter of LV), chordae structure, myocardial echogenicity and thickness. **Pulmonic** tract assessment revealed normal valve structure, laminar flow, and diameter (approx.1:1 pa/ao ratio).



## PATIENT

Bella Walsh

## SPECIES

Canine

## BREED

Chihuahua Mix

## SEX

Spayed Female

## AGE

12 Years

## WEIGHT

10.8 Pounds

## INTERPRETED BY

Eric Lindquist, DMV,  
DABVP (Canine &  
Feline), Cert. IVUSS

## IMAGING PERFORMED BY

Dr. Megan Bray

## HOSPITAL NAME

Taylorville VC

## REFERRING VET

Dr. Megan Bray

## INVOICE

37276

## DATE

5/28/26

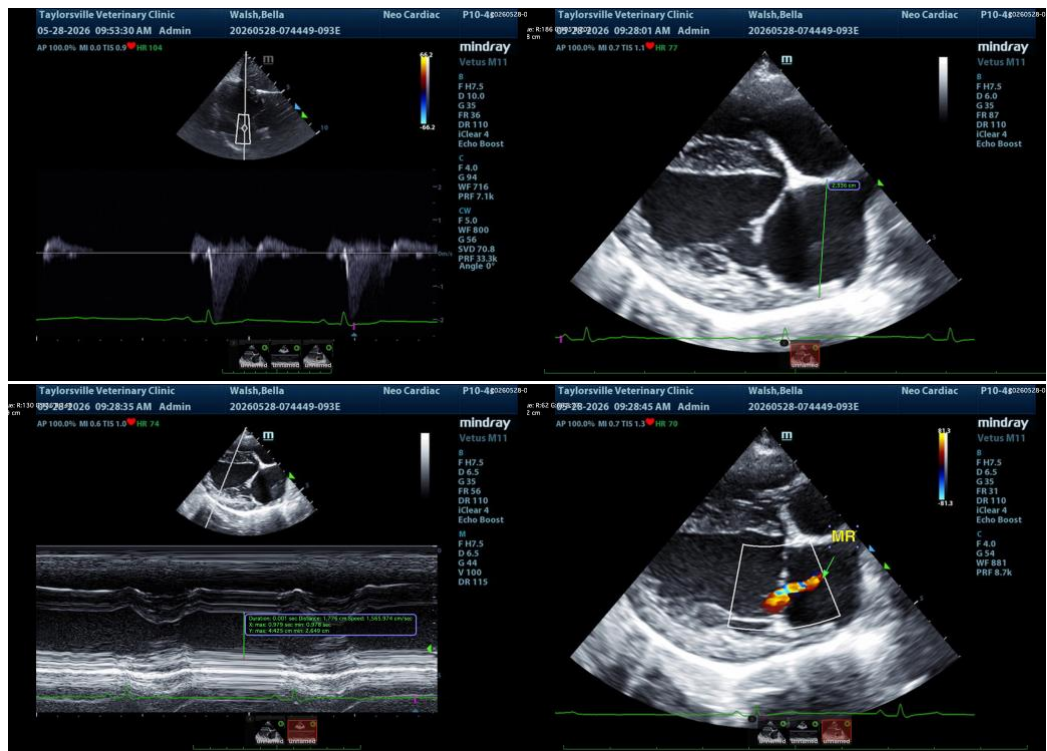
No visible **pericardial** or free pleura fluid was noted. No echographically detectable evidence of infiltrative disease was visible. The cranial **mediastinum and pericardial regions** were free of masses in the visible window.

## ULTRASONOGRAPHIC FINDINGS

- Stage B1 valvular disease
- The cough is noncardiogenic in this patient

## INTERPRETATION OF THE FINDINGS & FURTHER RECOMMENDATIONS

The heart is stable without clinical disease. No overt contraindication for anesthesia of brief to moderate duration. I suggest Torbutrol premed, Propofol induction, Isoflor maintenance or similar protocol if anesthesia is desired. Blood pressure recommended if not already performed and target white coat negative systolic pressure of < 160 mmHg. If higher than this ACE-inhibitor is suggested to reach this level. Recheck echocardiogram is recommended in 6 months, earlier if murmur grade increases or clinical signs initiate.





### PATIENT

Bella Walsh

### SPECIES

Canine

### BREED

Chihuahua Mix

### SEX

Spayed Female

### AGE

12 Years

### WEIGHT

10.8 Pounds

### INTERPRETED BY

Eric Lindquist, DMV,  
DABVP (Canine &  
Feline), Cert. IVUSS

### IMAGING PERFORMED BY

Dr. Megan Bray

### HOSPITAL NAME

Taylorville VC

### REFERRING VET

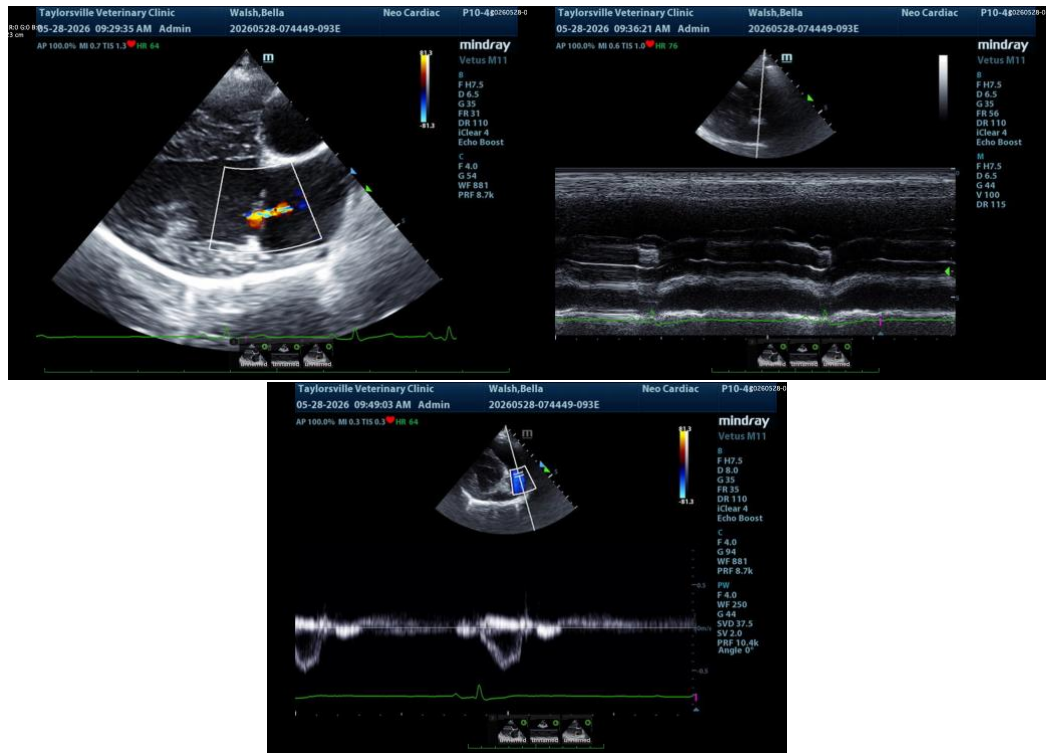
Dr. Megan Bray

### INVOICE

37276

### DATE

5/28/26



**The information and recommendations provided are based on the images presented by the referring veterinarian/sonographer. No evaluation can be communicated regarding pathology that was not visible in the image/video clips provided.**

Thank you for this referral. If the clinical or image interpretation does not parallel your findings or if I can be of any further assistance please contact me.

**Eric Lindquist**, DMV, DABVP(CFM), Cert. IVUSS,  
CEO, Owner, Founder -- SonoPath.com  
[info@SonoPath.com](mailto:info@SonoPath.com)