



PATIENT

Targaryen Goldenberg

SPECIES

Feline

BREED

DSH

SEX

Neutered Male

AGE

11

WEIGHT

10.4

INTERPRETED BY

Eric Lindquist, DMV,
DABVP(CFM), Cert.
IVUSS

IMAGING PERFORMED BY

Jenn

HOSPITAL NAME

Rockaway Animal
Hospital

REFERRING VET

Dr. Maniar

INVOICE

16528

DATE

05/27/26

PRESENTING CLINICAL SIGNS

Re check prev u/s 5/5 and 5/6 persistent pancreatic cyst. Owner reports eating well but persistent soft stool/ diarrhea

ULTRASONOGRAPHIC EXAMINATION OF THE ABDOMEN

Urinary System

The **urinary bladder**, trigone, and pelvic urethra presented normal thicknesses and normal tone. The ureters were not visible which is normal. No uroliths or sediment were visualized, and anechoic urine was present. No evidence of inflammatory or neoplastic changes were noted. Ureteral papillae were normal.

The **kidneys** revealed normal size and structure, corticomedullary definition and ratio for this age. The cortices presented largely uniform texture with normal echogenic relationship to liver and spleen. Medullary structure differed distinctly from the cortex and no evidence of pelvic dilation was present. The capsules were acceptably uniform without significant irregularities. The left kidney measured 4.4 cm in length. The right kidney measured 3.94 cm in length. Blood flow to the kidneys appeared to be mildly subnormal on power doppler assessment.

Adrenal Glands

Both **adrenal glands** were not visualized.

Spleen

The **spleen** presented a smooth homogeneous parenchyma hyperechoic to liver and renal cortical parenchyma. The capsule was smooth without noticeable expansion or deviation from within the spleen or adjacent pathology. The splenic vasculature demonstrated normal volume without signs of congestion or thrombosis. No sonographic evidence of acute or chronic inflammatory, neoplastic, or infarctual changes were noted.

Liver

The **liver** revealed coarse architecture and increased portal markings. The gallbladder and common bile duct were unremarkable. A moderate amount of remodeling was noted as well.

Gastrointestinal

Examination of the **gastrointestinal tract** revealed a stomach and intestine free of stasis, of normal wall thickness, acceptable curvilinear mural detail, and peristaltic activity. Small and large intestine demonstrated normal luminal chyme and stool consistency respectively. No obstructive or overt infiltrative disease was noted. No associated abnormal lymphatic activity was noted.

Pancreas

The **pancreatic** cyst is persistent with echogenic debris and a granulation bed. Echogenic debris or tissue thickening measured 1.1 cm. The cyst measured 2.5 cm.

ULTRASONOGRAPHIC FINDINGS

- Persistent pancreatic cyst/minor tissue thickening or granulomatous formation.



PATIENT

- Hepatic remodeling.

Targaryen Goldenberg

INTERPRETATION OF THE FINDINGS & FURTHER RECOMMENDATIONS

SPECIES

Ultrasound guided drainage is recommended with culture. Bile acid profile is warranted as well in this patient given the level of hepatic remodeling.

Feline

BREED

Internal medicine consult can be utilized through SonoPath.com. You can select the internal medicine drop down at <http://spa.sonopath.com/>.

DSH

One of the world's top internists & SonoPath associate Dr. Remo Lobetti BVSc, MMedVet, PhD, DECVIM can evaluate your case through SonoPath. <https://sonopath.com/resources/sonopath-services/internal-medicine-teleconsultation-services>

SEX

Neutered Male

AGE

11

WEIGHT

10.4

INTERPRETED BY

Eric Lindquist, DMV, DABVP(CFM), Cert. IVUSS

IMAGING PERFORMED BY

Jenn

HOSPITAL NAME

Rockaway Animal Hospital

REFERRING VET

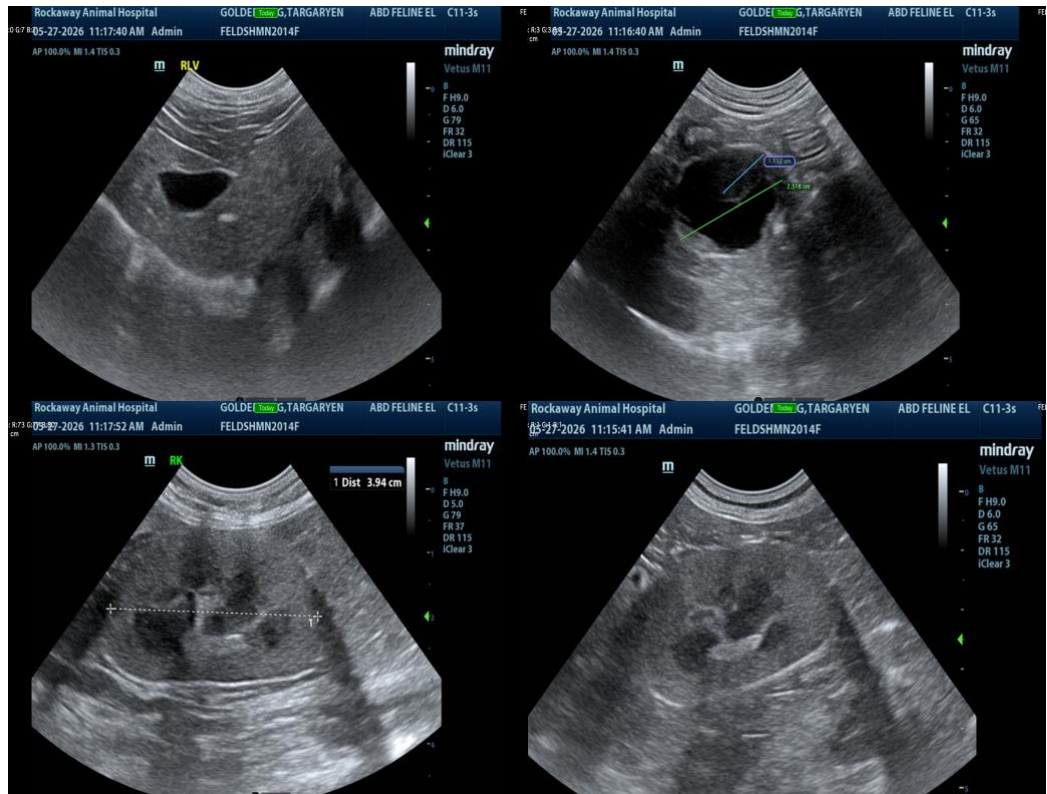
Dr. Maniar

INVOICE

16528

DATE

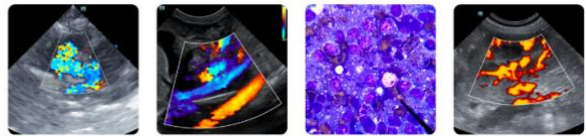
05/27/26



The information and recommendations provided are based on the images presented by the referring veterinarian/sonographer. No evaluation can be communicated regarding pathology that was not visible in the image/video clips provided.

Thank you for this referral. If the clinical or image interpretation does not parallel your findings or if I can be of any further assistance, please contact me.

Eric Lindquist, DMV, DABVP(CFM), Cert. IVUSS,
CEO, Owner, Founder -- SonoPath.com



PATIENT

info@SonoPath.com

Targaryen Goldenberg

SPECIES

Feline

BREED

DSH

SEX

Neutered Male

AGE

11

WEIGHT

10.4

INTERPRETED BY

Eric Lindquist, DMV,
DABVP(CFM), Cert.
IVUSS

IMAGING PERFORMED BY

Jenn

HOSPITAL NAME

Rockaway Animal
Hospital

REFERRING VET

Dr. Maniar

INVOICE

16528

DATE

05/27/26