



PATIENT

Poppy Russell

SPECIES

Feline

BREED

Domestic Shorthair

SEX

Spayed female

AGE

8 years

WEIGHT

8 lbs

INTERPRETED BY

Eric Lindquist, DMV
DABVP, Cert. IVUSS

IMAGING PERFORMED BY

Gudrun Gunther

HOSPITAL NAME

New Frontier Animal
Medical Center

REFERRING VET

Dr. Gunther

INVOICE

78050

DATE

5/27/26

PRESENTING CLINICAL SIGNS

History: Chronic weight loss/hyporexia.

Patient also has significant dental disease - we are trying to differentiate abdominal disease (such as IBD) from severe dental disease as cause for hyporexia and weight loss.

Abnormal PE/Chem/CBC/UA Results: CBC - WNL CHEM - elevated globulins (5.8 - normal. 2.8 - 5.1) mild elevation GGT spec fPL - WNL T4 - euthyroid UA - unremarkable FeLV/FIV negative

ULTRASONOGRAPHIC EXAMINATION OF THE ABDOMEN

Urinary System

The **urinary bladder**, trigone, and pelvic urethra presented normal thicknesses and normal tone. The ureters were not visible which is normal. No uroliths or sediment were visualized and anechoic urine was present. No evidence of inflammatory or neoplastic changes was noted. Ureteral papillae were normal.

The **kidneys** revealed largely normal size and structure, corticomedullary definition and ratio (cortex 1/3 of medulla) were essentially maintained with some age-related loss of curvilinear patterns regarding the capsule and C/M junction. The cortices presented largely uniform texture with some increased echogenicity expected for this age patient. Medullary structure differed distinctly from that of the cortex and no evidence of pelvic dilation was present. Mineralization was noted in the kidneys. The right kidney measured 3.5 cm. The left kidney measured 3.3 cm.

Adrenal Glands

Both **adrenal glands** were visualized and recognized as having normal shape, size, position and echogenicity for this breed. The phrenic vasculature, glandular echogenicity and detail were unremarkable. Capsule, cortex, and medullary definition were normal for this age patient. The left adrenal gland measured 0.3 cm.

Spleen

The **spleen** was mildly enlarged with uniform, but subtly micronodular parenchyma, and undulating capsular contour. This is consistent with reactive spleen owing to immune stimulus or early infiltrative disease such as mast cell disease or lymphoma. 25-gauge FNA would be ideal if weight loss is an issue to differentiate early round cell neoplasia versus splenitis or reactive spleen all of which can present in this manner. The spleen measured 1.05 cm.

Liver

The **liver** images submitted revealed subjectively normal liver size, contour, and structure. Parenchymal echogenicity was naturally coarse and hypoechoic to the spleen. Vascular and biliary tracts were of normal volume with no evidence of congestion. The gallbladder presented acceptably thin walls with primarily anechoic content. The cystic and common bile ducts were normal. No pathological hepatic



PATIENT

Poppy Russell

SPECIES

Feline

BREED

Domestic Shorthair

SEX

Spayed female

AGE

8 years

WEIGHT

8 lbs

INTERPRETED BY

Eric Lindquist, DMV
DABVP, Cert. IVUSS

IMAGING PERFORMED BY

Gudrun Gunther

HOSPITAL NAME

New Frontier Animal
Medical Center

REFERRING VET

Dr. Gunther

INVOICE

78050

DATE

5/27/26

lymphadenopathy was evident. No overt structural evidence of inflammatory, infiltrative or regenerative pathology was evident.

Gastrointestinal

The **gastrointestinal tract** revealed minor variable thickening and echogenic submucosal changes most consistent with low grade end result of chronic GI disease such as IBD and may be related to malassimilation of nutrients if any weight loss is present. Minor muscularis thickening was noted. No obvious neoplastic patterns were noted and luminal content as unremarkable.

Pancreas

The base and limbs of the **pancreas** were observed to be largely isoechoic to surrounding omental fat. Some parenchymal remodeling, however, with mild deviation from curvilinear normalcy was observed. Pancreatic duct and capsular irregularities were present consistent with age related changes. If pain upon imaging (+ Murphy sign) was present or if the patient is focally painful in subxiphoid palpation then low-grade smoldering chronic pancreatitis should be suspected.

ULTRASONOGRAPHIC FINDINGS

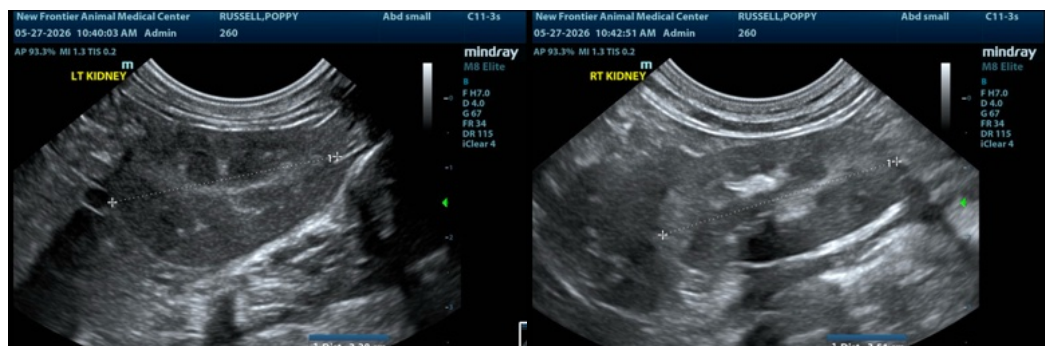
Unremarkable age related abdominal changes with slight intestinal thickening.

Mild splenic enlargement.

INTERPRETATION OF THE FINDINGS & FURTHER RECOMMENDATIONS

Given the elevated globulins and minor splenomegaly I recommend FNA of the spleen to ensure multiple myeloma is not an issue. Protein electrophoresis is indicated.

Maldigestion panel, three view chest radiographs and full CNS examination is recommended to examine for occult disease that could be responsible for the weight loss. Evaluation for competitive eating environments should also be considered.





PATIENT

Poppy Russell

SPECIES

Feline

BREED

Domestic Shorthair

SEX

Spayed female

AGE

8 years

WEIGHT

8 lbs

INTERPRETED BY

Eric Lindquist, DMV
DABVP, Cert. IVUSS

IMAGING PERFORMED BY

Gudrun Gunther

HOSPITAL NAME

New Frontier Animal
Medical Center

REFERRING VET

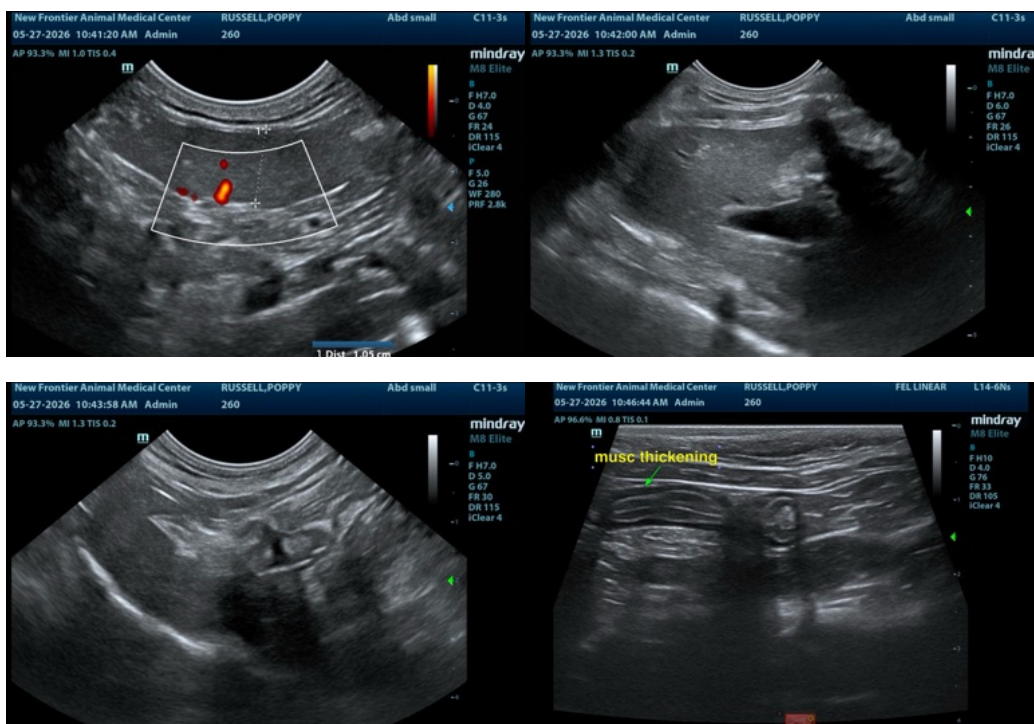
Dr. Gunther

INVOICE

78050

DATE

5/27/26



The information and recommendations provided are based on the images presented by the referring veterinarian/sonographer. No evaluation can be communicated regarding pathology that was not visible in the image/video clips provided.

Thank you for this referral. If the clinical or image interpretation does not parallel your findings or if I can be of any further assistance please contact me.

Eric Lindquist, DMV, DABVP (CFM), Cert. IVUSS, CEO of SonoPath.com

info@SonoPath.com