



**PATIENT**

Opie Palen

**SPECIES**

Canine

**BREED**

Border Collie

**SEX**

Neutered Male

**AGE**

11 Years

**WEIGHT**

46.9 Pounds

**INTERPRETED BY**

Eric Lindquist, DMV

DABVP, Cert. IVUSS

**IMAGING PERFORMED BY**

Dr. John Ammeraal

**HOSPITAL NAME**

Sova Animal Hospital

**REFERRING VET**

Dr. John Ammeraal

**INVOICE**

38089

**DATE**

5/27/22

**PRESENTING CLINICAL SIGNS**

First OV since 2019, past couple weeks Owner noted dribbling more urine as he walks after initial urination. Also noted to be drinking more as well.

Abnormal PE/Chem/CBC/UA Results: Fatty mass noted. BCS 5/9, few raised dermal masses. Seborrhea, Grade2 dental disease,

**LIMITED ULTRASONOGRAPHIC EXAMINATION**

The **urinary bladder** revealed sand accumulation, a grouping of which measured approximately 2.0 cm, non-obstructive. The pelvic urethra was imaged 3.0 cm beyond the cystourethral junction.

The **kidneys** revealed largely normal size and structure, corticomedullary definition and ratio (cortex 1/3 of medulla) were essentially maintained with some age-related loss of curvilinear patterns regarding the capsule and C/M junction. The cortices presented largely uniform texture with some increased echogenicity expected for his age patient. Medullary structure differed distinctly from that of the cortex and no evidence of pelvic dilation was present. Occasional cortical cyst and pinpoint calculi noted, non-obstructive. The left kidney measured 5.0 cm. The right kidney measured 5.0 cm.

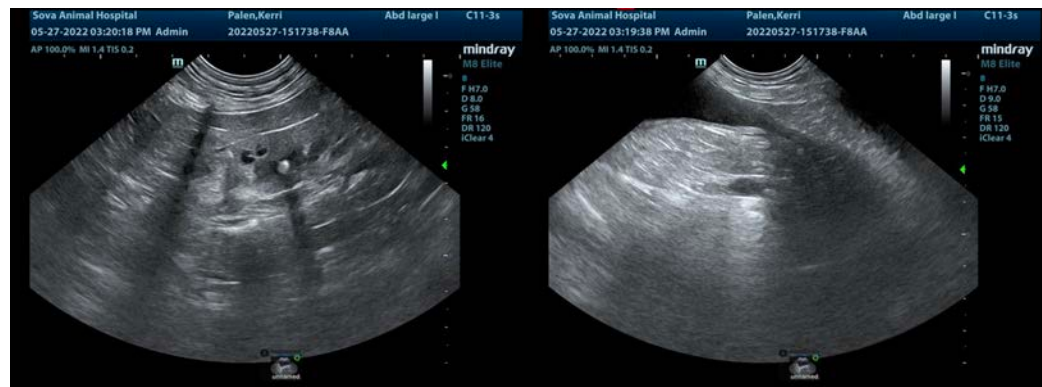
Rapid view of the liver revealed no evident pathology other than minor gallbladder debris.

**ULTRASONOGRAPHIC FINDINGS**

- Bladder sand
- Moderate degenerative renal changes with regenerative cysts and minor calculi

**INTERPRETATION OF THE FINDINGS & FURTHER RECOMMENDATIONS**

Cystotomy, sand analysis and culture recommended. Normo- and retrograde urethral flushing recommended.





**PATIENT**

Opie Palen

**SPECIES**

Canine

**BREED**

Border Collie

**SEX**

Neutered Male

**AGE**

11 Years

**WEIGHT**

46.9 Pounds

**INTERPRETED BY**

Eric Lindquist, DMV

DABVP, Cert. IVUSS

**IMAGING PERFORMED BY**

Dr. John Ammeraal

**HOSPITAL NAME**

Sova Animal Hospital

**REFERRING VET**

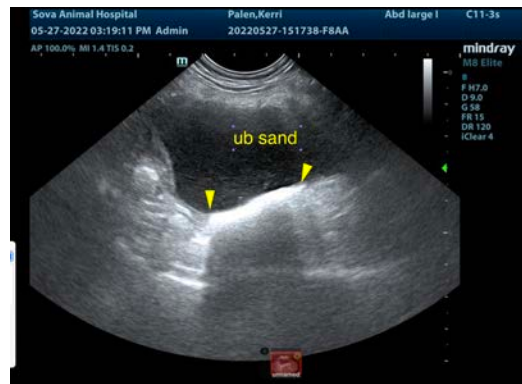Dr. John Ammeraal

**INVOICE**

38089

**DATE**

5/27/22



The information and recommendations provided are based on the images presented by the referring veterinarian/sonographer. No evaluation can be communicated regarding pathology that was not visible in the image/video clips provided.

Thank you for this referral. If the clinical or image interpretation does not parallel your findings or if I can be of any further assistance please contact me.

Eric Lindquist, DMV, DABVP, Cert. IVUSS, CEO of SonoPath.com

[info@SonoPath.com](mailto:info@SonoPath.com)