



PATIENT PRESENTING CLINICAL SIGNS

Mr. Joe Watts presented for cloudy malodorous urine, not eating as well as usual, chronic URI flare up recently, having some difficulty eating dry food, hx of ht murmur (4/6) and HCM being managed on pimobendan
 Abnormal PE/Chem/CBC/UA Results: blephrospasm OD mild cervical ventroflexion 4/6 ht murmur-loudest at the base CBC- Lymph 0.59, WBC 20.24, NEU 19.48, CHEM 17- Ca2+ 8.4, CL 100, GLU 137, K+ 2.1, Tbil 0.8, Na 143, BUN 148.7, CRE 1.7, PCV 30%/TS 6.2g/dl UA- USG 1.014,

SPECIES

Feline

BREED

Manx

SEX

Neutered male

AGE

20 years

WEIGHT

6 lbs

ULTRASONOGRAPHIC EXAMINATION OF THE ABDOMEN

Urinary System

The **urinary bladder**, trigone, and pelvic urethra presented normal thicknesses and normal tone. The ureters were not visible which is normal. No uroliths or sediment were visualized and anechoic urine was present. No evidence of inflammatory or neoplastic changes was noted. Ureteral papillae were normal.

The **kidneys** presented a relatively uniform cortical hyperechogenicity when compared to the renal medulla, spleen and liver. No overt masses were noted. Corticomedullary definition was nebulous and the ratio favored the cortex slightly. The ureters were not visible and assumed to be normal. These changes are most consistent with chronic interstitial nephritis yet infiltrative disease could not be entirely ruled out without biopsy though neoplasia is not suspected. The kidneys measured 3.6 cm.

Adrenal Glands

Both **adrenal glands** were visualized and recognized as having normal shape, size, position and echogenicity for this breed. The phrenic vasculature, glandular echogenicity and detail were unremarkable. Capsule, cortex, and medullary definition were normal for this age patient.

Spleen

The **spleen** presented a smooth homogeneous parenchyma hyperechoic to liver and renal cortical parenchyma. The capsule was smooth without noticeable expansion or deviation from within the spleen or adjacent pathology. The splenic vasculature demonstrated normal volume without signs of congestion or thrombosis. No sonographic evidence of acute or chronic inflammatory, neoplastic, or infarctual changes was noted.

Liver

The **liver** images submitted revealed subjectively normal liver size, contour, and structure. Parenchymal echogenicity was naturally coarse and hypoechoic to the spleen. Vascular and biliary tracts were of normal volume with no evidence of congestion. The gallbladder presented acceptably thin walls with primarily anechoic content. The cystic and common bile ducts were normal. No pathological hepatic lymphadenopathy was evident. No overt structural evidence of inflammatory, infiltrative or regenerative pathology was evident.

Gastrointestinal

INTERPRETED BY

Eric Lindquist, DMV
DABVP, Cert. IVUSS

IMAGING PERFORMED BY

Tessa Maggiulli

HOSPITAL NAME

Willamette VH

REFERRING VET

Dr. Maggiulli

INVOICE

30743

DATE

5/27/22



PATIENT

Mr. Joe Watts

Examination of the **gastrointestinal tract** revealed a stomach and intestine free of stasis, of normal wall thickness, acceptable curvilinear mural detail, and peristaltic activity. Small and large intestine demonstrated normal luminal chyme and stool consistency respectively. No obstructive or overt infiltrative disease was noted. No associated abnormal lymphatic activity was noted.

SPECIES

Feline

Pancreas

BREED

Manx

The base and limbs of the **pancreas** were observed to be largely isoechoic to surrounding omental fat. Pancreatic duct and capsular contour were acceptably normal and parenchyma respected normal curvilinear patterns. No overt evidence of active inflammatory or neoplastic disease was noted.

SEX

Neutered male

ULTRASONOGRAPHIC FINDINGS

Acute on chronic subjectively end stage interstitial nephrosis renal pattern.

AGE

20 years

INTERPRETATION OF THE FINDINGS & FURTHER RECOMMENDATIONS

Prognosis based on response to therapy and 72 hour IV fluid support, urine culture and blood pressure measurements are recommended.

WEIGHT

6 lbs

INTERPRETED BY

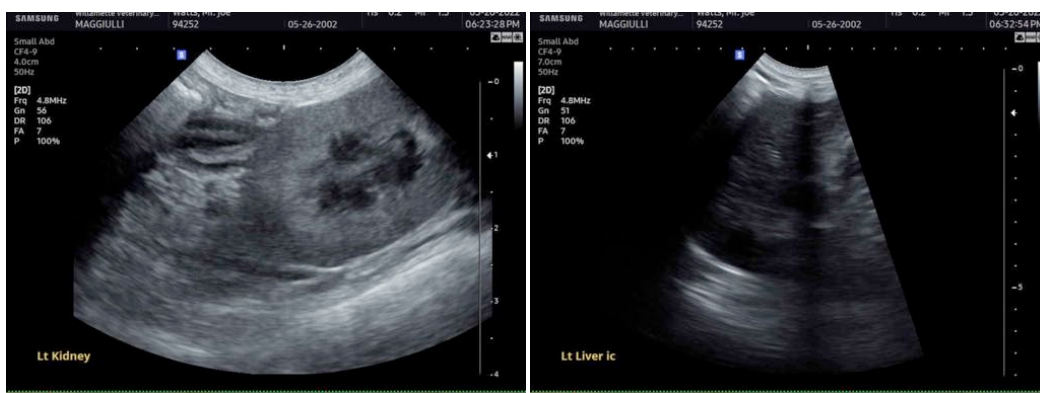Eric Lindquist, DMV
DABVP, Cert. IVUSS

IMAGING PERFORMED BY

Tessa Maggiulli

HOSPITAL NAME

Willamette VH



REFERRING VET

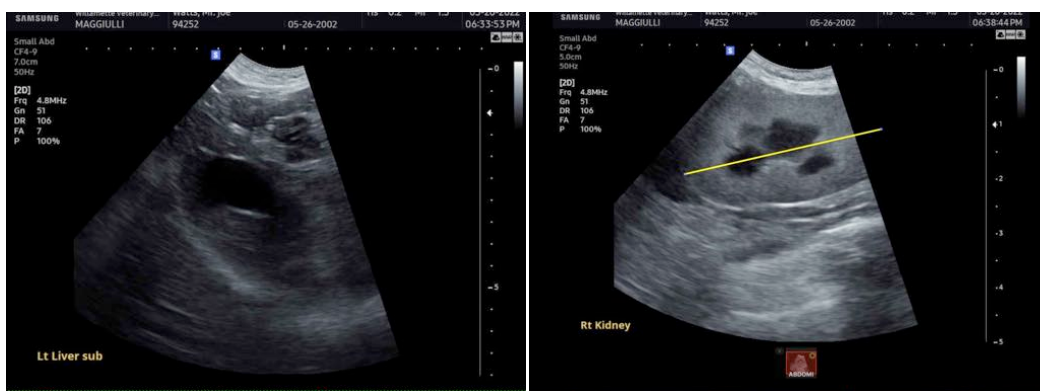
Dr. Maggiulli

INVOICE

30743

DATE

5/27/22





PATIENT

Mr. Joe Watts

The information and recommendations provided are based on the images presented by the referring veterinarian/sonographer. No evaluation can be communicated regarding pathology that was not visible in the image/video clips provided.

SPECIES

Feline

Thank you for this referral. If the clinical or image interpretation does not parallel your findings or if I can be of any further assistance please contact me.

BREED

Manx

Eric Lindquist, DMV, DABVP, Cert. IVUSS, CEO of SonoPath.com
info@SonoPath.com

SEX

Neutered male

AGE

20 years

WEIGHT

6 lbs

INTERPRETED BY

Eric Lindquist, DMV
DABVP, Cert. IVUSS

IMAGING PERFORMED BY

Tessa Maggiulli

HOSPITAL NAME

Willamette VH

REFERRING VET

Dr. Maggiulli

INVOICE

30743

DATE

5/27/22