IMAGING PERFORMED BY

IntraPet.com

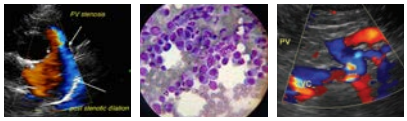

SonoPath
Clinical Sonography & Telecytology
EDUCATIONAL TELECONSULTATION SERVICES™
1-800-838-4268 info@sonopath.com SonoPath.com

DATE

5/27/22

PATIENT

Lilly Bear Holcomb

SPECIES

Canine

BREED

Mixed

SEX

Spayed Female

AGE

11/29/09

WEIGHT

11 Pounds

INTERPRETED BY

Eric Lindquist, DMV
DABVP, Cert. IVUSS

IMAGING PERFORMED BY

Stephanie Pearce
RDCS, RVT

HOSPITAL NAME

Animal Care Center

REFERRING VET

Dr. Anderson

INVOICE

38083

PRESENTING CLINICAL SIGNS

Elevated liver enzymes on labs.

Current Medications: None listed.
Lab Results: Elevated ALT up to 689, ALP 219, Lipase 325. Urinalysis unremarkable.
Date of Previous IntraPet Ultrasound: No previous.
Sedation: Not required to complete full diagnostic ultrasound.
Stat Report: Not requested.

ULTRASONOGRAPHIC EXAMINATION OF THE ABDOMEN

Urinary System

The **urinary bladder**, trigone, and pelvic urethra presented normal thicknesses and normal tone. The ureters were not visible which is normal. A mild amount of bladder sand was noted up to 1.0 cm, non-obstructive. No evidence of inflammatory or neoplastic changes were noted. Ureteral papillae were normal.

The **kidneys** presented moderate degenerative changes with pelvic and corticomedullary calculi. The right kidney measured 3.85 cm. The left kidney measured 3.67 cm. Blood flow to the kidneys appeared to be adequate to slightly subnormal on color flow assessment.

Adrenal Glands

Both **adrenal glands** were visualized and recognized as having normal shape, size, position and echogenicity for this breed. The phrenic vasculature, glandular echogenicity and detail were unremarkable. Capsule, cortex, and medullary definition were normal for this age patient. The right adrenal gland measured 1.48 cm x 0.40 cm at the caudal pole and 0.48 cm at the cranial pole. The left adrenal gland measured 1.89 cm x 0.45 cm at the caudal pole and 0.45 cm at the cranial pole.

Spleen

The **spleen** presented a smooth homogeneous parenchyma hyperechoic to liver and renal cortical parenchyma. The capsule was smooth without noticeable expansion or deviation from within the spleen or adjacent pathology. The splenic vasculature demonstrated normal volume without signs of congestion or thrombosis. No sonographic evidence of acute or chronic inflammatory, neoplastic, or infarctual changes were noted.

Liver

The **liver** revealed coarse architecture. Mild increased portal markings noted. The gallbladder and common bile duct were unremarkable. A minor amount of gallbladder debris, physiological.

Gastrointestinal

Examination of the **gastrointestinal tract** revealed a stomach and intestine free of stasis, of normal wall thickness, acceptable curvilinear mural detail, and peristaltic activity. Small and large intestine demonstrated normal luminal chyme and stool consistency respectively. No obstructive or overt infiltrative disease was noted. No associated abnormal lymphatic activity was noted.

Pancreas

The base and limbs of the **pancreas** were observed to be largely isoechoic to surrounding omental fat. Some parenchymal remodeling, however, with mild deviation from curvilinear normalcy was observed. Pancreatic duct and capsular irregularities were present consistent with age related changes. If pain upon imaging (+ Murphy sign) was present or if the patient is focally painful in subxyphoid palpation then low-grade smoldering chronic pancreatitis should be suspected.

ULTRASONOGRAPHIC FINDINGS

- Moderate degenerative renal changes
- Benign hepatopathy with remodeling
- Age related pancreatic changes
- Bladder sand – should pass without difficulty.

INTERPRETATION OF THE FINDINGS & FURTHER RECOMMENDATIONS

The patient is likely passing sand periodically from the kidneys to the bladder. Medical management should prove effective. Largely geriatric abdomen. FNA of the liver could be considered for further definition of inflammatory cell type. Diet management recommended regarding the bladder sand, and coverage for UTI with urine culture, given the mild upper limits of normal urinary white count.

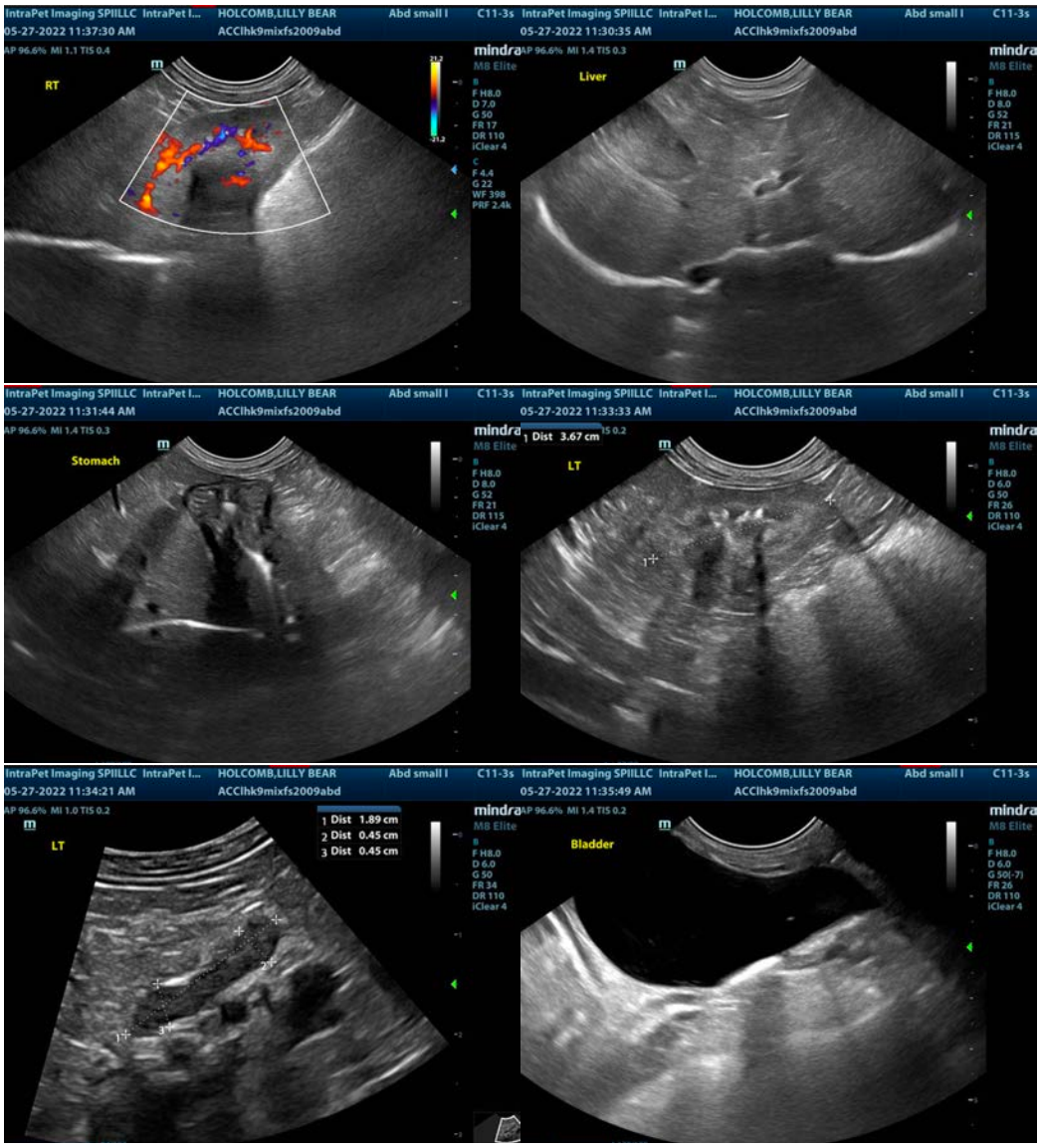

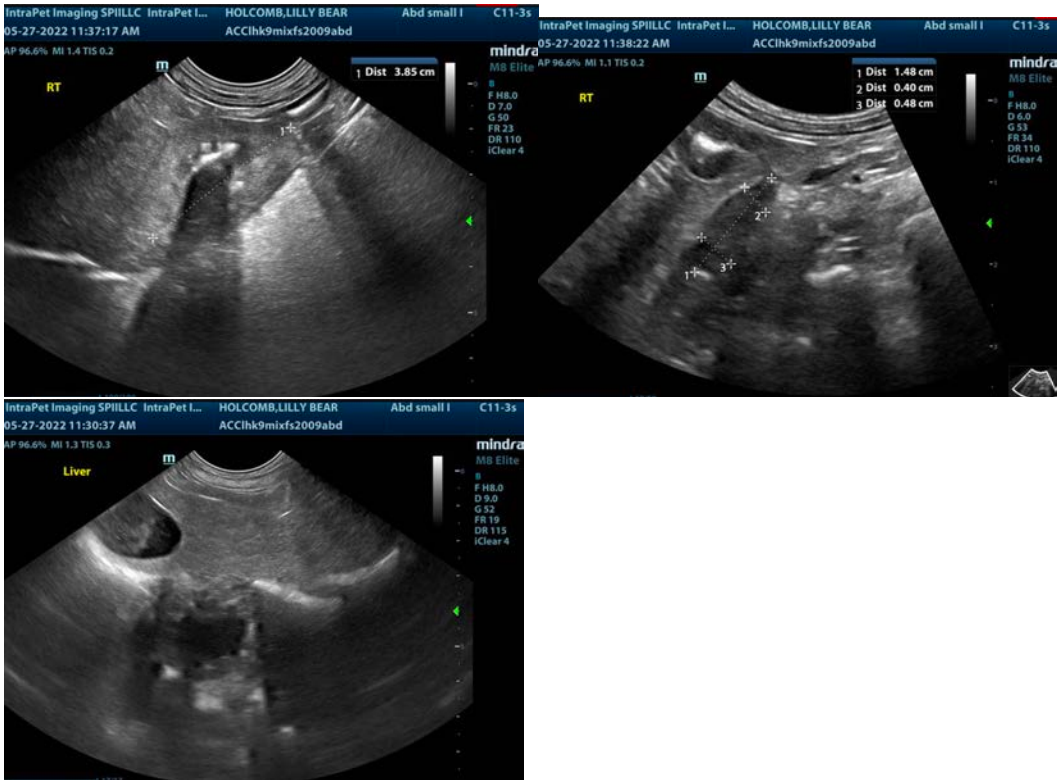

The information and recommendations provided are based on the images presented by the referring veterinarian/sonographer. No evaluation can be communicated regarding pathology that was not visible in the image/video clips provided.

Thank you for this referral. If the clinical or image interpretation does not parallel your findings or if I can be of any further assistance please contact me.

Eric Lindquist, DMV, DABVP, Cert. IVUSS, CEO of SonoPath.com
info@SonoPath.com